

**State budgetary educational institution of higher
professional education**

**"North Ossetian State Medical Academy" of the Ministry of
health of the Russian Federation**

Department of surgical diseases No. 2

Kalitsova M. V., Totikov Z.V.

ABDOMINAL HERNIAS

Textbook for students of 4 courses medical faculty of faculty surgery

Vladikavkaz

2020

Kalitsova M. V., Totikov Z.V.

Abdominal hernias: teaching guide for students, studying at “General Medicine” faculty. - North Ossetian state medical academy. - Vladikavkaz, 2020. - 29 sh.

This teaching guide covers main issues about etiology, pathogenesis, clinical features, laboratory and instrumental diagnostics and complications of Abdominal hernias.

Teaching guide “Abdominal hernias” is made for “Faculty surgery” discipline in accordance with requirements of FSES HE, and is intended for students from medical universities and faculties, studying for specialty 31.05.01 General medicine.

Reviews:

Khestanov A.K. - Professor of medical science, professor of Surgical department №3 department FSES HE NOSMA of Russian Ministry of health.

Beslekoiev U.S. - Associate professor, doctor of medical science, head of General surgery department FSES HE NOSMA of Russian Ministry of health.

Approved and recommended for printing by Central Coordinational educational and methodical board FSES HE NOSMA of Russian Ministry of health (6 july protocol № 6)

© North Ossetian State Medical Academy, 2020

© Kalitsova M.V., Totikov Z.V., 2020

CONTENTS

ANATOMY OF THE INGUINAL REGION	4
CLASSIFICATION OF HERNIA.....	8
AETIOLOGY OF HERNIA.....	9
INDIRECT HERNIA.....	10
DIRECT HERNIA.....	11
INDIRECT HERNIA.....	12
COMPLICATIONS OF HERNIA	20
RECURRENT HERNIA	24

- Hernia is a common condition affecting patients, especially inguinal hernia in males and incisional hernia in females. Even though several types of surgery have been described for hernias, mesh hernioplasty remains the gold standard treatment. Majority of the hernias require surgical treatment leaving apart small asymptomatic direct hernias in elderly. Today, laparoscopic hernia is becoming gold standard. Obstructed hernia is an emergency and late cases carry significant mortality. As far as students are concerned, hernia is the most common case in the examination. Hence, detailed clinical examination of hernia, complications, and various types of hernias and their treatment have been described in this chapter.

- Hernia means to bud or protrude or rupture (Latin).

Definition

Abnormal protrusion of a viscus or a part of it through a weak point in the body (opening) is known as a hernia. Inguinal hernia occurs either through the deep inguinal ring (indirect hernia) or through the posterior wall of the inguinal canal (direct hernia).

ANATOMY OF THE INGUINAL REGION (Fig. 1)

Inguinal ligament (Poupart's ligament) (1)

- It is the ligamentous portion of the external oblique aponeurosis which folds inwards and extends from anterior superior iliac spine to the pubic tubercle.
- The midpoint between these two structures is called midpoint of the inguinal ligament.

Lacunar ligament (Gimbernat's ligament)

- Some fibres of inguinal ligament pass posteriorly to attach to superior pubic ramus lateral to the tubercle and forms lacunar ligament.
- The midpoint between the anterior superior iliac spine and pubic symphysis is called midinguinal point.

Inguinal canal (2)

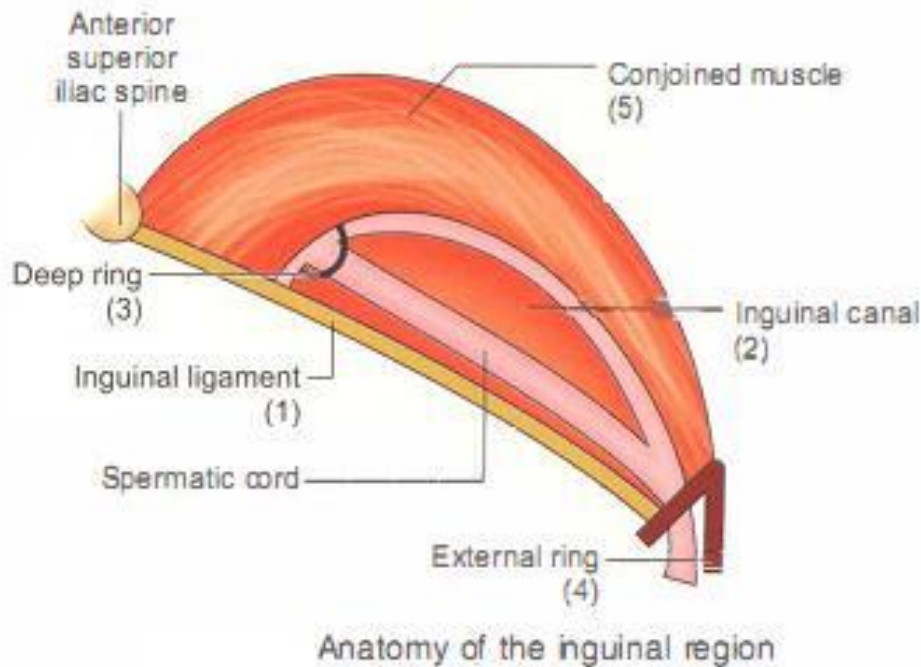
- It is 4 cm in length extending from the deep inguinal ring to the superficial inguinal ring.

Deep ring (internal ring) (3)

It is a 'U' shaped defect in the fascia transversalis which forms the posterior wall of the inguinal canal. It lies 1.25 cm above the midpoint of the inguinal ligament.

External ring (superficial ring) (4)

Superficial ring is a triangular defect in external oblique aponeurosis. It is bounded by the lateral and medial crura formed by the external oblique aponeurosis and the base of the triangle is formed by the pubic crest.



(Fig. 1)

Boundaries of inguinal canal

- Anterior: External oblique aponeurosis and a few fibres of the conjoined muscle (especially of internal oblique) laterally.
- Superior: Arched fibres of the conjoined muscle (5).
- Inferior: Inguinal ligament and the lacunar ligament on the medial side (Gimbernat's ligament).
- Posterior: Fascia transversalis and the conjoined tendon medially. Thus, the inguinal canal is strong in the lateral part anteriorly and the medial part posteriorly.

Contents of inguinal canal

1. Spermatic cord

CONTENTS OF THE SPERMATIC CORD

- Vas deferens
- Testicular artery
- Artery to the vas
- Cremasteric artery
- Pampiniform plexus of veins
- Lymphatics
- Sympathetic nerves
- Genital branch of genitofemoral nerve
- Processus vaginalis

2. Ilioinguinal nerve

ILIOINGUINAL NERVE

- The ilioinguinal nerve is a branch of the first lumbar nerve (L1). It separates from the first lumbar nerve along with the larger iliohypogastric nerve.
- Ilioinguinal nerve does not pass through the deep inguinal ring. It only travels through part of the inguinal canal.
- After going through inguinal canal, it pierces the internal oblique muscle, distributes nerve fibres to it, and then accompanies the spermatic cord through the superficial inguinal ring.
- Divides into anterior scrotal nerve and anterior labial nerve.
- Supplies the skin of the upper and medial part of the thigh, scrotum and vulva.
- Entrapment or injury to the ilioinguinal nerve is one of the causes of posthemiorrhaphy pain.
- Hence, a few recommend division of ilioinguinal nerve during hernia surgery.

3. Genital branch of genitofemoral nerve

4. Round ligament in females

5. Vestigial remnant of processus vaginalis sac.

Myopectineal orifice of Fruchaud (Fig. 2)

- This weak area is the site of all groin hernias according to Fruchaud.
- It is the area between inguinal ligament anteriorly and iliopubic tract posteriorly.
- Iliopubic tract: It is the thickened inferior margin of the transversalis fascia which appears as a fibrous band running parallel and posterior (deep) to inguinal ligament. It inserts into superior pubic ramus to form lacunar ligament.
- Boundaries of myopectineal orifice of Fruchaud:

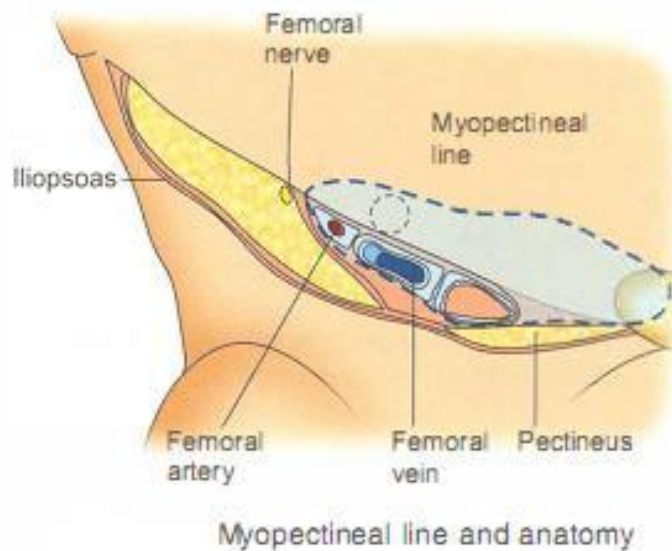
Superiorly: Arched fibres of internal oblique

Laterally: Iliopsoas muscle

Medially: Lateral border of rectus abdominis muscle

Inferiorly: Pubic pecten-Cooper's ligament

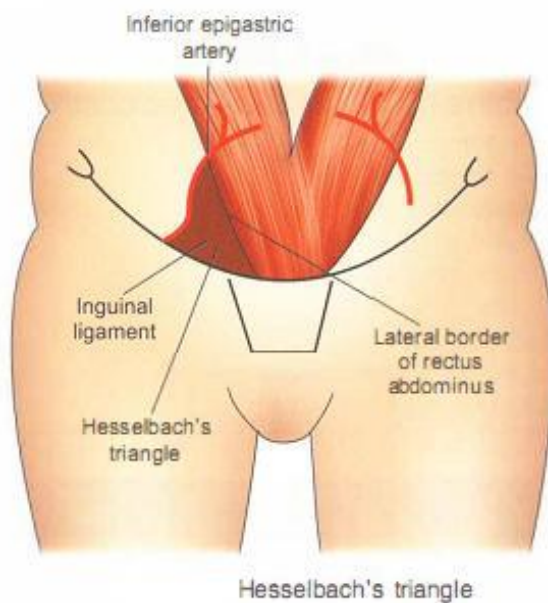
- Surgical importance of iliopubic tract: Recognition of this is a part of laparoscopic repair (initial step)-visualising from within. This structure reinforces posterior wall and floor of inguinal canal as it bridges structures traversing subinguinal space.



(Fig. 2)

Hesselbach's triangle (Fig. 3)

- It is bounded medially by lateral border of rectus abdominus muscle, laterally by inferior epigastric artery and inferiorly by inguinal ligament.
- Direct hernias occur commonly through Hesselbach's triangle (medial), indirect hernia lateral to inferior epigastric artery.



(Fig. 3)

INGUINAL DEFENCE MECHANISMS

1. Obliquity of inguinal canal (in children it is straight).
2. During straining or coughing, the conjoined tendon contracts, and since it forms the anterior, superior and posterior boundaries, it closes the inguinal canal-shutter or sphincter-like effect.
3. Increased intra-abdominal pressure produces plugging effect at the external ring. The deep ring is pulled upwards and laterally because it is adherent to the posterior surface of transversalis muscle. This occludes the ring and prevents herniation-Ball valve effect.

CLASSIFICATION OF HERNIA

I. The European hernia society classification:

- Primary (P), Recurrent (R)
- Lateral (L), Medial (M), Femoral (F)
- Defect size assumed to be 1.5 cm

Thus primary direct hernia with 3 cm defect size is written as PM2.

II Anatomical classification

1. Indirect hernia
2. Direct henia

III. Nyhus classification

This classification is based primarily on the defect, which helps in planning an appropriate repair.

Type I: Indirect hernia with normal deep ring

Type II: Indirect hernia with dilated deep ring

Type III: Based on posterior wall defect

- a. Direct
- b. Pantaloon
- c. Femoral

Type IV: Recurrent hernia.

IV. Gilbert's classification (Table)

- It is based on the defect in the posterior wall (direct hernia) or defect in the internal ring (indirect).
- Depending upon the defect, the suggested repair is given below. However, basic principles are the same.
- The last two types-Type VI and Type VII are modifications by Robbin.

Gilbert's classification and suggested repair		
Types	Classification	Repair
I.	Snug internal ring Preperitoneal indirect sac Does not admit one finger	Herniorrhaphy or hernioplasty
II.	Moderately enlarged internal ring Bubonocoele Admits one finger	Herniorrhaphy or hernioplasty
III.	Large defect—2 or 3 finger-breadths internal ring. May be sliding hernia	Preperitoneal mesh by slitting transversalis fascia
IV.	Large direct hernia with full blow out defect Internal ring is normal	Mesh repair
V.	Direct hernia with punched out hole/defect in the transversalis fascia The internal ring is intact	Plug the defect or purse-string closure of the defect followed by mesh repair
VI.	Pantaloon hernia	Mesh repair
VII.	Femoral hernia	Femoral hernia repair

AETIOLOGY OF HERNIA: WHAT CAUSES HERNIA?

- Indirect hernia occurs largely due to persistent processus vaginalis sac. Manifestations of this can be seen in elderly patients in whom an indirect hernia can be triggered by some actors which increase intra-abdominal pressure.
- Direct hernia occurs mainly due to weakness of transversalis fascia in Hesselbach's area. Increase in abdominal pressure can occur due to chronic cough, constipation or difficulty in passing urine, development of ascites (portal hypertension, nephrotic syndrome), etc.
- Collagen disorder: In prune-belly syndrome, collagen fibre disorder causes development of not only hernias but also intestinal hernias, bilateral hernias, etc.
- Hernia occur due to inherited imbalance in the types of collagen.

CAUSES OF HERNIA	
1. Congenital	Persistent processus vaginalis sac: chief cause of indirect hernia.
2. Collagen fibre disorder	<ul style="list-style-type: none"> • Prune-belly disorder—congenital • Smoking: Acquired collagen deficiency
3. Obesity	
4. Chronic causes of increased intra-abdominal pressure	<ul style="list-style-type: none"> • Chronic cough • Chronic constipation • Straining at micturition • Ascites
5. Weakness of conjoined tendon/rupture of a few fibres	<ul style="list-style-type: none"> • Lifting heavy weight • Postappendicectomy—injury to ilioinguinal nerve. • Chronic illness/debilitating disease causing weakness of transversalis fascia in the Hesselbach's area.

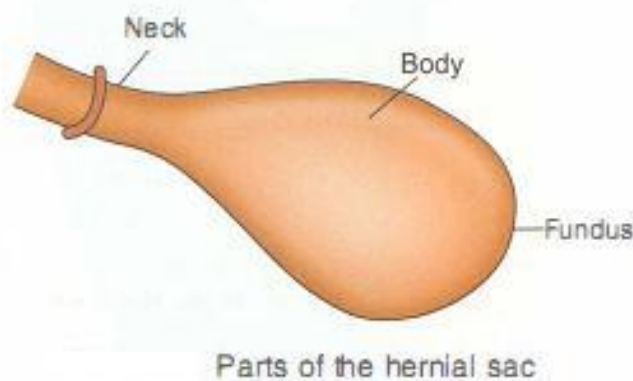
INDIRECT HERNIA

It is a herniation of abdominal contents through the deep ring into the inguinal canal. Indirect hernia occurs due to persistent processus vaginalis sac. It is the most common type of hernia in the body. The preformed sac passes through the deep ring, traverses the inguinal canal and may extend into the scrotum through the external ring. As it comes into the inguinal canal, it is invested by the following coverings:

1. External spermatic fascia derived from external oblique aponeurosis.
2. Cremasteric fascia derived from internal oblique.
3. Internal spermatic fascia from fascia transversalis.

Parts of the hernia (Fig. 4)

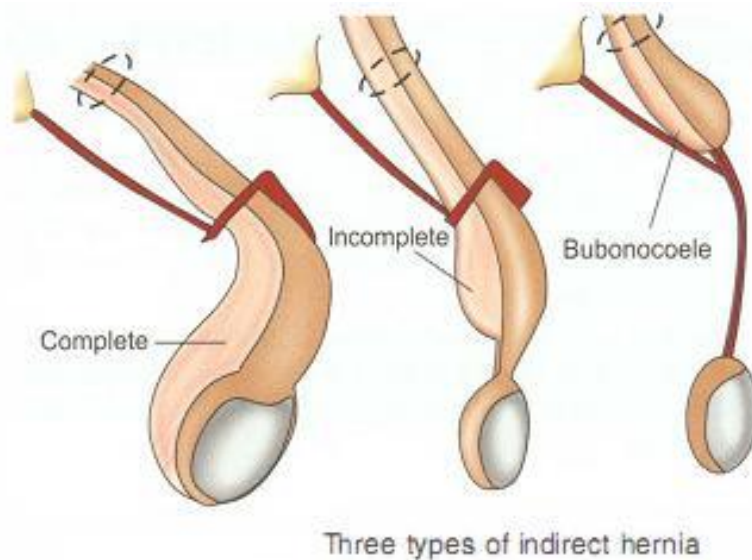
Hernial sac is part of the peritoneum which is dragged into the inguinal canal. The mouth of the sac is in the peritoneal cavity. The neck is the narrowest portion (deep ring). The actual hernial sac has a body and a fundus. Depending upon the contents it can be named as follows: Omentumomentocoele, Intestine-enterocoele, Littre's hernia-hernia containing Meckel's diverticulum. It may also contain ovary or appendix. When part of the wall of the gut is involved, it is known as Richter's hernia.



(Fig. 4)

Types of indirect hernia (Fig. 5)

1. Complete hernia (scrotal): When the sac is patent up to the bottom of the scrotum, it is a complete scrotal hernia.
2. Funicular: The processus vaginalis sac is patent up to the root of scrotum, it is an incomplete indirect hernia.
3. Bubonocoele: Processus vaginalis sac is confined to the inguinal region or the inguinal canal only. Such hernias are seen in young patients.



(Fig. 5)

Coverings of the indirect inguinal hernia from outside to inside

1. Skin
2. Two layers of superficial fascia: Fatty and membranous (Camper's and Scarpa's fascia respectively).
3. External spermatic fascia, a continuation of the external oblique aponeurosis.
4. Cremaster muscle and fascia, a continuation of the internal oblique.
5. Internal spermatic fascia: Derived from the fascia transversalis.
6. Extraperitoneal fat
7. Peritoneum

DIRECT HERNIA

It is always acquired. It occurs through Hesselbach's triangle, a weakness in the posterior wall of the inguinal canal (transversalis fascia). Its boundaries are:

- Medially: Lateral border of the rectus abdominis
- Laterally: Inferior epigastric artery
- Below: Inguinal ligament

Precipitating factors

1. Weakness of fibres of transversus abdominis or congenital absence of a few fibres is a major factor responsible for direct hernia.
2. In elderly patients, it is precipitated by:
 - Chronic cough, chronic bronchitis
 - Pops on coughing
 - Difficulty in passing urine due to benign prostatic hypertrophy (BPH).
 - Chronic constipation due to habitual constipation, or malignancy of left colon.

3. Smoking: Decreased strength of abdominal muscles due to decreased elastin.

CLINICAL EXAMINATION OF A CASE OF HERNIA

History

- Swelling in the inguinal region which is gradually increasing in size.
- To start with, the swelling disappears on lying down and increases on straining, walking, etc. Later it cannot be reduced (due to adhesions).
- History of dragging pain indicates omentocele.
- Since the omentum is attached to the stomach above and supplied by T10, the pain is referred to the umbilical region.
- Sudden, severe pain in the hernia, vomiting and in·educibility indicates 'obstructed hernia'.
- H/o chronic cough, constipation, difficulty in passing urine should be asked. If present, it may suggest the cause of hernia.

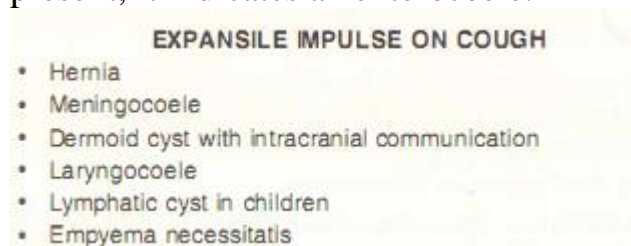
History of appendicectomy

Division of ilioinguinal nerve during appendicectomy may cause denervation of fibres of the right transversus abdominis, which forms 'U' shaped ring, resulting in weakness of the abdominal wall.

Inspection (a model case of incomplete hernia)

It should be done in the standing position. Both sides should be checked.

- There is a swelling in the inguinal region extending to the root of the scrotum measuring about 6 x 3 cm. Its surface is smooth, borders are round and skin over the swelling is normal and it is pyriform in shape.
- Ask the patient to cough-expansile impulse on cough is present. If peristalsis is present, it indicates an enterocoele.



- Presence of scar indicates a recurrent hernia. Ragged scar indicates infection.
- Direct hernia pops out as soon as the patient stands and often it is bilateral.

Palpation

- Inspector findings should be confirmed.
 - Swelling is soft, and gurgles if it is an enterocoele.
 - It may be firm or granular if it is an omentocele.
1. Ask the patient to cough-expansile impulse is felt at the root of scrotum.
 2. Getting above the swelling
- should be done in the standing position.

- At the root of scrotum, the spermatic cord is palpated between the finger and the thumb. In cases of complete indirect hernia, spermatic cord cannot be felt as a naked structure because it is covered anterolaterally by the sac. This is called as getting above the swelling not possible (negative).

3. Reducibility-ask the patient to lie down.

- If the swelling becomes smaller or disappears, it is a hernia (hydrocoele is not reducible).

- Omentocoele: Initially, reduction is easy but later, becomes difficult (due to adhesions).

- If it is difficult to reduce, ask the patient to reduce it. Otherwise, lex and medially rotate the hip and try to reduce it, a method called as taxis.

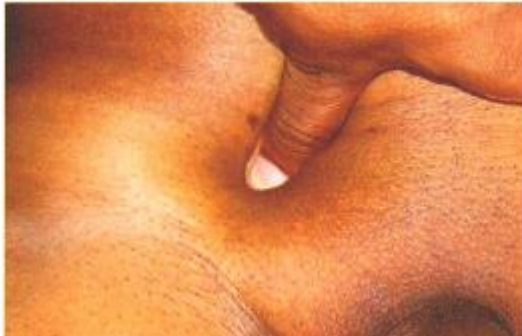- If in spite of this, the swelling is not reduced, it is called as an irreducible hernia.

4. External ring invagination test:

At the root of the scrotum, skin is gathered and lifted up with the little finger. It is then invaginated into the external ring. As the external ring is stretched in indirect henia, the inger goes obliquely

and laterally. In a direct hernia, the finger goes backwards, and the superior ramus of the pubic bone can be felt as a bare bone. On asking the patient to cough, the impulse touches the pulp of the finger in direct hernia and the tip in indirect hernia.

5. Internal ring occlusion test (deep ring occlusion test):



Reduce the swelling first. Locate the deep ring above the midpoint between anterior superior iliac spine and symphysis pubis. Occlude the deep ring with the thumb and ask the patient to cough.

a. If impulse and the swelling are seen, it is a direct hernia because it occurs in the Hesselbach's triangle (medial to deep ring).

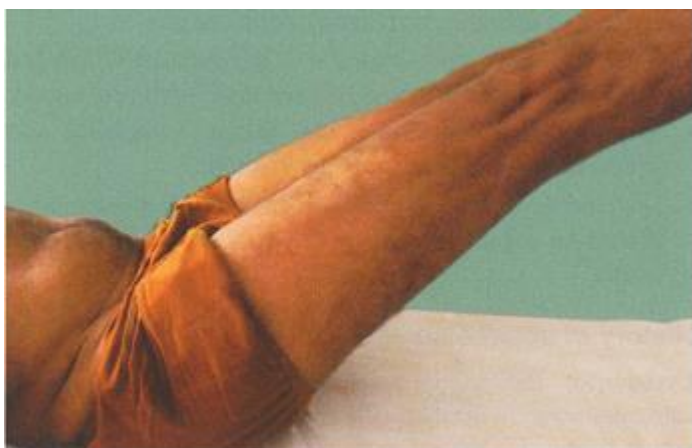b. If the swelling is not seen, it is an indirect hernia. Deep ring occlusion test can be done with the patient in standing and supine position.

Problems of deep ring occlusion test

a. If occlusion is not done properly, results may vary.

b. Pantaloon hernia (Romberg hernia, saddlebag hernia, dual hernia). It is a direct henia having indirect component.

6. Leg raising test or head raising test



- Weakness of oblique muscles is manifested by Malgaigne's bulgings above the medial half of inguinal ligament. It is an absolute indication for hernioplasty.
- Malgaigne's bulgings indicate weakness of the oblique muscles of the abdominal wall.

7. Zieman's method: Three inger method

Keep index finger at deep ring, middle finger on the posterior wall above and lateral to the external ring and ring finger at femoral ring. Now ask the patient to cough.

Depending upon the type of hernia, impulse is felt. It is not necessary to perform this test in incomplete or complete indirect hernias.

8. Per abdomen:

To rule out any mass (colonic).

9. Look or phimosis/stricture urethra:

Young patients having urinary complaints with hernia may be suffering from stricture urethra. Lift the scrotum and feel for any strictures in the bulbar urethra. Retract skin of prepuce and rule out phimosis.

10. Per-rectal examination should be done in elderly patients to rule out prostatic enlargement.

11. Examination of respiratory system is done to rule out chronic bronchitis, tuberculosis, etc.

DIFFERENTIAL DIAGNOSIS OF A GROIN SWELLING (Fig. 6)

Groin refers to the junction of lower abdomen with the thigh. Hence, swellings in the inguinal region and upper thigh close to the inguinal ligament are included under groin swellings.

1. Inguinal hernia

2. Femoral hernia: The main sac is below and lateral to pubic tubercle .

3. Vaginal hydrocoele: Fluctuation and transillumination tests are usually positive and getting above swelling is possible. (Please note that in infantile hydrocoele and hydrocoele en bisac, getting above swelling is not possible).

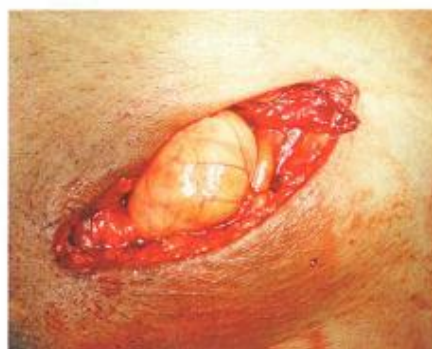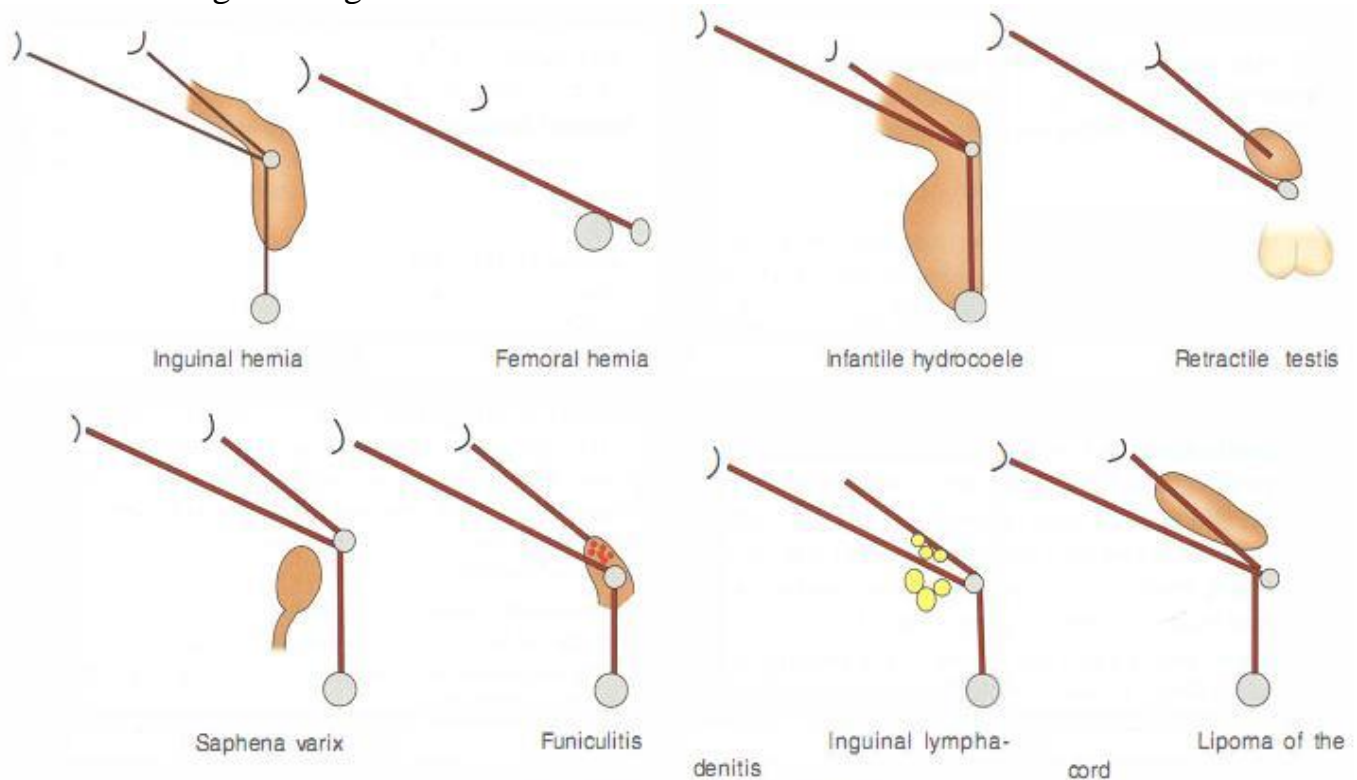
4. Retractable testis: It can present as a firm swelling in the inguinal region. Scrotum is empty.

5. Saphena varix: Patient can present with a swelling in the thigh. Swelling is usually about 2.5 cm below the pubic tubercle. A swelling that disappears on elevation of the leg is characteristic of a swelling of venous origin.

6. Funiculitis: A funiculitis can occur with or without acute epididymo-orchitis. Severe pain in the inguinal region, tender swelling, high grade fever with chills and rigors are characteristic. Spermatic cord is thickened and swelling is not reducible.

7. Inguinal lymphadenitis: Pain and nodular swelling below inguinal ligament is a feature. It is not reducible and some source of infection in the lower limb is usually present.

8. Lipoma of the cord: It presents as a soft, lobulated but irreducible swelling in the inguinal region.



Left inguinal lipoma of the cord

(Fig. 6)

Differences between direct and indirect hernia		
	Direct hernia	Indirect hernia
1. Age	Common in elderly	Can occur in any age group
2. Aetiology	Weakness of posterior wall of inguinal canal	Preformed sac
3. Precipitating factors	Chronic bronchitis, enlarged prostate	—
4. On standing	Pops out	Does not pop out
5. Side	Usually bilateral	Unilateral (30% bilateral)
6. Internal ring occlusion test	Swelling is seen	Swelling is not seen
7. Malgaigne's bulgings	May be present	Absent
8. Complications	Not common because neck is wide	Common, neck is narrow—obstruction and strangulation
9. Relationship of sac to the cord	Sac is posterior to the cord	Sac is anterolateral to the cord
10. Direction of the sac	It comes out of Hesselbach's triangle	Sac comes through the deep ring

Clinical differences between hernia and hydrocoele		
	Indirect complete hernia	Vaginal hydrocoele
1. Standing position	Swelling of scrotum and inguinal region	Swelling confined only to scrotum
2. Impulse on coughing	Present	Absent
3. Getting above swelling	Not possible	Possible
4. Reducibility	Usually present unless complicated	Not reducible
5. Consistency and transillumination	Soft, gurgling, no transillumination	Soft, fluctuant, transillumination is present

INVESTIGATIONS

1. Routine investigations such as complete blood picture (CBP) and urine examination are done. In elderly patients, chest X-ray, electrocardiography or even pulmonary function tests may be necessary. Patients with urinary complaints are evaluated for prostatic enlargement and stricture urethra.

2. Ultrasound: Hernia is a clinical diagnosis. In the vast majority of the cases, no investigations are required specific to the diagnosis of hernia.

However, in appropriate cases imaging can be done.

- In so-called occult cases wherein patient has groin pain but clinically not evident. Ultrasound can detect a sac—however it is operator dependant, ultrasound is also useful in cases of postoperative swelling in the groin to rule out haematoma/ seroma/recurrence.

3. Computed tomography(CT) scan is ideal in cases of giant hernias, or special types such as obturator hernia, perineal hernia, etc.

4. Magnetic resonance imaging (MI): Ideal in sportsmen who complain of groin pain, to detect hernia or to rule out muscle sprain or any other orthopaedic disorders.

TREATMENT

1. Herniotomy (Fig. 7)

Excision of the sac alone is done in patients up to 14-16 years of age (children). Hernia occurs due to preformed sac. Hence, no repair is necessary.



(Fig. 7)

2. Herniorrhaphy

- It can be of two types: Bassini's and Shouldice.
- What is done today is the modified Bassini repair.

A. Modified Bassini's herniorrhaphy (Fig.8).

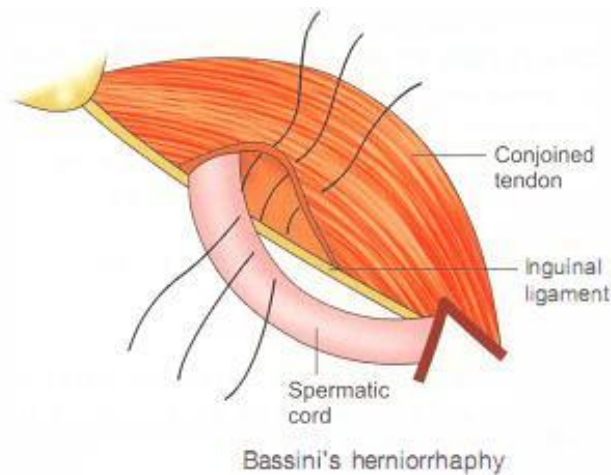
- Herniotomy with approximation of posterior wall of the inguinal canal by suturing the conjoint tendon (above) to the inguinal ligament below, by using interrupted, nonabsorbable suture material such as nylon, thick silk or polypropylene. This is the most popular method. Repair of stretched deep ring by narrowing and laterally displacing the spermatic cord is done (Lytle's repair) in selected cases at the end of the procedure.
- If there is tension, an incision over the anterior rectus sheath will help in doing the repair (Tanner's slide).

Indications of Bassini's herniorrhaphy

- Indirect hernia with good muscle tone.
- Direct hernia with good muscle tone.
- Young patients with good muscle tone.

Criticism for Bassini's herniorrhaphy

- It is a repair with tension
- Conjoint tendon and inguinal ligament approximation is not physiological.



(Fig.8)

B. Shouldice repair

SHOULDICE REPAIR

- **First layer:** Double breasting of the transversalis fascia.
- **Second layer:** Conjoined tendon is sutured to inguinal ligament.
- **Third layer:** Upper half of external oblique aponeurosis is sutured to inguinal ligament.

- It is the most popular tensionless method wherein only local tissues are used.
- After opening the inguinal canal, hemiotomy is done.
- Transversalis fascia which forms the posterior wall, is incised from the internal ring till pubic tubercles.
- Thus, upper and lower flaps of transversalis fascia are sutured in a double-breasting manner by using non-absorbable sutures such as 34 gauge stainless steel wire, polyamide or polypropylene. This is the first layer of Shouldice repair.
- The second layer is like Bassini's, where in conjoint tendon is sutured to the inguinal ligament by using nonabsorbable sutures.
- The third layer is completed by suturing upper lap of external oblique aponeurosis to the inguinal ligament.
- The results have been good in Shouldice's hands. The operation needs expertise.

3. Hernioplasty

Indications

1. Indirect or direct hernia with a good muscle tone. In such cases, darning can be done.
 2. Indirect or direct hernia with weak muscle tone, meshplasty is preferred.
 3. Recurrent hernia
- Hernioplasty refers to strengthening the posterior wall of inguinal canal. There are two types of hemioplasties which

are commonly practised-A. Mesh repair, B. Daning.

A. Strengthening: The posterior wall (Lichtenstein repair) of inguinal canal by a prolene mesh or Marlex mesh. The fibroblasts and capillaries grow over the mesh, converting it into a thick fibrous sheath and strengthening the posterior wall. The mesh is fixed inferiorly to lacunar and inguinal ligaments, medially to overlap rectus sheath and fixed to fascia over the pubic bone. A few interrupted sutures are put to fix it to the transversalis fascia. Laterally, an artificial deep ring is created by crossing of both upper and lower leaves of the mesh. To attain this, a slit is given on one side of mesh. (Lacunar ligament is that portion of the inguinal ligament which extends backwards and upwards to the pectineal line and forms the medial margin of the femoral ring).

COMPLICATIONS OF HERNIA SURGERY

These are common complications after surgery. Often they are mild and not so worrisome. However, some of the complications can be serious which require immediate attention and treatment.

1. Complications during surgery

- Injury to the iliac vessels: The most serious but rare complication is injury to iliac vessels. It can happen in thin patients when suturing of the inguinal ligament is done from lateral to medial side. The sudden jet of fresh red blood indicates that the bite has been taken through the artery. It is better to call the vascular surgeon, extend the incision, have a proximal control, suture directly or do a resection and end to end anastomosis. They have to be anticoagulated with low molecular weight heparin followed by oral anticoagulants.
- Injury to the urinary bladder: This can happen when anatomy is not clear as in few giant or scrotal hernias, perineal hernias or distortion due to previous surgery. Sudden finding of clear fluid with urinary smell means bladder injury. Immediate repair with 2-0 vicryl followed by urinary catheter placement or 3 weeks is the treatment.

2. Early postoperative period

- Pain: Pain is common due to the incision in the skin and some degree of retraction of structures such as inguinal ligament downwards and conjoint tendon upwards. The pain can be decreased by local anaesthetic infiltration, examples bupivacaine 0.25% up to a maximum of 2 mg/kg body weight.
- Bleeding: Perfect haemostasis is the aim of all surgeries. In spite of this, a few bleeders may open up, mostly venous blood-may be pampiniform plexus veins or arterial blood from inferior epigastric artery. The bleeding may stop with compression bandage. Otherwise, exploration and ligation of bleeders needs to be done in the operation theatre.

- Urinary retention is common, more so in males: Pain, spinal or epidural anaesthesia, sedatives, lack of privacy are contributing actors. Provide analgesia, privacy and hot omentation to suprapubic region. If all of these sae, catheterise bladder as a last step.

- Abdominal distension: This is not common. It can happen when large intestinal contents of the hernia sac are reduced or handled as in scrotal hernias or sliding hernias. It is also important to realise that omentum is attached to stomach and colon above. One should see that bleeders from injured arteries of the omentum should be ligated properly. Some intraperitoneal blood may add to paralytic ileus.

3. Intermediate-between 3 and 7 days

- Seroma is due to inflammatory response to mesh or suture materials. It causes swelling and anxiety that it may be a recurrence. When in doubt, get an ultrasound examination first. Seroma needs to be aspirated. Seroma is more common after laparoscopic hernia repairs.

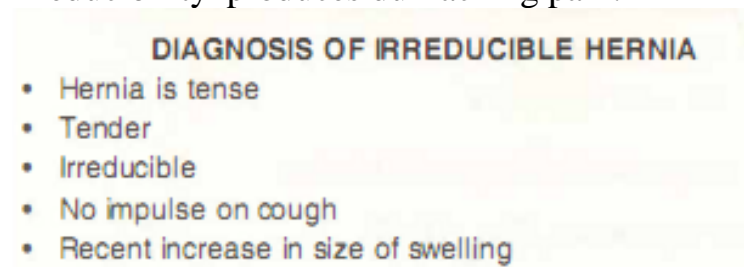
- Wound infection: Henia is a clean surgery. Infection should not occur. However, poor handling of the tissues, haematoma, seroma and diabetes may precipitate wound infection. Open the sutures, drain the pus and use appropriate antibiotics in such cases. Persistent wound infection may prompt removal of the mesh. A few cases of tuberculosis have been reported. This is due to improper sterilisation of the mesh used.

4. Late: Late complications are not all that common. One complication which bothers a few patients is chronic pain called inguinodynia.

COMPLICATIONS OF HERNIA

1. Irreducibility

Occurs due to adhesions formed between omentum, sac and the contents. Irreducibility produces dull aching pain.

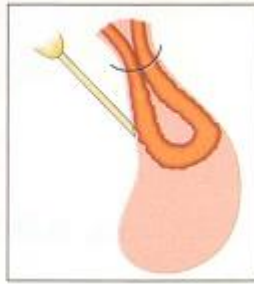


2. Obstructed hernia (Key Box 34.9 and Fig. 34.30)

Irreducible hernia + obstruction to the lumen of the gut gives rise to obstructed hernia. Clinically, it produces severe colicky abdominal pain, abdominal distension, vomiting and step ladder peristalsis.

FACTORS RESPONSIBLE FOR OBSTRUCTED HERNIA

- Narrow neck
- Irreducibility
- Sudden straining
- Too many contents
- Long duration of hernia
- Sliding hernia



Treatment

Urgent division of the neck of the sac followed by herniorrhaphy or henioplasty.

3. Strangulated hernia

Irreducibility + obstruction + impairment of blood supply to intestine.

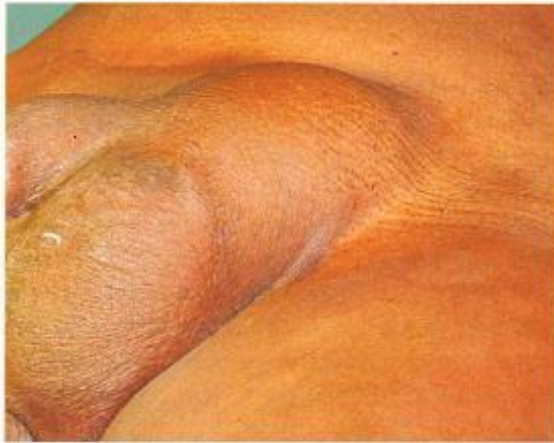Pathology

- Strangulation commonly occurs in femoral hernia, obturatorhernia and in indirect hernia.
- Initially the venous return is occluded, the part gets congested and mucosal ulceration and haemorrhage occurs into the gut wall. It also results in oedema due to capillary exudation.
- If the obstruction is not relieved, constriction of the artery takes place resulting in gangrene of bowel. If this happens, there is a proliferation of bacteria.
- Gangrene appears at the ring of constriction first. Later it develops in the antimesenteric border.
- Such a gangrenous segment contains decomposed blood in which gram-negative organisms multiply. They produce endotoxins resulting in endotoxic shock. If the gangrene extends into the intra-abdominal segment of the bowel, peritonitis can occur.
- The deep ring and the external ring are the common constricting agents.

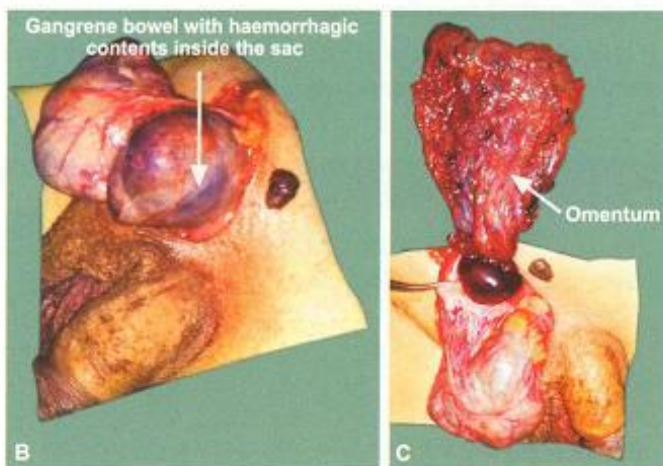
Clinical features

- Sudden, severe, prolonged pain with some features of shock are indicative of strangulation.
- Clinical examination of such hernia reveals (Fig. 9):
 1. Tense (hernial sac is tense-differentiates it from obstructed hernia)
 2. Tender
 3. No impulse on cough
 4. Irreducible
 5. Recent increase in the size of the swelling
 6. General condition of the patient is poor:
- Feeble pulse

- Hypotension
- Rebound tenderness
- Guarding and rigidity, if infection has spread intra-peritoneally.
- Absent bowel sounds
- Toxic look



Strangulated hernia



Strangulated hernia with gangrene

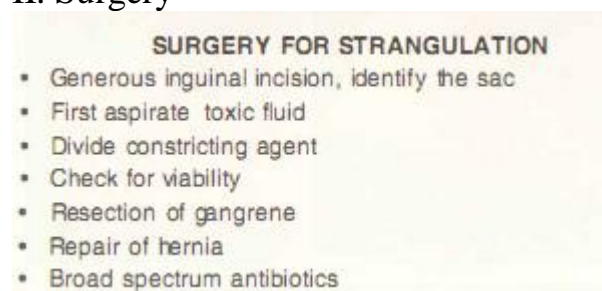(Fig. 9)

Treatment

I. General measures

- The patient is hospitalised. The foot end of the bed is raised so that an irreducible hernia may reduce by gravity. However, if there is a suspicion of gangrene, this step is not recommended.
- A Ryle's tube is introduced to decompress the stomach, thus preventing vomiting and reducing abdominal distension.
- Intravenous fluids are given to correct dehydration and to prevent renal failure.
- Narcotic analgesics are required to reduce the pain.
- An attempt should be made to reduce the swelling when there is no gangrene by the following measures:
 - A. Good sedation
 - B. Patient's thigh is flexed, adducted and medially rotated
 - C. With the right hand, the sac is gently squeezed by applying pressure over the scrotum. At the same time with the left hand, the proximal portion of the sac is guided into the inguinal canal. This procedure is described as taxis. Taxis is contraindicated if there is gangrene.
 - D. Complications of forced reduction include contusion of intestinal wall, rupture of the sac at the neck and reduction en masse, i.e. the entire sac with the contents are reduced into the abdominal cavity but the intestine still remains strangulated.
- The patient is prepared for surgery and blood is grouped and cross-matched.

II. Surgery



- With broad spectrum antibiotic coverage, the hernia is explored by an inguinoscrotal incision and hernial sac is denied. At this stage, the constricting ring should not be divided. First all the toxic fluid from the sac is aspirated. The constriction is then divided using a grooved director or hernia bistoury. While dividing the constricting ring, the inferior epigastric vessels which are situated medially may be damaged. Therefore, care has to be taken to protect these vessels.
- If the bowel is gangrenous, resection of gangrenous segment and anastomosis is done. Closure of incision includes placement of tube drain, which is brought out through a separate incision.
- If viability of the bowel is doubtful, the intestinal loops are covered with hot wet mops for a period of 5-10 minutes and 100% oxygen is given to the patient (request the anaesthetist). Return to pink colour, peristalsis of bowel and pulsations in the mesentery indicate viability.

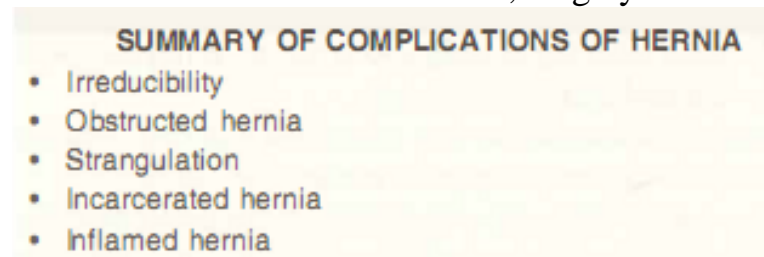
- If the general condition of the patient permits, repair of the hernia may also be done. If evidence of peritonitis is present or if gangrene is spreading within, laparotomy should be done.

4. Incarcerated hernia

It is an obstructed hernia due to obstruction caused by faecal matter. It generally occurs in a sliding hernia

5. Inflamed hernia

It occurs when the contents of hernia get inflamed, e.g. appendicitis in a hernial sac, Meckel's diverticulitis in hernial sac. Thus, complications of hernia can be dangerous. It may range from a simple obstruction to a life-threatening strangulation. Hence, early diagnosis and early treatment are necessary in all cases of indirect hernia. In a few selected cases of direct hernia, wherein the defect is big, the chances of strangulation are less. However, if there are no medical contraindications, surgery has to be advised.



RECURRENT HERNIA

Causes

I. Preoperative

1. Chronic cough
2. Weak muscle tone
3. Straining while passing urine, constipation
4. Obesity, ascites, anaemia.

II. Intraoperative

1. Improper excision of the sac: The sac should be ligated at the level of deep ring (neck). This is called high ligation of the sac. Very often, the sac is seen as soon as the inguinal canal is opened. If it is ligated at the fundus or body (low ligation), it invariably results in recurrence. A missed indirect sac can be a cause of recurrence (Fig 10).



(Fig 10)

2. Absorbable sutures such as catgut have lifespan of 2-3 weeks. If they are used for reconstruction, they invariably result in recurrence.
3. Bleeding: At the end of the surgery, small bleeding points should be coagulated by using diathermy or ligatures. Haematoma formation predisposes to infection, which can be the cause of recurrence.
4. Tension between suture lines can cause strangulation and fibrosis of muscle fibres. Hence, care and gentleness is important while suturing conjoined tendon to the inguinal ligament.

III. Postoperative

1. Persistent postoperative cough weakens the suture line.
2. Haematoma can get secondarily infected resulting in pus formation. The sutures give way leading to recurrence. Hence, if there is a significant haematoma, it should be drained.
3. Infection: Even though hernia is a clean surgery, chances of infection are present especially in diabetics, alcoholics and immunocompromised patients. Prophylactic antibiotics such as 2nd generation cephalosporin should be given. If infection occurs, it should be treated accordingly.
4. Exertion: Too much exertion in the postoperative period, in the form of lifting heavy weights or carrying heavy weights on the shoulder, may weaken the suture line, resulting in hernia.

Most of the recurrences occur within one year. Incidence of recurrent hernia may vary from 2 to 8% even in experienced hands. In a case of recurrent hernia, it is difficult to say whether it is a direct hernia or indirect hernia. From the management point of view, it does not matter.

Treatment

- If the sac is present due to incomplete excision at the previous surgery, it should be completely excised up to the level of deep ring, followed by hernioplasty.
- Meshoplasty is the surgical treatment of a recurrent hernia. However, if mesh cannot be placed either due to infection or due to nonavailability, prolene plication can be done.
- Tuberculosis must be ruled out in cases of persisting infection.
- In all these cases, precipitating factors if any, should be treated first.
- The only way to totally prevent recurrence is by closure of the deep ring. This can be done only after dividing the spermatic cord (Kuntz procedure). It is indicated in elderly patients who have multiple recurrences.

1. Length of inguinal canal is:

- A. 4cm
 - B. 6 cm
 - C. 8 cm
 - D. 10 cm
2. Which was not a boundary of the Hesselbach's triangle?
 - A. Rectus abdominis
 - B. Inguinal ligament
 - C. Inferior epigastric artery
 - D. Testicular artery
 3. Following are true about external ring except:
 - A. It is not a ring
 - B. It is a defect in the internal oblique aponeurosis
 - C. Invagination test is done through external ring
 - D. It transmits spermatic cord
 4. About deep inguinal ring, which one of the following is true?
 - A. It is a defect in the external oblique aponeurosis
 - B. It is a defect in the internal oblique aponeurosis
 - C. It is a defect in the transversalis fascia
 - D. It is a defect in the cremasteric fascia
 5. Following are true or deep inguinal ring except:
 - A. Deep ring is a defect in the transversalis fascia
 - B. Indirect hernia sac comes out lateral to the deep ring
 - C. Pantaloon hernia can be on both sides of deep ring
 - D. It is closed at the end of hernia repair to prevent recurrence
 6. The ideal surgical treatment or sliding inguinal hernia will be:
 - A. Herniotomy
 - B. Bassini's herniorrhaphy
 - C. Marsey's repair
 - D. Lichtenstein's repair
 7. Following are contents of the spermatic cord except:
 - A. Vas deferens
 - B. Testicular artery
 - C. Genital branch of genitofemoral nerve
 - D. Ilioinguinal nerve
 8. About sliding inguinal hernia following are true except:
 - A. Urinary bladder can be the part of hernial sac
 - B. It can be both direct or indirect type
 - C. The hernial sac should be twisted like as in indirect hernia treatment
 - D. Often it is irreducible
 9. Richter's hernia refers to:
 - A. Hernia containing intestines
 - B. Strangulated hernia
 - C. Only a part of circumference of the intestine is caught in a hernial sac
 - D. Hernia containing urinary bladder
 10. Immediate structure anterior to direct hernial sac is:
 - A. External oblique aponeurosis
 - B. Internal oblique aponeurosis
 - C. Transversalis fascia
 - D. Posterior rectus sheath

ANSWERS

1-A 2-D 3-B 4-C 5-D 6-D 7-D 8-C 9-C 10-C

Literature:

1. K Rajgopal Shenoy, Anitha Shenoy. Manipal Manual of Surgery. CBS Publishers & Distributors. Forth Edition. 842-877.

2. Harold Ellis, Sir Roy Calne, Christopher Watson. General Surgery Lecture Notes. Wiley BlackWell. 2016. 239-250
3. Schumpelick V, Zimmer M (eds) (1990) Atlas of hernia surgery. Decker, New York .
4. Meyer G, Schildberg FW (eds) (1997) [Endoscopic hernioplasty] Johann Ambrosius Barth, Germany .
5. Morris-Stiff G J, Hughes L E. The outcome of nonabsorbable mesh placed within the abdominal cavity: Literature review and clinical outcome. J Am Coll Surg. (1998);186:352–367.
6. Hay J M, Boudet M J, Fingerhut A, Poucher J, Hennes H, Habib E, Veyriers M, Flamant Y. Shouldice inguinal hernia repair in the male adult: The gold standard? Ann Surg. (1995);222:719–727.
7. Rutkow I M. et al. Demographic, classificatory and socioeconomic aspects of hernia repair in the United States. Surg Clin North Am. (1993);73:413–426.
8. Schumpelick V, Conze J, Klinge U. [Preperitoneal mesh-plasty in incisional hernia repair. A comparative retrospective study of 272 operated incisional hernias] Chirurg. (1996);67:1028–1035.
9. Holzheimer RG, Mannick JA, editors. Munich: Zuckschwerdt; 2001. Surgical Treatment: Evidence-Based and Problem-Oriented.
10. Chevrel JP (ed) (1997) Hernias and surgery of the abdominal wall. Springer, Berlin Heidelberg New York

All the illustrated materials are taken from «Manipal Manual of Surgery. CBS Publishers & Distributors. Fourth Edition. Edited by K Rajgopal Shenoy, Anitha Shenoy»