

Стом-21ИИ

Federal State Budget Educational Institution of Higher Education “North-Ossetian State Medical Academy” of Ministry of Health of the Russian Federation

Department of Otorhinolaryngology and Ophthalmology

**GUIDELINES FOR INDEPENDENT (EXTRACURRICULAR) WORK
in otorhinolaryngology**

of the main professional educational program of higher education - the specialist's program
31.05.03 Dentistry,
approved as of “24” May 2023.

Vadikavkaz 2023

These guidelines are designed for extracurricular independent work of 4th year students (8th semester) of the Faculty of Medicine.

FSBEI HE NOSMA of the Ministry of Health of Russia
in otorhinolaryngology

Compilers:

Head of the Department of Otorhinolaryngology with Ophthalmology, FSBEI HE NOSMA of the Ministry of Health of Russia

Associate Professor, Doctor of Medical Sciences E.T. Gappoeva,

Assistant Professor, Dept. of Otorhinolaryngology with Ophthalmology, FSBEI HE NOSMA of the Ministry of Health of Russia

Candidate of Medical Sciences V. P. Kudzieva

Reviewers:

Head of the Department of Pharmacology and Clinical Pharmacology Doctor of Medicine,
Professor L.Z. Bolieva

Professor of the Department of Internal Medicine , Doctor of Medical Sciences, Professor A.S.
Tsogoev

Lesson 1

Topic: Methodology and technique of endoscopic examination of ENT organs.

Examination questions:

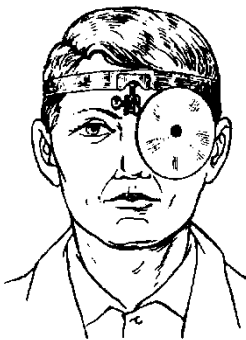
1. General principles of examination of otorhinolaryngological patients.
2. Organization of the otorhinolaryngologist's workplace.

<p>The student should know:</p> <ol style="list-style-type: none">1. General provisions, sequence of methods of investigation of ENT organs2. Normal condition when performing investigation of ENT-organs <p style="padding-left: 40px;">Features of pediatric otorhinolaryngology</p>	<p>References:</p> <p>Nosulya E. V. Propaedeutics in otorhinolaryngology. - Medical Information Agency. - 2009 г. -P.5-32</p> <p>2)Palchun V.T., Magamedov M.M., Luchikhin L.A. Otorhinolaryngology textbook. - 2007. P.7-77</p> <p>3)Lectures of the department where the student studies</p>
<p>The student should be able to:</p> <ol style="list-style-type: none">1. Use a frontal reflector2. Perform external examination of ENT organs3. Perform anterior and posterior rhinoscopy, pharyngoscopy, indirect laryngoscopy, otoscopy	<p>References:</p> <p>1)Luchikhin L.A. Otorhinolaryngology. Textbook. – Approved by MoE RF. - GEOTAR Media. - 2016 . - 584 p.</p> <p>2) Luchikhin L.A. Examination of the otorhinolaryngological patient. - GEOTAR-Media. - 2014 г. - 256 p.</p> <p>3)Palchun V.T. Diseases of the ear, throat and nose. Textbook for students of secondary vocational education institutions studying in the specialty 060101.51 "Medicine" in the discipline "Diseases of the ear, throat and nose". - GEOTAR-Media. - 2016 . - 315 p.</p>


Self-study assignments:

1. The room for the examination of ENT organs should be _____
2. During the examination, the patient is _____ of the doctor, and the light source is _____
3. The sequence of examination of ENT organs is as follows: _____

4. Rhinoscopy can be _____
5. Examination of the upper part of the pharynx and the back of the nose is called _____
6. _____ The following instruments should be used to inspect the upper pharynx _____
7. The middle section of the pharynx is examined with _____
8. The lower part of the pharynx and larynx (indirect laryngoscopy) is examined with _____
9. Phonation is the pronunciation of the following vowels _____
10. Otoscopy is performed with the following instrument _____, while the examination begins with the _____ ear.
11. In order to see the loose part of the tympanic membrane, the patient's head must be _____
12. On palpation of the cartilage of the larynx it is normally determined _____



Pic.1. The position of the frontal mirror on the doctor's head.



Pic. 2. Name the instruments depicted in the photo

Lesson 2

Topic: Clinical anatomy, physiology and research methods of the auditory analyzer.

Examination questions:

1. The structure of the outer, middle ear, the anatomy of the cochlea
2. Physiology of the ear.
3. Methods of ear research

<p>The student should know:</p> <ol style="list-style-type: none"> 1. Clinical anatomy of the external ear 2. Middle ear cavity system, walls, contents of the tympanic cavity 3. Topography of the facial nerve. Types of structure of the mastoid process. Structure of the auditory tube 4. Blood supply and innervation of external and middle ear 5. Structure of the cochlea and its receptor apparatus 6. Physiology of the ear: sound conduction and sound perception 7. Methods of ear examination 	<p>References:</p> <ol style="list-style-type: none"> 1) Palchun V.T. Diseases of the ear, throat and nose. Textbook for students of secondary vocational education, studying in the specialty 060101.51 "Medicine" in the discipline "Diseases of the ear, throat and nose. - GEOTAR-Media. - 2016 . - 315 p. 2) Palchun V. T., Luchikhin L.A., Magomedov M.M. Guidelines for practical otorhinolaryngology. - MIA. - 2011. - 565 p. 3) Stratieva O.V. Clinical anatomy of the ear. - SPb: SpetsLit. - 2004. - 256 p. - Boboshko M.Y. The auditory tube. - SPb: SpetsLit. - 2003. - 353 p. 4) Lectures of the department where the student studies
<p>The student should be able to:</p> <ol style="list-style-type: none"> 1. Conduct an examination of the external ear 	<p>References:</p>

<p>2. Carry out otoscopy, characterize the condition of the tympanic membrane (light reflex, identification points)</p> <p>3. Determine, with testing, the patency of the auditory tube and eardrum motility</p> <p>4. Interpret the X-ray of the temporal bones, according to Schüller, Meyer, Stenvers</p> <p>5. Determine and characterize the auditory passport (whispering, speaking, air and bone conduction determinations, Rinne, Federici, Jelle, Weber tests)</p> <p>6. Interpret the main types of audiograms, tympanograms.</p>	<p>1) Palchun V. T., Luchikhin L.A., Magomedov M.M. Guide to Practical Otorhinolaryngology. - MIA. - 2011. – 565 p.</p>
---	---

Self-study assignments:

1. The outer ear consists of _____
2. The boundary between the outer ear and the middle ear is _____
3. The untensioned part of the tympanic membrane lacks a layer of _____
4. The tympanic membrane has 5 identifying points _____ and 4 quadrants _____
5. The middle ear consists of the following communicating air cavities _____
6. The tympanic cavity has 6 walls _____ and three floors _____
7. The tympanic cavity contains 3 auditory ossicles _____ and 2 muscles _____
8. The mastoid begins to form at the age of _____ and is completed by _____ years old and has the following types of structure _____
9. The bony labyrinth consists of _____
10. The peripheral receptor of the auditory analyzer _____ consists of _____ cells
11. Diffraction is _____
12. Echo is _____

- 13.Reverberation is _____
- 14.Interference is _____
- 15.Resonance is _____
- 16.The auditory potential threshold is characterized by_____
17. Intensity and loudness of sound is _____
- 18.The strength of sound is measured in _____, the frequency in _____

Tests

1. THE EAR LABYRINTH IS LOCATED IN THE

- 1) mastoid process
- 2) scales of the temporal bone
- 3) temporal bone pyramid 4) zygomatic process

2. AUDITORY PATHWAY OF THE SOUND ANALYZER

- 1) Reissner's membrane of the cochlea
- 2) Corti's organ
- 3) Tympanic membrane and auditory ossicles

3. SOUND CONDUCTING PART OF THE AUDITORY ANALYZER

- 1) eardrum and auditory ossicles
- 2) external auditory pathway
- 3) Corti's organ
- 4) endolymph

4. ISTHMUS IN THE EXTERNAL AUDITORY CANAL IS IN

- 1) bony region
- 2) membranous-cartilaginous region
- 3) tip of the membranous-cartilaginous part to the bony part.

5. THE COCHLEAR AQUEDUCT OPENS INTO THE FOSSA

- 1) anterior
- 2) posterior
- 3) middle

6. THE SIGMOID SINUS IS LOCATED IN THE FOSSA

- 1)anterior
- 2)middle

3) posterior

7. BERNARD'S CANALS ARE ON THE WALL OF THE EXTERNAL AUDITORY CANAL

1) lower

2) upper

3) anterior

4) posterior

8. THE FIRST NEURON OF THE AUDITORY ANALYZER IS LOCATED IN

1) tympanic cavity

2) cochlea

3) internal auditory canal

4) medulla oblongata

9. HEARING TESTING BY SPEECH.

1) tympanometry

2) tonal audiometry

3) acumetry

4) impedance meter

10. IN EARLY CHILDHOOD THE EXTERNAL AUDITORY CANAL IS REPRESENTED BY

1) spinous-cartilaginous

2) bony

3) the membranous-cartilaginous part and the bony part

11. LOWER WALL OF TYMPANIC CAVITY IS BORDERED BY

1) temporomandibular joint

2) sigmoid sinus

3) bulb of jugular vein

4) internal carotid artery

12. NORMALLY A HUMAN BEING PERCEIVES WHISPERED SPEECH AT A DISTANCE OF

1) 4m

2) 6m

3) 10m

4) 20m

13. RINNE'S TEST IS NEGATIVE WITH

1) diseases of the sound-perceiving section of the sound analyzer

2) diseases of the sound-conducting section of the sound analyzer

3) in the normal condition

14. THE DRUM CAVITY IS CONNECTED WITH THE HEARING TUBE BY

1) nasopharynx

2) nasal cavity

3) snail

4) antrum

15. THE STRETCHED PART OF THE DRUM BOARD CONSISTS OF _____ LAYERS

1) 2

2) 3

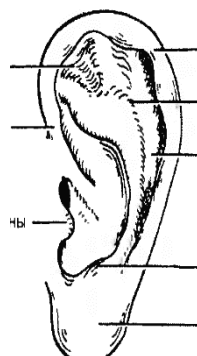
3) 4

4) 5

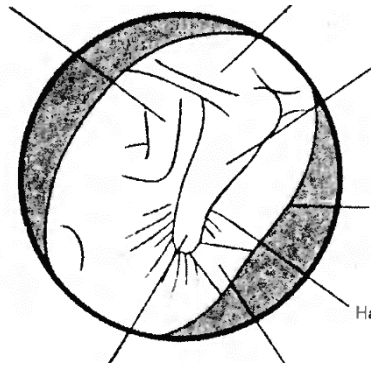
Keys to the test

«Clinical anatomy and physiology of ear»

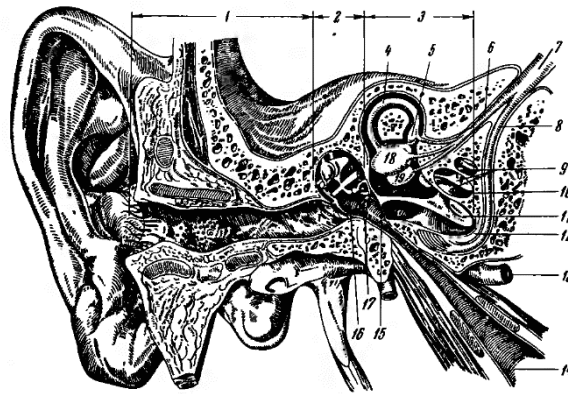
№	Answer	№	Answer
1	3	9	3
2	3	10	1
3	3	11	4
4	3	12	2
5	2	13	2
6	3	14	1
7	1	15	2
8	2		



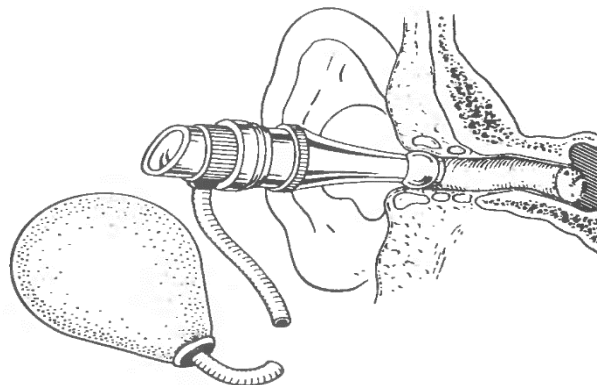
Pic. 10. Indicate the main structures of the ear auricle



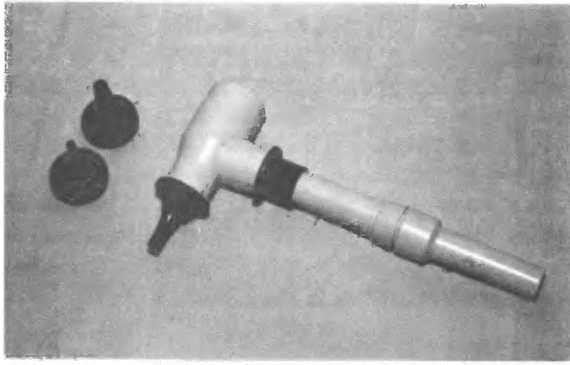
Pic.11. Indicate the parts, quadrants and identification points of the tympanic membrane.



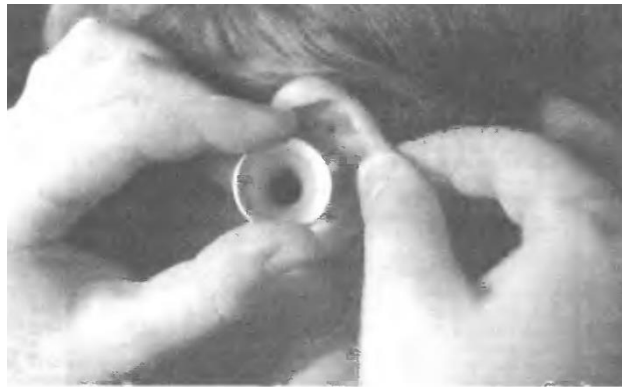Pic. 12. What formations are indicated on the vertical section of the ear.



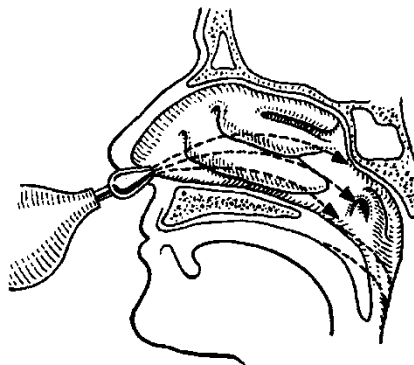
Pic.3. What is the name of the examination method and with what tool is it performed?



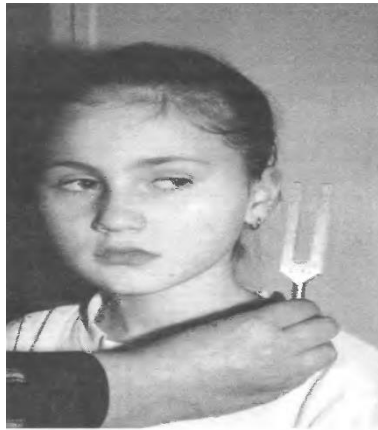Pic. 4. Name the instrument



Pic.5. What method of examination is indicated in the picture, how the auricle is retracted in children and adults.



Pic.6. What instrument is used and how is this method of examination performed?



Pic.7. What conductivity is tested in the picture and what is the name of the instrument.

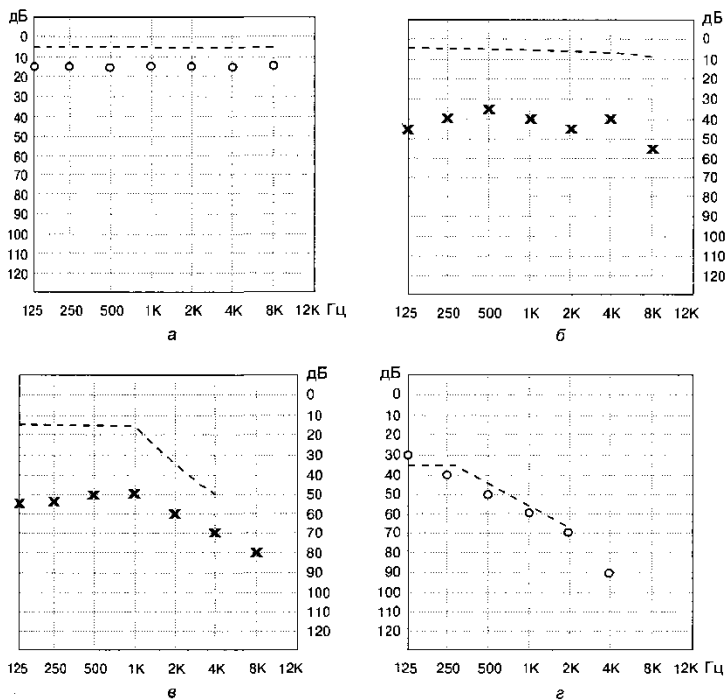


Fig. 8. Name the examination method, what is the dB, Hz. What types of conductivity are seen in this examination.

Lesson 3

Topic: Clinical anatomy, physiology and research methods of the vestibular analyzer.

Examination questions:

1. Anatomy of the vestibular ampullae, ampullae of the semicircular canals
2. Vestibular analyzer, connections of nuclei with different formations of CNS and peripheral nervous system
3. Methods of examination of the vestibular analyzer

The student should know:

1. Clinical anatomy of the vestibule, ampullae of the semicircular canals,

References:

<p>structure of the receptor apparatus of the sacs</p> <ol style="list-style-type: none"> 2. Nuclei of the vestibular analyzer and their connections with other parts of the CNS 3. Adequate stimuli of ampullary apparatus and otolith apparatus 4. Basic regularities of nystagmus (Ewald and Voyacek's laws). 5. Methods of examination of vestibular function 	<ol style="list-style-type: none"> 1)Altman Ya. A., Tavartkiladze G.A. Guide to Audiology. - Moscow: DMKPress, 2003. - 360 p. 2)Luchikhin L.A. Otorhinolaryngology. Textbook. – Approved by the MoE RF. -GEOTAR Media. - 2016 г. - 584 p. 3) Luchikhin L.A. Examination of the otorhinolaryngological patient. - GEOTAR-Media. - 2014 . – 256p
<p>The student should be able to:</p> <ol style="list-style-type: none"> 1. Define and characterize spontaneous nystagmus 2. Perform index tests (finger-nose, finger-finger, Vodak-Fisher test) 3. Examine stability in Romberg pose, and perform straight and flank gait 4. Perform rotational, caloric, and pressor tests 	<p>References:</p> <ol style="list-style-type: none"> 1)Palchun V.T. Diseases of the ear, throat and nose. Textbook for students of secondary vocational education, studying 060101.51 "Medicine" for the discipline "Diseases of the ear, throat and nose. - GEOTAR-Media. - 2016 . - 315 p. 2)Luchikhin L.A. Examination of an otorhinolaryngological patient. - GEOTAR-Media. - 2014 . - P. 248- 326 3)Alexeeva N.S. Vertigo. Otoneurological aspects.- MedPress- Inform. - 2014. -184 p.

Assignments for independent work:

1. The following pockets are located in the vestibule _____.

1. The anterior portion of the vestibule communicates with the cochlea through _____ and the posterior portion with _____

2. The semicircular canals _____, they are arranged in planes

3. Endolymph differs from perilymph in the composition of potassium and sodium ions: _____

4. The otolith membrane is represented by _____

5. Vestibular –spinal connections provide _____ connection

6. Vestibular-oculomotor connections provide _____

7. Vestibulo-vegetative connections provide _____
8. Vestibular-cerebellar ways _____
9. Vestibular –cortical connections _____
10. Adequate stimuli for ampullary receptors are _____
and for the otolithic apparatus _____
12. Spontaneous vestibular symptoms include _____
13. Adiadochokinesis is _____
14. The advantage of the caloric test is _____
15. Objective methods of assessing static balance are _____

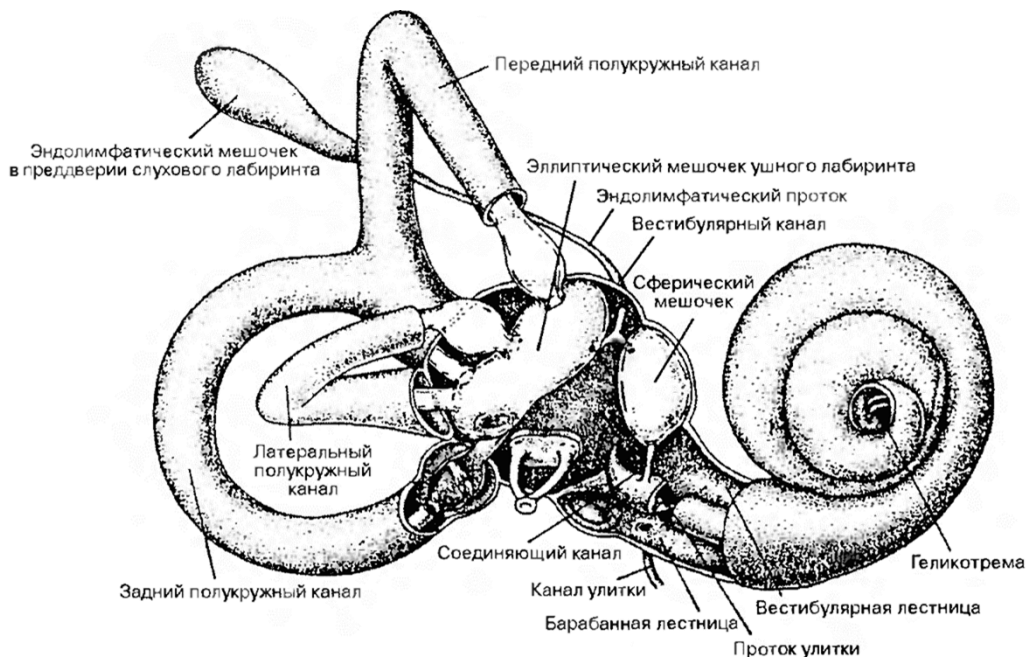


Fig.14. Which structures of the inner ear are shown in the figure.

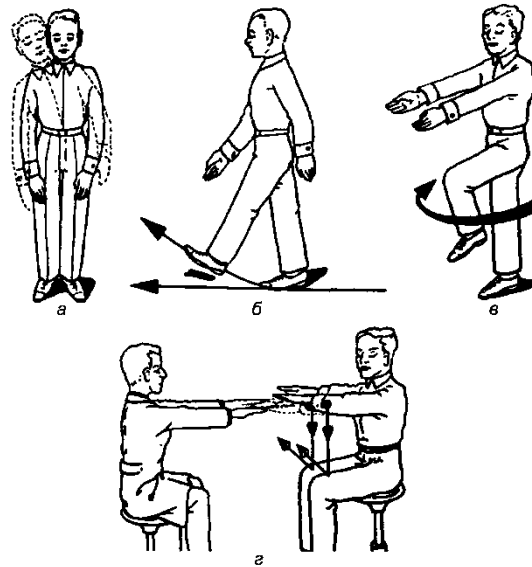


Fig. 9. Specify the vestibular tests.

Tests

1) IN THE VOYACEK TEST, WE OBSERVE ____ DEGREES OF TORSO DEVIATION

- 1) two
- 2) three
- 3) four
- 4) five

2) ADEQUATE STIMULUS OF THE RECEPTORS OF SEMICIRCULAR CANALS IS

- 1) angular acceleration
- 2) straight-line acceleration
3. acceleration of gravity

3) ADEQUATE STIMULUS OF OTOLITH APPARATUS IS

- 1) straight-line acceleration, acceleration of gravity
- 2) angular acceleration, straight-line acceleration
- 3) gravity acceleration, angular acceleration
- 4) straight-line acceleration, angular acceleration

4) THE INNER EAR CONSISTS OF

- 1) tympanic cavity, vestibule, and semicircular canals
- 2) vestibule, cochlea, internal auditory canal
- 3) vestibule , semicircular canals, cochlea
- 4) tympanic cavity, vestibule, internal auditory canal

5. THE FIRST NEURON OF THE VESTIBULAR APPARATUS IS LOCATED IN

- 1) tympanic cavity
- 2) cochlea
- 3) vestibule
- 4) internal auditory canal

6. DURING THE ROTATION TEST IN BARANY ROTATIONAL CHAIR THE PATIENT'S HEAD IS TILTED TO THE

- 1) left side
- 2) right side
- 3) 30 degrees forward
- 4) 30 degrees backward

7. DIRECTION OF NYSTAGMUS IS DETERMINED BY THE DIRECTION OF

- 1) slow component of nystagmus at very abstraction of eyes
- 2) fast component of nystagmus at the most distant part of the eyes
- 3) slow component of nystagmus when looking straight ahead
- 4) fast component of nystagmus when looking straight ahead

8. DEGREE IS REGISTERED WHEN THE EYEBALLS ARE MOVED TOWARD

- 1) slow component
- 2) fast component
- 3) when looking straight ahead
- 4) is not registered

9. WHEN PERFORMING THE OTOLITH TEST, THE PATIENT IS BENT OVER

- 1) right side
- 2) left side
- 3) 45 degrees forward
- 4) 90 degrees forward

10. WHAT DEGREE OF NYSTAGMUS IS DETERMINED BY LOOKING TOWARD THE SLOW COMPONENT

- 1) first
- 2) second
- 3) third

11. DIRECTION OF NYSTAGMUS DURING CALORIC TEST WITH COLD WATER

- 1) upwards

- 2) in the opposite side
- 3) in the same direction
- 4) rotatory

12. EXAMINATION METHODS OF FUNCTION OF SEMICIRCULAR CANALS

- 1) otolith test
- 2) rotary test
- 3) test on four-pointed Hillov's swing
- 4. electrocochleometry

13. EXAMINATION OF OTOLITH APPARATUS FUNCTION IS PERFORMED USING

- 1) two-pole swing
- 2) four-pin swing
- 3) rotation test
- 4) caloric test

14.THE SECOND EWALD'S LAW STATES

- 1) the direction of endolymph motion corresponds to the direction of the slow nystagmus component
- 2) direction of endolymph motion corresponds to the direction of the fast component of nystagmus
- 3) rotation of the body to the right excites the left labyrinth
- 4) rotation of the body to the left excites the right labyrinth

15. NUMBER OF DEGREES OF NYSTAGMUS

- 1) I
- 2) II
- 3) III
- 4) IV

Keys:

«Clinical anatomy and physiology of the vestibular apparatus»

№	Answer	№	Answer
1	2	10	3
2	1	11	2
3	1	12	2
4	3	13	2
5	4	14	1

6	3	15	3
7	2		
8	2		
9	4		

Lesson 4.

Topic: Clinical anatomy, physiology and research methods of the nose, paranasal sinuses and pharynx.

Examination Questions.

1. Clinical anatomy of the external nose, nasal cavity.
2. Blood supply, innervation, lymphatic ways of external nose, nasal cavity.
3. Olfactory analyzer
4. Anatomy, topography of paranasal sinuses.
5. Physiology, methods of investigation of the nose and paranasal sinuses.

<p>The student should know:</p> <ol style="list-style-type: none"> 1. Bony and cartilaginous bases of the external nose, blood supply, innervation of the external nose. 2. Walls of the nasal cavity, nasal passages. 3. Features of the structure of the nasal cavity in young children. The role of nasal breathing in the physical development of the body and in the formation of the dental system in children. 4. Structure of the paranasal sinuses. 5. Functions of the nose. 6. Methods of investigation of the nose and paranasal sinuses. 	<p>References:</p> <ol style="list-style-type: none"> 1) Palchun V. T., Magamedov M.M., Luchikhin L.A. Otorhinolaryngology textbook. - Moscow ed. GEOTAR-Media. - 2011 . - 656 p. 2) Lectures of the department where the student studies
--	---

<p>The student should be able to:</p> <ol style="list-style-type: none"> 1. Perform examination, palpation of the external nose. 2. Perform anterior, posterior rhinoscopy, characterize normal rhinoscopic picture 3. Determine nasal respiratory function, olfactometric kit 4. Interpret radiographs in naso-frontal, naso-subchinoscopic projections. Characterize CT scans. 	<p>References:</p> <ol style="list-style-type: none"> 1) Piskunov G.Z., Piskunov S. Z. Clinical rhinology. - MOSCOW: MIA. - 2013. – P. 27-98 2) Lectures of the department where the student studies
---	--

Assignments for independent work.

1. The upper respiratory tract consists of _____
2. The cartilaginous part of the nasal septum is represented by _____
3. The bony base of the external nose consists of _____
4. The angular vein communicates with the _____
5. The motor innervation of the external nose is carried out _____, and the sensitive innervation _____
6. In the lower wall of the nasal cavity passes _____
7. The medial wall of the nasal cavity _____, which consists of _____
8. The growth area is located in the _____
9. Upper wall of the nasal cavity _____
10. The lateral wall of the nasal cavity includes the following formations _____
11. In the middle nasal passage open the sinuses, in the upper _____, in the lower _____
12. The osteomeatal complex _____
13. The Kisselbach zone is located _____
14. Where is the junction of the maxillary sinus with the middle nasal passage?
15. The posterior wall of the frontal sinus borders the _____

16. The following formations border the lateral wall of the sphenoid sinus _____

17. The labyrinthine labyrinth is divided into 3 types of cells _____

18. Basic physiological functions of the nose are _____

19. Mucociliary clearance _____

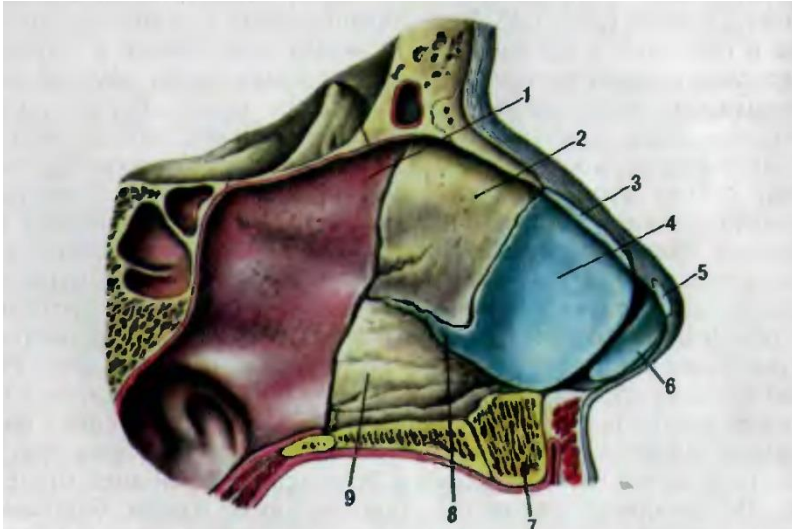


Fig.15. Indicate the formation in the picture

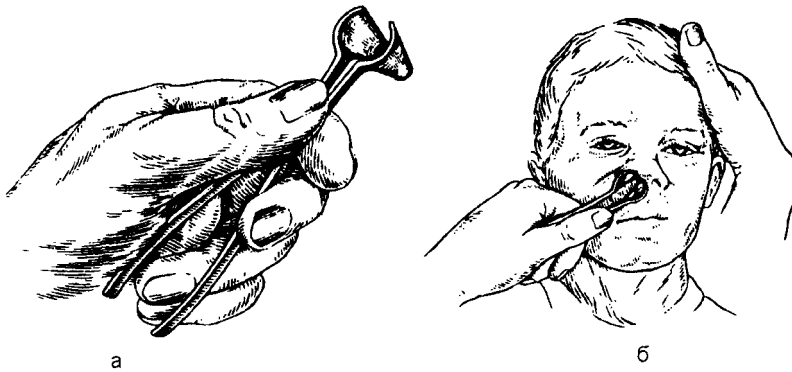


Fig.16. Name the instrument and the nose examination method

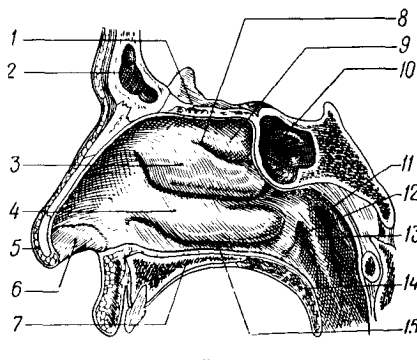


Fig. 17. Indicate what formations are depicted in the picture according to their localization.

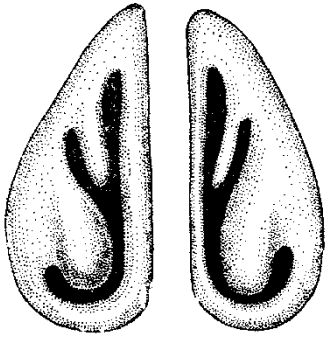


Fig.18. Which nasal shells are visible on this method of examination.

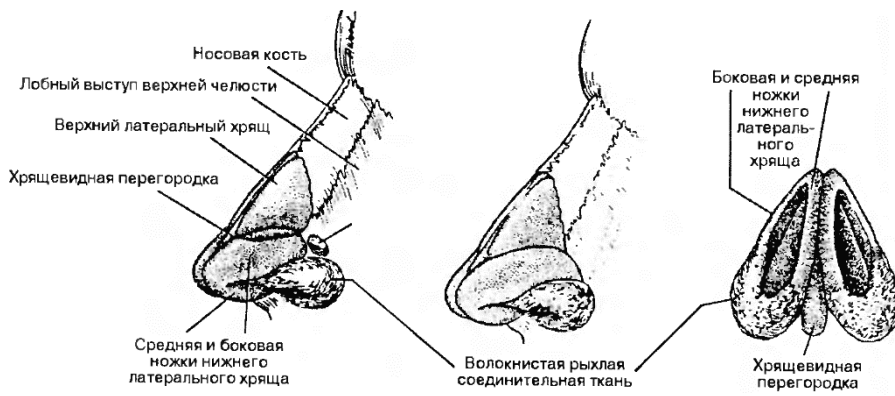


Fig. 19. Specify the cartilage and bones that make up the external nose.

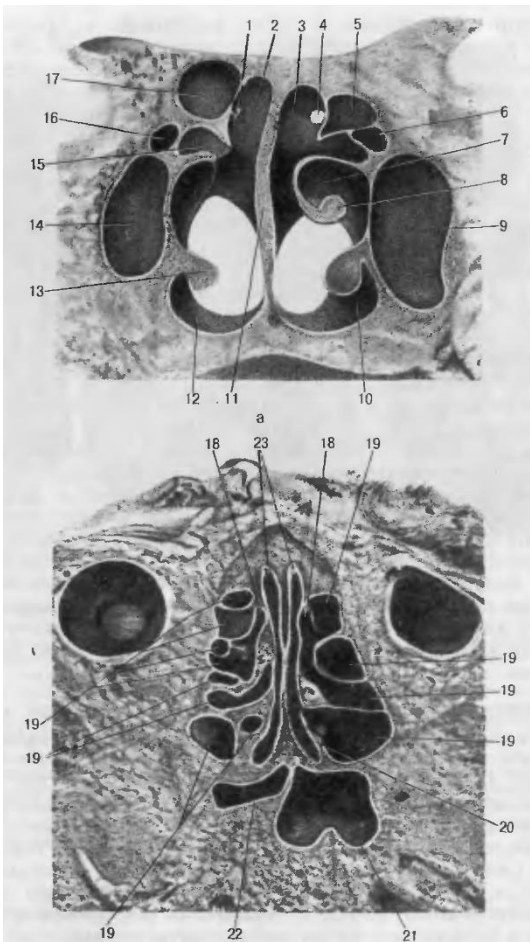


Fig.20. Indicate the paranasal sinuses.

Tests

1. THE NASAL SEPTUM IS FORMED BY

- 1) triangular cartilage, labyrinth, cusp
- 2) palatine bone, cusp, quadrangular cartilage
- 3) Perpendicular plate of the lamina, cusp, quadrangular cartilage, nasal scallop of the maxilla
- 4) nasal bone, quadrangular cartilage, crossover

2. THE NASOLACRIMAL CANAL OPENS INTO THE _____ NASAL PASSAGE

- 1) upper
- 2) middle
- 3) lower
- 4) common

3. THE MAXILLARY SINUS OPENS INTO THE _____ NASAL PASSAGE

- 1) upper
- 2) middle
- 3) inferior

4) general

4. THE FRONTAL SINUS OPENS INTO THE _____ NASAL PASSAGE

1) upper

2) middle

3) inferior

4) common

5. ETHMOIDAL LABYRINTH BORDERS ON THE _____ CRANIAL FOSSA

1) anterior

2) middle

3) posterior

6. THE ANTERIOR CELLS OF THE ETHMOIDAL LABYRINTH OPEN INTO THE _____ NASAL PASSAGE

1) upper

2) middle

3) inferior

4) common

7. THE MIDDLE CELLS OF THE LABYRINTH OPEN INTO THE _____ NASAL PASSAGE

1) upper

2) middle

3) inferior

4) common

8. THE POSTERIOR CELLS OF THE LABYRINTH OPEN INTO THE _____ NASAL PASSAGE

1) upper

2) middle

3) lower

4) general

9. THE SPHENOID SINUS OPENS INTO THE _____ NASAL PASSAGE

1) upper

2) middle

3) lower

4) common

10. CAVERNOUS SINUS IS LOCATED

1) in the anterior cranial fossa

- 2) middle cranial fossa
- 3) posterior cranial fossa
- 4. below the base of the skull

11. EXTERNAL NASAL MUSCLES ARE INNERVATED BY NERVE

- 1) first branch of the trigeminal nerve
- 2) second branch of the trigeminal nerve
- 3) third branch of the trigeminal nerve
- 4) facial

12. EXTERNAL NASAL SKIN IS INNERVATED BY NERVES

- 1) first and second branches of the trigeminal nerve
- 2) facial nerve and the first branch of the trigeminal nerve
- 3) second and third branches of the trigeminal nerve
- 4) facial nerve and second branch of the trigeminal nerve

13. THE THICKEST WALL OF THE FRONTAL SINUS IS _____

- 1) inferior
- 2) posterior
- 3) anterior
- 4) medial

14. THE INTERNAL WALL OF THE MAXILLARY SINUS IS THINNEST AT THE LEVEL OF THE _____ NASAL PASSAGE

- 1) inferior
- 2) middle
- 3) upper

15. OLFACTORY ZONE IN THE NASAL CAVITY IS LOCATED IN THE AREA OF NASAL PASSAGE

- 1) lower
- 2) middle
- 3) upper
- 4) lower common

Keys:

«Clinical anatomy of the nose and sinuses»

№	Answer	№	Answer
1	3	8	1
2	3	9	1

3	2	10	2
4	2	11	4
5	1	12	1
6	2	13	1
7	2	14	2
		15	3

Test Questions

1. Clinical anatomy, blood supply, innervation of the pharynx
2. lymphadenoid pharyngeal ring.
3. Physiology and research methods of the pharynx.

<p>The student should know:</p> <ol style="list-style-type: none"> 1. Walls, divisions, layers of the pharynx. 2. Paratonsillar, parapharyngeal tissue, pharyngeal space. 3. Structure of lymphadenoid ring of Walder-Pyrogov (palatine, pharyngeal, tubal, lingual tonsils). 	<p>References:</p> <ol style="list-style-type: none"> 1) Luchikhin L.A. Otorhinolaryngology. Textbook. - Ministry of Education of the Russian Federation. -GEOTAR- Media. - 2016 - 584 p.
---	--

<p>4. Vessels and nerves of pharynx, its functions.</p> <p>5. Research methods of pharynx.</p> <p><u>The student should be able to.</u></p> <p>1. Perform examination of regional lymph nodes.</p> <p>2. Perform oroscopy, epi-, meso-, hypopharyngoscopy, finger examination of nasopharynx.</p>	<p>2) Ovchinnikov Yu. M., Gamov V. II. Diseases of the nose, throat and ear. - M.: Medicine. - 2003 - 320 p.</p> <p>3) Palchun V. T., Luchikhin L. A. History of the disease in ENT-hospital / Methodical recommendations. - M: Medicine. - 2004 - 32 p.</p>
--	--

Assignment for independent work.

- 1 The pharynx has four walls and three divisions _____
2. The nasopharynx contains _____ tonsils.
3. The pharynx is limited by _____
4. Between the anterior and posterior pharynxes are _____
5. At the back of the pharynx there are clusters of _____
6. The muscles of the soft palate are _____
7. The paratonsillar tissue is located between the _____
8. The parapharyngeal tissue is limited by _____ on the front, by _____ on the inner side, by _____ on the posterior side, by _____ on the lateral side _____.
9. The blood supply of the pharynx is from _____
10. The anterior and posterior pharyngeal venous plexuses are located in _____, blood from them is collected in _____.
11. The act of swallowing has the following phases _____
12. Rhinolalia clause occurs under the following conditions _____
13. Hyponasal speech occurs with _____
14. The method of examination of the nasopharynx is called _____, of oropharynx _____, of larynopharynx _____.
15. The test to determine the contents of the tonsil lacunae is called _____
16. Valleculae are _____
17. _____ Prevents food from entering the pharynx

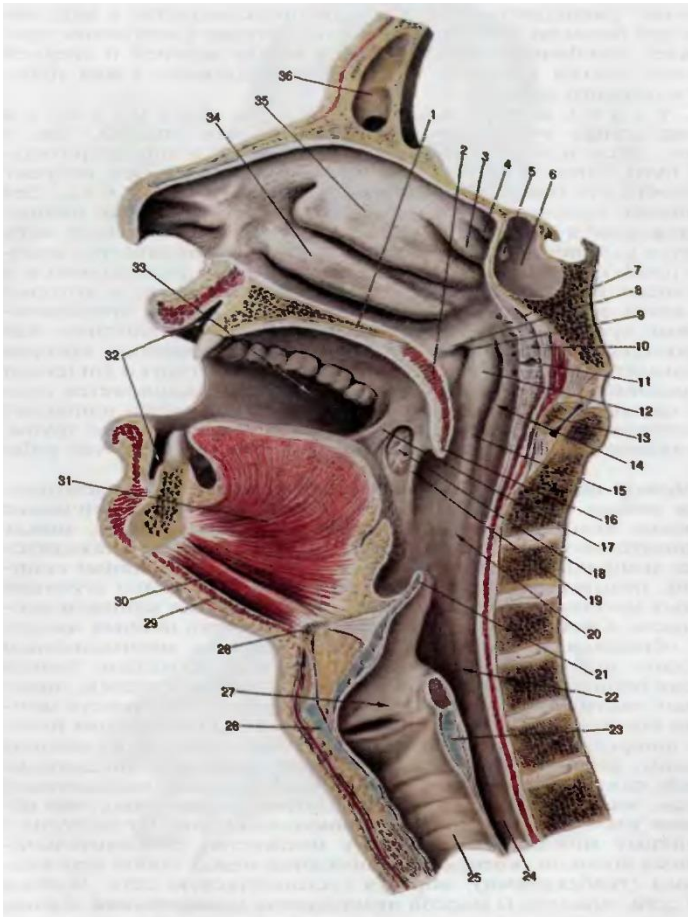


Fig.21. What formations are depicted in the picture according to their location?

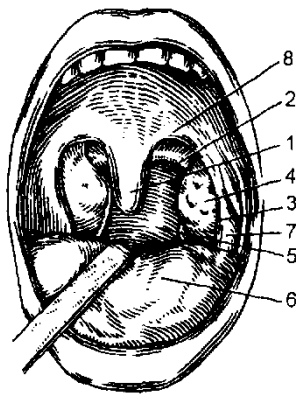


Fig.22.
Structures and
formations
indicated during
pharyngoscopy.

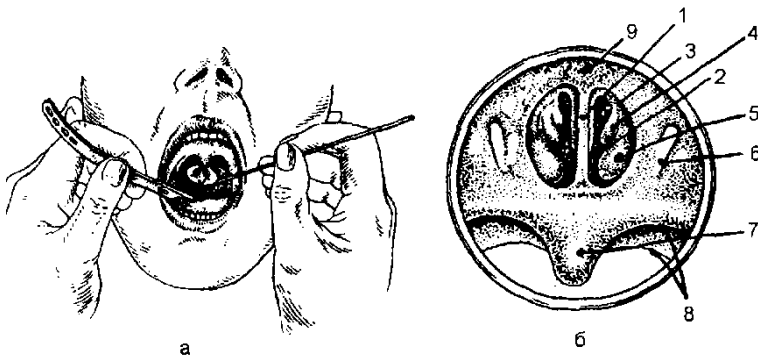


Fig.23. Name the method of examination and nasopharyngeal formations in it.

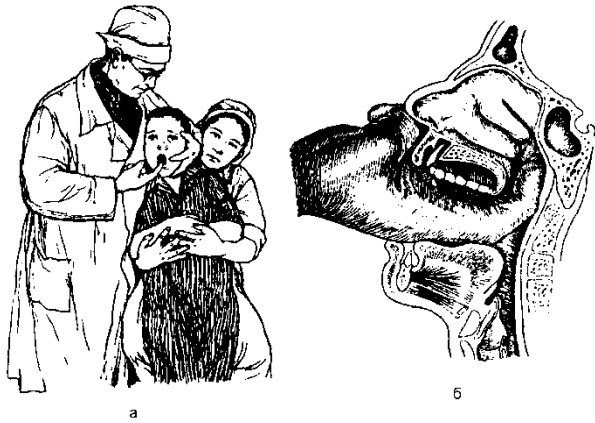

Fig. 24. What is the name of this examination and for which pathology is it performed?

Tests.

THE OROPHARYNX HAS WALLS

1) 2

2) 3

3) 4

4) 5

2.THE MIDDLE PART OF THE GLOTTIS (OROPHARYNX) CORRESPONDS TO THE CERVICAL VERTEBRA

1) 2

2) 3

3) 4

4) 5

3.THE MAJOR ARTERY LOCATED NEAR THE LOWER POLE OF THE PALATINE TONSIL

1) external carotid

2) internal carotid

3) common carotid

4) thyroid

4. THE LATERAL OCULOPHARYNGEAL SPACE BORDERS ON THE

1) Upper constrictor of pharynx

2) middle constrictor of pharynx

3) Pharyngeal muscle

4) medial pterygoid muscle

5.MUSCLE OF THE PHARYNX, NARROWING THE LUMEN OF THE PHARYNGEAL ORIFICE OF THE AUDITORY TUBE

1) Raising the palatine curtain

2) exerting palatine curtain

3) palatotongue

4) palatopharyngeal

6.IMPAIRMENT OF TASTE IN THE POSTERIOR 1/3 OF THE TONGUE IS DUE TO NERVE DAMAGE

1) facial

2) trigeminal

3) lingual-pharyngeal nerve

4) vagus nerve

7.TASTE DISORDER IN THE ANTERIOR 2/3 OF THE TONGUE IS CAUSED BY NERVE DAMAGE

- 1) facial
- 2) trigeminal
- 3) lingual-pharyngeal nerve
- 4) vagus nerve

8. BLOOD SUPPLY OF PALATINE TONSILS IS PROVIDED FROM

- 1) external and internal carotid arteries
- 2) external carotid artery
- 3) internal carotid artery
- 4) facial artery

9. PHARYNX CORRESPONDS TO CERVICAL VERTEBRAE

- 1) I-III
- 2) I-IV
- 3) I-V
- 4) I-VI

10. THE BOUNDARY BETWEEN THE NASOPHARYNX AND OROPHARYNX IS

- 1) Horizontal plane across the tongue surface
- 2) Upper pole of palatine tonsils
- 3) horizontal plane across the hard palate
- 4) margin of the soft palate

11. NUMBER OF TONSILS LOCATED IN THE NASOPHARYNX

- 1) One
- 2) two
- 3) Three
- 4) four

12. THE BOUNDARY BETWEEN OROPHARYNX AND LARYNGEOPHARYNX IS THE LEVEL OF

- 1) root of tongue and epiglottis
- 2) lower edge of soft palate
- 3) lower pole of palatine tonsils
- 4) floor of oral cavity

13. MOTOR INNERVATION OF PHARYNX IS CARRIED OUT BY NERVE

- 1) retrograde
- 2) linguo-pharyngeal and sublingual
- 3) Reciprocating and lingual-pharyngeal nerves

4) Sublingual and recurrent

14. SENSORY INNERVATION OF THE PHARYNX IS CARRIED OUT BY NERVES

- 1) second branch of the trigeminal nerve, vagus nerve and hyoid nerve
- 2) second branch of the trigeminal nerve, vagus nerve and lingual pharyngeal nerve
- 3) first and second branches of the trigeminal nerve, vagus nerve
- 4) first and second branches of the trigeminal nerve and lingualpharyngeal nerve

15. NUMBER OF TONSILS LOCATED IN PHARYNX

- 1) six
- 2) five
- 3) four
- 4) three

Keys:

№	Answer	№	Answer	№	Answer
1	2	6	3	11	3
2	2	7	1	12	1
3	2	8	2	13	3
4	4	9	4	14	2
5	1	10	3	15	1

Lesson 5

Topic: Clinical anatomy, physiology of the larynx, trachea, bronchi and esophagus.

Examination questions:

1. Clinical anatomy of larynx, physiology, methods of examination of larynx.
2. Structure of trachea, bronchi and esophagus.
3. Research methods of larynx, trachea, bronchi and esophagus.

<p>The student should know:</p> <ol style="list-style-type: none"> 1. Cartilage, joints, ligaments and muscles of the larynx and their functions. 2. Structural features of the laryngeal mucosa. 3. Blood supply and innervation, laryngeal lymphatic system. 4. Functions of the larynx. 5. Age-related anatomical and physiological features of the larynx, tracheobronchial tree and esophagus. 6. Structure of the esophagus. 7. Examination methods of larynx, trachea, bronchi and esophagus 	<p>References:</p> <ol style="list-style-type: none"> 1) Luchikhin L.A. Otorhinolaryngology. Textbook. – Approved by of the Ministry of Education of the Russian Federation. - GEOTAR- Media. - 2016 - 584 p. 2) Luchikhin L.A. Examination of an otorhinolaryngological patient. - GEOTAR-Media. - 2014 - 256 p. 3) Palchun V.T. Diseases of the ear, nose and throat. A textbook for students of institutions of secondary vocational education, studying in the specialty 060101.51 "General Medicine" in the discipline "Diseases of the ear, throat and nose". - GEOTAR-Media. - 2016 - 315 p.
<p>The student should be able to:</p> <ol style="list-style-type: none"> 1. Conduct an external examination and palpation of the cartilage of the larynx, regional lymph nodes. 2. Perform indirect laryngoscopy (hypopharyngoscopy) and characterize the norms for this type of research. 3. Perform esophagostomy, tracheobronchoscopy. 	<p>References:</p> <ol style="list-style-type: none"> 1) Luchikhin L.A. Otorhinolaryngology. Textbook. – Approved by of the Ministry of Education of the Russian Federation. - GEOTAR- Media. - 2016 - 584 p. 2) Luchikhin L.A. Examination of an otorhinolaryngological patient. - GEOTAR-Media. - 2014 - 256 p. 3) Palchun V.T. Diseases of the ear, nose and throat. A textbook for students of institutions of secondary vocational education, studying in the specialty

	060101.51 "General Medicine" in the discipline "Diseases of the ear, throat and nose". - GEOTAR-Media. - 2016 - 315 p.
--	--

Assignment for independent work .

1. The cartilages of the larynx: single _____
paired _____
 2. The pterygoid joint is formed _____ and provides _____ the vocal folds
 3. The paracranial joint is formed _____ and provides _____ the vocal folds.
 4. Ligaments of the larynx. 1. _____
2. _____
3. _____
4. _____
5. _____
6. _____
7. _____
8. _____
 5. External muscles: I group 1 _____
2 _____
II group 1 _____
2 _____
3 _____
4 _____
5 _____
 6. The upper laryngeal artery is a branch of the _____, which branches off from the _____
 7. The inferior laryngeal artery is a branch of the _____, which branches off from _____.
 8. The upper laryngeal nerve is a branch from the vagus nerve in the area of _____
 9. The inferior laryngeal nerves are extensions of the _____
 10. How are the right and left recurrent nerves located relative to the trachea and esophagus? right _____ and left _____
-

11. The multilayer squamous epithelium is present in the following formations of the larynx _____
12. The trachea is bordered at the back by _____, to the right of it is _____, to the left of it is _____
13. The esophagus has three parts _____, the length of the cervical part is _____, the thoracic part is _____ the abdominal part is _____
14. The wall of esophagus has the following layers _____
15. The first constriction of the esophagus is _____
16. The second constriction is formed by _____
17. The third constriction _____
18. Basic functions of the larynx _____
19. Upper resonator is formed _____
20. Lower resonator is formed _____
21. The characteristics of sound include _____
22. Voice change, or mutation, occurs between the age of _____, In boys the voice changes from _____ to _____, and in girls from _____ to _____

Tests.

1. THE INTERNAL MUSCLES OF THE LARYNX ARE DIVIDED INTO GROUPS

- 1) narrowing the glottis, widening the glottis, tightening the glottis
- 2) tightening vocal folds, narrowing vocal slit
- 3) widening and narrowing vocal folds
- 4) tightening, widening the vocal folds, raising the larynx

2. ESOPHAGUS HAS ANATOMICAL CONSTRICTIONS

- 1) one
- 2) two
- 3) three
- 4) four

3. THE CONICAL LIGAMENT IS LOCATED BETWEEN

- 1) thyroid cartilage and hyoid bone
- 2) reticular cartilage and trachea
- 3) thyroid cartilage and rhizoid cartilage
- 4) thyroid cartilage and epiglottis

4. THE MAIN FUNCTIONS OF THE LARYNX ARE

- 1) respiratory, vocal-forming, protective
- 2) voice-forming, reflexive
- 3) reflexive, protective
- 4) respiratory, vocal-forming

5. INTERNAL BRANCHES OF THE UPPER LARYNGEAL NERVES ENTER THE LARYNX THROUGH

- 1) thyroperitoneal ligament
- 2) hyoid membrane
- 3) thyroid cartilage
- 4) metacarpal cartilage

6. TENSION OF VOCAL FOLDS IS CHANGED BY MUSCLE

- 1) posterior parascapularis muscle
- 2) lateral parotid scapular muscle
- 3) thyrotocherpulopaloid muscle
- 4) pterygoid

7. THE GAP BETWEEN THE THYROID AND METATARSAL CARTILAGES IS CLOSED BY

- 1) thyropharyngeal membrane
- 2) ligament of the thyrohypopharynx
- 3) conic ligament

8. ORIGIN OF ESOPHAGUS CORRESPONDS TO PROJECTION

- 1) hyoid bone
- 2) superior edge of thyroid cartilage
- 3) lower edge of thyroid cartilage
- 4) lower edge of the metatarsal cartilage

9. TRACHEAL BIFURCATION IS LOCATED AT THE LEVEL OF THE THORACIC VERTEBRAE

- 1) T11-T12
- 2) T12-T13
- 3) T13-T14
- 4) T14-T15

10. IN CHILDREN THE LOOSE SUBMUCOSAL LAYER IS DEVELOPED IN THE LARYNGEAL FLOOR

- 1) upper
- 2) middle
- 3) lower
- 4) upper and middle

11. THE INTERNAL MUSCLE OF THE LARYNX

- 1) hypopharyngeal
- 2) stylopharyngeal

3) thyropharyngeal

4) sternocleidomastoid

12. UPPER LARYNGEAL ARTERY IS A BRANCH OF

1) internal carotid artery

2) superior thyroid artery

3) subclavian artery

4) thyrocervical trunk

13. LOWER LARYNGEAL ARTERY IS A BRANCH OF THE ARTERY

1) internal carotid

2) external carotid

3) inferior thyroid

4) subclavian

14. LARYNX INNERVATION IS CARRIED OUT BY THE NERVE

1) trigeminal

2) lingual-pharyngeal

3) vagus

4) hyoid

15. THE BORDERS OF THE ESOPHAGUS CORRESPOND TO THE VERTEBRAE

1) CV-TIX

2) CVI-TXI

3) TI-TX

4) TII-TVIII

Keys

№	Answer	№	Answer
1	1	10	3
2	3	11	3
3	3	12	2
4	1	13	3
5	2	14	3
6	4	15	2
7	3		
8	4		
9	2		

Lesson 6

Topic: Acute diseases of the outer, middle ear.

Examination questions:

1. Give a definition for a furuncle of the external auditory canal, spilled inflammation of the skin of the external auditory canal.
2. What stages does acute purulent inflammation of the middle ear go through in its development?
3. What are the features of acute otitis media in childhood and with infectious diseases?
4. What types of fungi cause otomycosis?
5. What are the stages in the development of mastoiditis?
6. How are foreign bodies of the ear classified?

Objectives:

<p>The student should know:</p> <ol style="list-style-type: none">1. Basic clinical symptoms of external and middle ear, their complications, peculiarities of acute purulent otitis media with infectious diseases in childhood, principles of conservative treatment, indications for paracentesis2. Clinical manifestations, diagnosis, basic principles of treatment of mastoiditis.3. Classification of varieties of congenital ear anomalies and ear foreign bodies.	<p>References:</p> <ol style="list-style-type: none">1. Ovchinnikov Yu.M., Gamov V.P. Diseases of the nose, throat and ear. - M.: Medicine. - 2003 - 320 p.2. Palchun V.T. Diseases of the ear, throat and nose. Textbook for Students of Secondary Vocational Education, studying on the specialty 060101.51 "Medical Business" in the discipline "Diseases of the Ear, Throat and Nose. - GEOTAR-Media. - 2016 - 315 p.3. Palchun V. T., Magamedov MM, Luchikhin LA Otorhinolaryngology textbook. - Moscow ed. GEOTAR-Media. - 2011. - 656 p.
<p>The student should be able to:</p> <ol style="list-style-type: none">1. Identify forms of otitis externa (furuncle, spilled inflammation)2. Identify the causative agent of otomycosis in the discharge from the ear canal.3. Correctly perform irrigation of the wax plug, using a Janet syringe.4. Determine the stages of acute suppurative otitis media during otoscopy according to changes in the tympanic membrane.	<p>References:</p> <ol style="list-style-type: none">1) Luchikhin L.A. Diseases of the upper respiratory tract and ear. Handbook of the practicing physician. - GEOTAR-Media. - 2016 - 256 p.2) Luchikhin L.A. Otorhinolaryngology. Textbook. - Grif MO RF. - GEOTAR Media. -

<p>5. Perform paracentesis of the tympanic membrane.</p> <p>6. Evaluate the findings of Schuller, Meyer stacked radiographs.</p>	<p>2016 - 584 p.</p> <p>3) Ovchinnikov Y.M., Gamov V.P. Diseases of the nose, throat and ear. - M.: Medicine. - 2003 - 320 p.</p> <p>4) Otorhinolaryngology National Manual / Ed. by V.T.Palchun, Corresponding member of Russian Academy of Medical Sciences. - Moscow, GEOTAR-Media. - 2013. - 954 p.</p> <p>5) Palchun V.T. Diseases of the ear, throat and nose. Textbook for students of secondary vocational education, studying in the specialty 060101.51 "Medical Business" in the discipline "Diseases of the ear, throat and nose. - GEOTAR-Media. - 2016. - 315 p.</p>
--	--

Assignment for independent work.

1. A furuncle of the external auditory canal is _____
2. Spilt inflammation of the skin of the external auditory canal affects its sections _____.
3. To diagnose otomycosis the following methods of examination are used _____
4. A contraindication for earwax washing is _____
5. Stages of acute purulent otitis media are _____
6. Gradinigo triad _____
7. The indication for an anthrotomy is _____

Tests

1. EXTERNAL DIFFUSE OTITIS MEDIA IN ADULTS IS CHARACTERIZED BY

- 1) pain when pressing on the condyle
- 2) pain when percussing the mastoid process
- 3) dizziness

4) nystagmus

2. FURUNCLES IN THE EXTERNAL AUDITORY CANAL ARE CAUSED BY

1) trauma to the skin of the external auditory canal

2) mastoiditis

3) catarrhal otitis media

4) temporomandibular joint dysfunction

3. IN OTOMYCTUS CAUSED BY FUNGUS ASPERGILLUS NIGER THE COLOR OF THE DISCHARGE WILL BE

1) black-brown

2) yellowish

3) greenish

4) white-gray

4. THE MAIN SYMPTOM OF AN OCCLUSION OF THE EAR CANAL WITH A WAX PLUG

1) sharp pain in the ear

2) nystagmus

3) hyperacusis

4) unilateral deafness

5. TO REMOVE WAX PLUGS THE WATER TEMPERATURE SHOULD BE

1) 27° C

2) 30° C

3) 37° C

4) 42° C

6. WHEN REMOVING THE WAX PLUG FROM THE EAR THE WATER JET FROM THE SYRINGE IS DIRECTED ALONG THE WALLS OF

1) lower posterior

2) upper posterior

3) anterolateral

4) antero-posterior

7. IN ORDER TO SOFTEN A WAX PLUG IN THE EAR THE FOLLOWING IS PLACED

1) distilled water

2) 3% boric alcohol solution

3) sodoglycerine drops

4) hydrocortisone suspension

8. PATIENTS WITH ACUTE OTITIS MEDIA HAVE HEARING LOSS

- 1) perceptive
- 2) mixed
- 3) conductive

9. PARACENTESIS OF THE TYMPANIC MEMBRANE IS PERFORMED IN THE QUADRANT

- 1) anterior-upper
- 2) anterior-lower
- 3) posterior-upper
- 4) posterior-lower

10. MOST COMMON WAY OF PENETRATION OF INFECTION INTO THE MIDDLE EAR

- 1) through auditory tube
- 2) through external ear canal in case of tympanic membrane trauma
- 3) hematogenous route
- 4) lymphogenic way

11. NARROWING OF EXTERNAL AUDITORY CANAL IS SEEN IN

- 1) otosclerosis
- 2) chronic middle otitis media
- 3) acute otitis media
- 4) otitis externa

12. ACUTE PURULENT MIDDLE OTITIS MEDIA COMPLICATED BY MASTOIDITIS IS ACCOMPANIED BY

- 1) paracentesis of tympanic membrane
- 2) anthrotomy
- 3) atticotomy
- 4) anthromastoidotomy

13. HEARING LOSS IS NOTED IN THE PRESENCE OF A WAX PLUG IN THE EXTERNAL AUDITORY CANAL

- 1) perceptive
- 2) mixed
- 3) conductive

14. DIAGNOSTIC SIGN OF ACUTE OTITIS MEDIA

- 1) hyperemia of tympanic membrane
- 2) scarring of tympanic membrane

- 3) shortening of malleolus handle and light cone
- 4) granulation in the lumen of the external auditory canal

Keys :

№	Answer	№	Answer
1	1	8	3
2	1	9	4
3	1	10	1
4	4	11	4
5	3	12	4
6	2	13	3
7	3	14	1

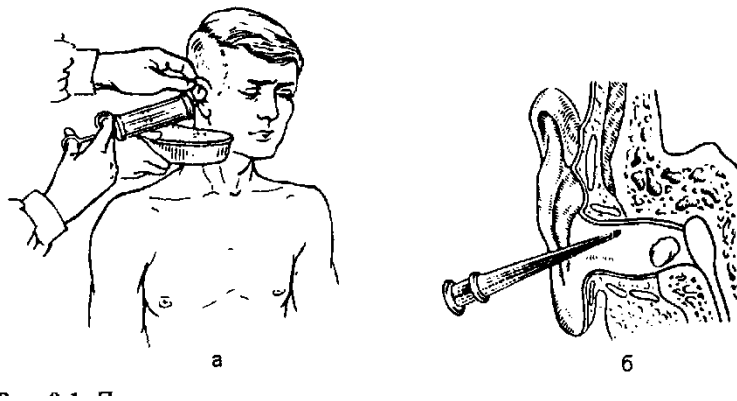


Fig.26. Which manipulation is performed in the figure, with which instrument, for which disease? What is the direction of the water jet and why? Specify contraindications for this examination.

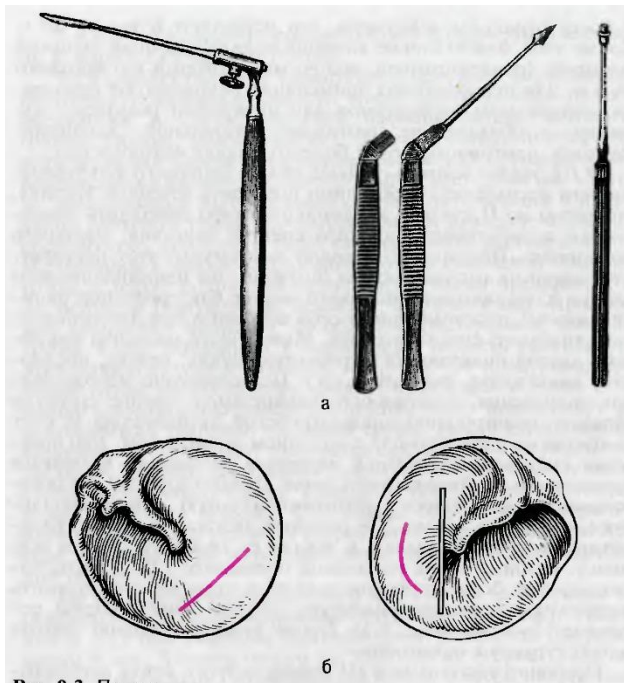


Fig. 27. What is the name of the instrument, for which disease is it used, in which quadrant of the eardrum is the incision made.

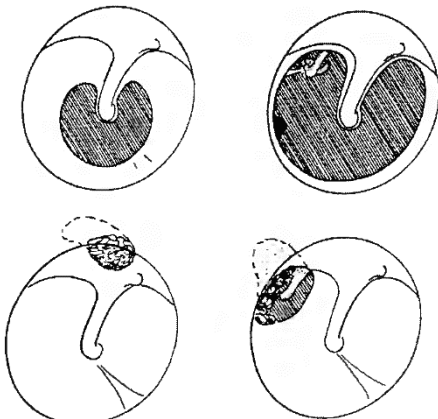


Fig. 28. What types of eardrum perforations are shown in the picture?

Lesson 7

Topic: Chronic ear diseases. Otogenic intracranial complications

Examination Questions

1. How is chronic middle ear inflammation classified and how does it proceed?
2. Name benign and malignant tumors of the ear, ear injuries.
3. Etiology, pathogenesis, clinic, diagnosis, differential diagnosis, basic principles of treatment of acute and chronic tubotitis, sensorineural hearing loss, otosclerosis, Meniere's disease.
4. Labyrinthitis, its characteristic, clinic, diagnosis, principles of therapy.
5. Name the causative agent of meningitis, as well as ear diseases that can lead to meningitis, routes of infection
6. Give the definition, etiology, pathogenesis, what clinical manifestations occur in brain

abscess, cerebellar, sinustrombosis and otogenic sepsis.

Objectives

<p><u>The student should know:</u></p> <ol style="list-style-type: none">1. Forms, course, clinical manifestations of chronic otitis media, as well as complications caused by these forms.2. Etiology, pathogenetic aspects, clinical picture, diagnosis, principles of treatment of acute and chronic catarrh of the middle ear, sensorineural hearing loss, otosclerosis, Meniere's disease3. Classification of ear tumors, trauma, diagnosis, therapy of these diseases.4. Forms, pathomorphology, classification of labyrinthitis, ways of penetration into the inner ear.5. Etiology, pathogenesis, clinic, symptoms, diagnosis, treatment of meningitis, brain abscess, cerebellum, sinustrombosis, otogenic sepsis.	<p><u>References</u></p> <ol style="list-style-type: none">1) Lopatin A.S., Alexandrova I.A., Varvianskaya A.V. Rational pharmacotherapy of ear, throat and nose diseases. A guide for practicing doctors.-LitTerra.-2013. p. 210-2282) Luchikhin L.A. Otorhinolaryngology. Textbook. – Approved by the Ministry of Education of the Russian Federation, - GEOTAR Media.-2016 - 584 p.3) Palchun V.T. Diseases of the ear, throat and nose. Textbook for students of secondary vocational education, studying in the specialty 060101.51 "Medicine" in the discipline "Diseases of the ear, throat and nose. - GEOTAR-Media. - 2016 . - 315 p.4) Palchun V.T., Magamedov M.M., Luchikhin L.A. Otorhinolaryngology textbook.2007. - 468-645 p.
<p><u>The student should be able to:</u></p> <ol style="list-style-type: none">1. Distinguish forms of meso-, epitympanitis.2. Perform otoscopy3. Perform chambertonal tests, decipher the auditory passport, give interpretation of audiograms, radiographs according to Schuller, Meyer, Stenvers.4. Determine spontaneous labyrinth nystagmus, fistulous symptom.5. Perform Vodak-Fisher, finger-nose, finger-finger tests.6. Identify Kernig's, Brudzinski's (upper, lower), Bechterew's symptoms.7. Carry out a spinal puncture.	<p><u>Refernces:</u></p> <ol style="list-style-type: none">1) Lopatin A.S., Aleksandrova I.A., Varvianskaya A.V. Rational pharmacotherapy diseases of the ear, throat and nose. Guidelines for practicing physicians.-LitTerra.-2013. p. 210-2282) Luchikhin L.A. Otorhinolaryngology. Textbook. – Approved by the Ministry of Education of the Russian Federation, - GEOTAR Media.-2016 - 584 p.3) Palchun V.T. Diseases of the ear, throat and nose. Textbook for students of secondary vocational education, studying in the specialty 060101.51 "Medicine" in the discipline "Diseases

	of the ear, throat and nose. - GEOTAR-Media. - 2016 . - 315 p. 4)Palchun V.T., Magamedov M.M., Luchikhin L.A. Otorhinolaryngology textbook.2007. - 468-645 p
--	--

Questions for independent work

1. Name the main forms of chronic inflammation of the middle ear _____

2. Give the definition and classification of ear tumors, ear injuries _____

3. State the stages, degrees, course of sensorineural hearing loss, otosclerosis, Meniere's disease _____

4. In which part of the tympanic membrane is the perforation located during ?
mesotympanitis _____
epitympanitis _____
5. Tumor-like growths in the ear are _____

6. Benign ear tumors include _____

7. Otoscopy in tubo-otitis is characterized by the following changes to the eardrum

8. For practical purposes, sensorineural hearing loss is divided into _____

9. The following degrees of hearing loss are defined according to the levels of thresholds for perceiving speech frequencies _____
10. Meniere's disease is characterized by the classic triad _____

11. The various surgical treatments for Meniere's disease are divided into the following groups
12. The following forms of otosclerosis are distinguished according to the nature of the lesion of the auditory and sound-conducting apparatus _____

-
-
13. The following types of surgery for otosclerosis are known _____
-
14. An indication for hearing aids is _____
15. Depending on the nature of the pathogenic process, the following forms of labyrinthitis are distinguished
by spread level _____
by pathomorphological signs _____
16. Noise in the ear in labyrinthitis _____,
is amplified by _____
- 17 Differential diagnosis of labyrinthitis is made with the following diseases _____
-
18. Meningeal (otogenic) symptoms include _____
-
19. Indication for lumbar puncture is _____
20. Otogenic meningitis is differentiated from _____
21. Griesinger's symptom is _____,
it appears with sigmoid sinus thrombosis.
22. Whiting's symptom is - _____.

Tests

1. TREATMENT OF PATIENTS WITH CHRONIC EXUDATIVE OTITIS MEDIA INCLUDES

- 1) general ear surgery
- 2) mastoidotomy
- 3) myringotomy
- 4) stapedectomy

2. GENERAL BAND EAR SURGERY IS INDICATED FOR

- 1) adhesive otitis media
- 2) otosclerosis
- 3) exudative otitis media
- 4) chronic purulent-destructive epithympanitis

3. CHARACTERISTIC OTOSCOPIC SIGN OF CHRONIC PURULENT OTITIS MEDIA IS

- 1) scars on the tympanic membrane
- 2) lime deposit on the tympanic membrane
- 3) perforation of the eardrum
- 4) dull color of eardrum

4. OTOSCLEROSIS IS MORE COMMON IN

- 1) girls
- 2) boys
- 3) men
- 4) women

5. THE PATHOGENESIS OF OTOSCLEROSIS IS BASED ON

- 1) osteodystrophic process
- 2) decrease of intralabyrinthine pressure
- 3) increase in intralabyrinthine pressure and edema (hydrops) of the labyrinth
- 4) scarring process in tympanic cavity.

6. OTOSCOPIC SIGN OF OTOSCLEROSIS IS

- 1) thickening of the tympanic membrane
- 2) normal appearance or thinning of the tympanic membrane
- 3) perforation of tympanic membrane in stretched part
- 4) Scars and petrificates on tympanic membrane

7. SURGICAL TREATMENT OF PATIENTS WITH OTOSCLEROSIS IS

- 1) tympanoplasty
- 2) anthromastoidotomy
- 3) stapedoplasty
- 4) aticoanthrotomy

8. IN OTOSCLEROSIS THE PRIMARY OTOSCLEROTIC FOCUS IS LOCALIZED IN THE AREA OF

- 1) oval window
- 2) round window
- 3) tympanic membrane
- 4) tympanic orifice of ear canal

9. TIMPANEL FORM OF OTOSCLEROSIS THICKNESSES

- 1) perceptual
- 2) mixed

3) conductive

4) scalar

10. IN A PATIENT WITH A LESION OF THE SOUND-ACCEPTING PART OF THE SOUND ANALYZER IN THE RIGHT EAR THE SOUND IN THE WEBER EXPERIMENT WILL BE DIRECTED

1) to the right

2) to the left

3) to both sides

4) in the center of the head

11. WHEN PERFORMING THRESHOLD TONAL AUDIOMETRY IN A PATIENT WITH A LESION OF THE SOUND-PRODUCING PART OF THE SOUND ANALYZER WE OBSERVE

1) decrease in airborne sound conduction

2) decrease of bone and air conduction

3) decrease of bone sound conduction

4) islets of sound

12. PETROSITIS IS CHARACTERIZED BY

1) paresis or paralysis of facial nerve

2) trigeminitis

3) bilateral hearing loss

4) pain during chewing

13. PERMANENT SYMPTOM OF CHRONIC OTITIS MEDIA

1) increase in body temperature

2) ear pain

3) perforation of tympanic membrane

4) gait disturbance

14. PATHOGENETIC BASIS OF THE MENIERE'S DISEASE IS CONSIDERED TO BE

1) hydrops of labyrinth

2) presence of cholesteatoma in tympanic cavity

3) labyrinthitis

4) arterial hypertension

15. CHOLESTEATOMA IS CHARACTERISTIC OF

1) otosclerosis

2) adhesive otitis media

3)chronic purulent mesotympanitis

4) chronic purulent epitympanitis

16.IN EXACERBATION OF CHRONIC PURULENT MESOTYMPANITIS THERE IS

1) swelling of soft tissues in the occipital region

2) intensification of pus discharge from ear

3) nystagmus

4) neck stiffness

17.MASTOIDITIS IS A COMPLICATION OF

1) acute purulent otitis media

2) chronic mesotympanitis

3) tubootitis

4) adhesive otitis media

18.SIGN OF EPITYMPANITIS IS

1) perforation in the non-tensioned part of tympanic membrane

2) perforation in the stretched part of the tympanic membrane

3) intact eardrum

4) central perforation

19.MEDICATION USED DURING AN ATTACK IN MENIERE'S DISEASE

1) 2.4% eufillin solution 10 ml into a vein

2) 0.1% solution of atropine sulfate 1 ml under the skin

3) 50% analgin solution 2 ml into the muscle

4) 5% ascorbic acid solution 2 ml in a vein

20. TO TREAT PATIENTS WITH MENIERE'S DISEASE THE FOLLOWING SURGERIES ARE PERFORMED

1) stapedoplasty

2) stapedectomy

3) endolymphatic sac drainage

4) atromastoidotomy

Keys:

№	Answer	№	Answer
1	3	15	4
2	4	16	2
3	3	17	1

4	4	18	1
5	1	19	2
6	2	20	3
7	3		
8	1		
9	3		
10	2		
11	1		
12	2		
13	3		
14	1		

1. THE MOST FREQUENT WAY OF SPREADING INFECTION INTO THE CRANIAL CAVITY FROM THE MIDDLE AND INNER EAR IS

- 1) contact
- 2) lymphogenic
- 3) hematogenous
- 4) 4. labyrinthine

2. IN CHRONIC PURULENT MIDDLE OTITIS COMPLICATED BY MENINGITIS A SURGERY IS

- 1) extended radical ear surgery
- 2) mastoidotomy
- 3) endoaural atticotomy
- 4) anthromastoidotomy

3. TO DIAGNOSE CHRONIC PURULENT MEDIA OTITIS COMPLICATED BY MENINGITIS, THE FOLLOWING SURGERIES ARE PERFORMED

- 1) otoscopy, otoneurological examination
- 2) otoscopy, cranial CT scan, blood analysis
- 3) otoscopy, cranial X-ray, spinal tap, otoneurological examination
- 4) otoscopy, blood test, medical history

4. SYMPTOM OF OTOGENIC PURULENT MENINGITIS IS

- 1) ptosis
- 2) diplopia
- 3) nystagmus
- 4) positive symptoms of Kernig, Brudzinski, stiffness of occipital muscles

5. OTOGENIC INTRACRANIAL COMPLICATIONS INCLUDE

- 1) petrositis
- 2) sinus thrombosis
- 3) zygomatica
- 4) Bezold's mastoiditis

6. SYMPTOM CHARACTERISTIC OF OTOGENIC CEREBELLAR ABSCESS IS

- 1) adiadochokinesis
- 2) hyperacusis
- 3) amnesic aphasia
- 4) posture of the patient in "doggy-legged" posture

7. ACUTE PURULENT MIDDLE OTITIS MEDIA COMPLICATED BY MASTOIDITIS AND SUBPERIOSTEAL ABSCESSES IS CHARACTERISED BY

- 1) paracentesis of tympanic membrane
- 2) anthromastoidotomy
- 3) atticotomy
- 4) anthrotomy

8. SYMPTOM OF FORCED POSITION OF THE HEAD IS CHARACTERISTIC FOR THE DISEASE

- 1) subdural abscess
- 2) sinus thrombosis
- 3) otogenic abscess of cerebellum
- 4) extradural abscess

9. FEVER IN SINUS THROMBOSIS

- 1) febrile
- 2) normal
- 3) subfebrile
- 4) hectic

10. A SUBDURAL ABSCESS IS AN ACCUMULATION OF PUS

- 1) between dura mater and bone
- 2) deep in the brain substance

3) between dura mater and spider dura mater

4) in cerebellum

11. IN OTOGENIC INTRACRANIAL COMPLICATIONS THE FOLLOWING SURGERIES ARE PERFORMED

1) extended radical ear surgery

2) atticotomy

3) tympanoplasty

4) anthrotomy

12. BRADYCARDIA IS NOTED IN DISEASES OF

1) cerebral abscess

2) sinus thrombosis

3) otogenic meningitis

4) otogenic sepsis

13. TREATMENT TACTICS OF PATIENTS WITH SUBDURAL ABSCESS IS

1) mastoidotomy

2) antibacterial, symptomatic, detoxification therapy

3) extended radical ear surgery

4) extended radical ear surgery with obligatory abscess opening, antibacterial, symptomatic and detoxication therapy

14. HEADACHE IN CEREBELLAR ABSCESS IS MOST FREQUENTLY LOCATED IN

1) frontal area

2) occipital area with possible irradiation along posterior surface of neck

3) parietal region

4) temporal region

15. IN CASE OF ABSCESS OF LEFT TEMPORAL LOBE IN RIGHT-HANDED PEOPLE THE MOST FREQUENTLY REVEALED SYMPTOM IS

1) agraphia

2) alexia

3) amnesic aphasia

4) motor aphasia

16. ADIADOCHOKINESIS IS A SPECIFIC SYMPTOM OF LESION IN

1) temporal lobe of the brain

2) cerebellum

3) frontal lobe

4) labyrinth

17. AMNESTIC APHASIA IS OBSERVED IN

1) frontal lobe abscess

2) cerebellar abscess

3) meningitis

4) abscess in temporal lobe of brain

18. SPINAL TAP IS DONE IN THE SPINAL REGION

1) cervical

2) thoracic

3) lumbar

19. THERE ARE FOLLOWING STAGES IN THE CLINICAL PICTURE OF OTOGENIC CEREBRAL ABSCESS

1) one

2) two

3) three

4) four

20. HEMIANOPSIA IS OBSERVED IN

1) abscess in frontal lobe of brain

2) abscess in temporal lobe of brain

3) cerebellar abscess

4) leptomeningitis

No	Answer	No	Answer
1	1	11	1
2	1	12	1
3	3	13	4
4	4	14	2
5	2	15	3
6	1	16	2
7	2	17	4
8	3	18	3
9	4	19	4
10	3	20	2

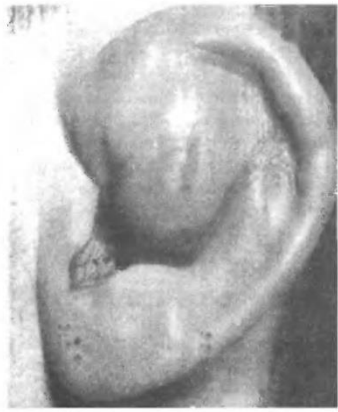

Fig.29. Which external ear disease can you see in the picture?

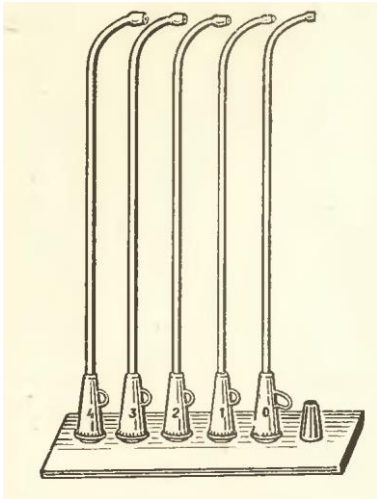


Fig.30. What are the names of the instruments and what are they used for?

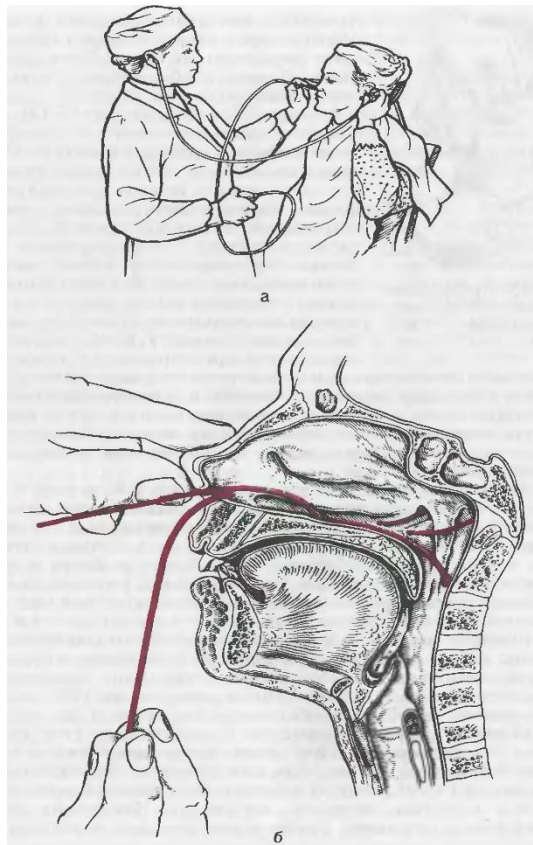


Fig. 13. What is the name of the method and what instrument is it performed with?

Facial nerve
Tympanic cavity

Cerebral membrane
Internal acoustic meatus
Labyrinth

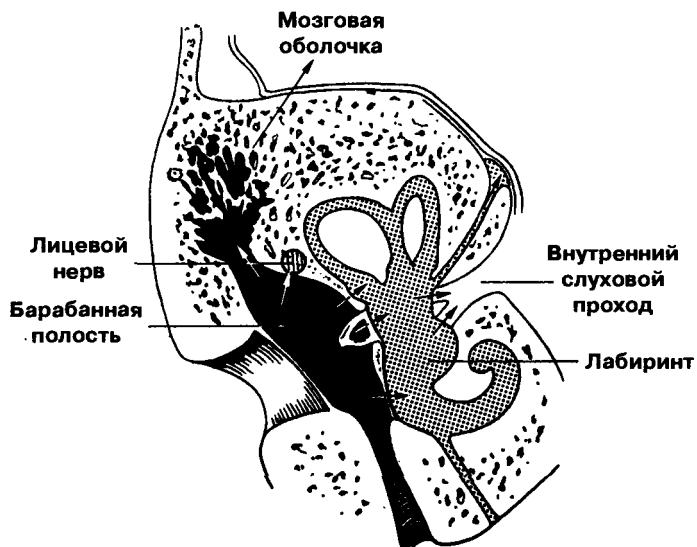


Fig.31. Name 5 main ways of infection spread during otitis media

Lesson 8

Topic: Diseases of the nose and paranasal sinuses.

Review questions:

1. Define how a deviated nasal septum, nasal furuncle are clinically manifested
2. How are acute and chronic rhinitis, acute and chronic sinusitis classified, how do they occur
3. Rhinogenic complications: what diseases of the sinuses lead to them, clinic, diagnosis, treatment
4. Causes, measures to stop nasal bleeding
5. Tumors of the nose and sinuses, trauma, fractures of the nasal bones, foreign bodies - classification, clinical manifestations, diagnosis, treatment
6. Hematoma and abscess of nasal septum

Objectives

<p><u>The student should know:</u> Basic clinical symptoms of diseases of the nose and paranasal sinuses, their complications, principles of conservative treatment and indications, as well as contraindications to surgical intervention</p>	<p><u>References:</u> 1) Palchun V.T., Magamedov M.M., Luchikhin L.A. Otorhinolaryngology textbook.-2007.- 468-645 p. 2)Piskunov G.Z., Piskunov S. Z. Clinical rhinology.-M.: IIA, 2006. - 282-407 p. 2)Lectures of the department where the student studies</p>
<p><u>The student should be able to:</u> 1.Perform anterior and posterior rhinoscopy 2. Perform pre-hospital, medical interventions to stop nasal bleeding 3.Insert medicated turundas into the nasal passages 4.Evaluate the R-grams of the paranasal sinuses in case of pathology</p>	<p><u>References:</u> 1) Palchun V.T., Magamedov M.M., Luchikhin L.A. Otorhinolaryngology textbook.-2007.- 468-645 p. 2)Piskunov G.Z., Piskunov S. Z. Clinical rhinology.-M.: IIA, 2006. - 282-407 p.</p>

Assignments for independent work:

1. Terrible complications of a nasal furuncle are _____

2. According to L.B. Dain's classification chronic rhinitis are divided into
 - 1 _____
 - 2 _____
 - 3 _____
 - 4 _____
3. There are three types of nasal septal deformities _____

1. The main treatment for deviated septum is _____

2. Septal hematoma is caused by _____

3. Depending on the causes of bleeding a distinction is made between _____

4. How many degrees of bleeding are there and what is the volume of blood loss for them _____
5. The main manipulations in the pre-hospital phase of stopping nasal bleeding include _____

6. The main measures to stop nasal bleeding in the hospital are _____

7. Acute rhinitis has three stages _____

8. Acute rhinitis can lead to the following complications _____

9. What is the name of the test to distinguish catarrhal rhinitis from hypertrophic rhinitis and how is it performed? _____
10. The main type of treatment for chronic hypertrophic rhinitis is _____

11. What is the main localization of bleeding from the nasal cavity _____

12. In neuro-vegetative form of vasomotor rhinitis anterior rhinoscopy is characterized by _____
13. Allergic rhinitis is characterized by a triad of signs _____

14. The main causative agents of sinusitis are _____

Tests:

1) SYMPTOM IN CHRONIC POLYPOSIS ETHMOIDITIS IS

- 1) thinning of nasal mucosa
- 2) mucous nasal discharge
- 3) nasal discharge with a putrid odour
- 4) recurrent nasal bleeding

2) RHINOSCOPIC PICTURE OF ACUTE NONSPECIFIC RHINITIS IS CHARACTERIZED BY

- 1) nasal mucous membrane hyperemia
- 2) enantheas in the mucous membrane
- 3) thinning of nasal cavity mucous membrane
- 4) papillary hyperplasia of nasal mucosa

3. IN PURULENT SPHENOIDITIS NASAL DISCHARGE IS DETERMINED RHINOSCOPICALLY

- 1) average
- 2) inferior
- 3) upper
- 4) general

4. THE PRESENCE OF BLUISH AND WHITE SPOTS ON THE MUCOUS MEMBRANE OF THE NASAL SINUSES IS CHARACTERISTIC OF RHINITIS

- 1) chronic vasomotor
- 2) chronic hypertrophic
- 3) chronic atrophic
- 4) acute non-specific

5. X-RAY SIGN OF CATARRHAL MAXILLARY SINUSITIS IS

- 1) parietal darkening of maxillary sinus
- 2) non-homogeneous reduction of maxillary sinus transparency
- 3) homogeneous intensive reduction of maxillary sinus transparency
- 4) globular shadow in projection of maxillary sinus

6. NASAL FURUNCLE DEVELOPMENT IS PREDISPOSED TO

- 1) leukemia
- 2) thyrotoxicosis
- 3) diabetes mellitus

7. MAXILLARY SINUSITIS IS MORE COMMONLY

- 1) odontogenic
- 2) rhinogenic
- 3) traumatic
- 4) orbitogenic

8. RHINOGENIC MAXILLARY SINUSITIS IS DIFFERENTIATED FROM ACUTE PURULENT PERIOSTITIS OF THE UPPER JAW BY

- 1) the nature of pain sensations
- 2) the presence of changes in the alveolar process tissue
- 3) data of dental percussion
- 4) changes in the white blood cells

9. PUNCTURE OF MAXILLARY SINUS IS CARRIED OUT THROUGH

- 1) superior nasal passage
- 2) middle nasal passage
- 3) inferior nasal passage
- 4) anterior sinus wall

10. ACUTE RHINORRHEA HAS STAGES

- 1) one
- 2) two
- 3) three
- 4) four

11. SYMPTOM CHARACTERISTIC OF SEPTAL DEVIATION IS

- 1) difficulty in nasal breathing
- 2) putrid odor
- 3) rhinorrhea
- 4) anosmia

12. SYMPTOM OF OZENA IS

- 1) wide nasal passages
- 2) polyposis hyperplasia of nasal mucosa
- 3) recurrent nasal bleeding
- 4) hypertrophy of nasal cavities

13. TREATMENT METHOD OF CHRONIC HYPERTROPHIC RHINITIS IS

- 1) submucosal vasotomy
- 2) galvanocaust
- 3) submucosal conchotomy
- 4) intranasal blocks

14. ANOSMIA IS OBSERVED IN

- 1) simple atrophic rhinitis
- 2) vasomotor rhinitis
- 3) ozena
- 4) hypertrophic rhinitis

15. LEFLER'S BACILLUS IS FOUND IN

- 1) venereal disease
- 2) diphtheria
- 3) scleroma
- 4) syphilis

16. FOUL-SMELLING RHINORRHEA IS OBSERVED IN

- 1) hypertrophic rhinitis
- 2) simple trophic rhinitis
- 3) vasomotor rhinitis
- 4) ozena

17. INDICATION FOR RADICAL SURGERY ON THE MAXILLARY SINUS IS

- 1) sanation of chronic inflammation nidus

2) cyst removal

3) foreign body removal

18. TREPANOPUNCTURE IS PERFORMED IN CASE OF DISEASE

1) maxillary sinus

2) cells of the labyrinthine cortex

3) frontal sinus

4) sphenoid sinus

19. NASAL FURUNCLE LEADS TO SINUS THROMBOSIS

1) cavernous

2) sigmoid

3) transversal

4) longitudinal

20. TREPANOPUNCTURE OF FRONTAL SINUS IS MADE THROUGH THE WALL

1) inferior

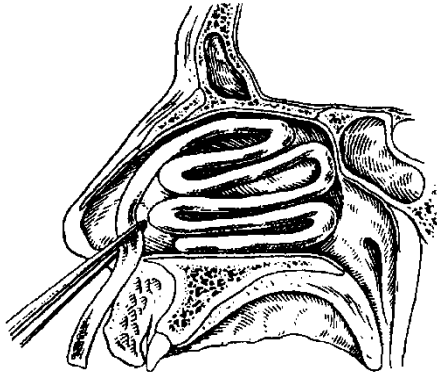
2) medial

3) anterior

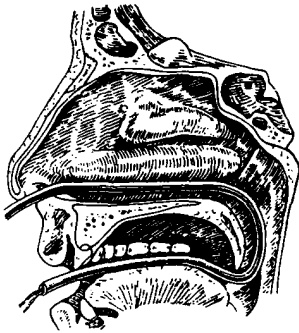
4) lateral

Keys:

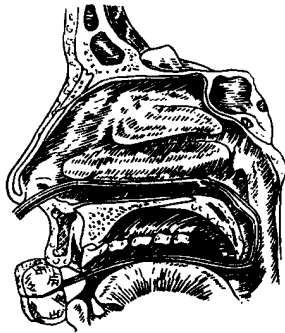
№	Answer	№	Answer
1	2	12	1
2	1	13	3
3	3	14	3
4	1	15	2
5	1	16	4
6	4	17	1
7	2	18	3
8	2	19	1
9	3	20	3
10	3		
11	1		



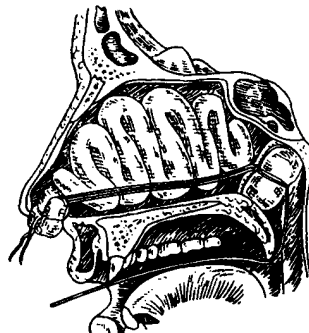
a.



a



б



в

Fig.35. b. Specify methods of stopping nasal bleeding.

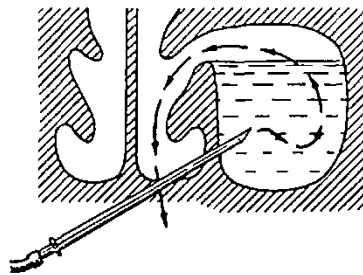
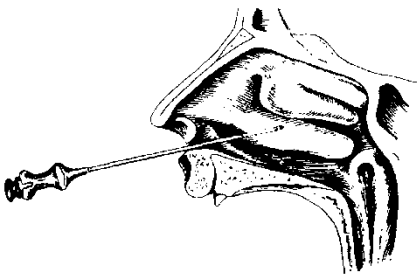


Fig.36. What is the name of the procedure and what is its technique?

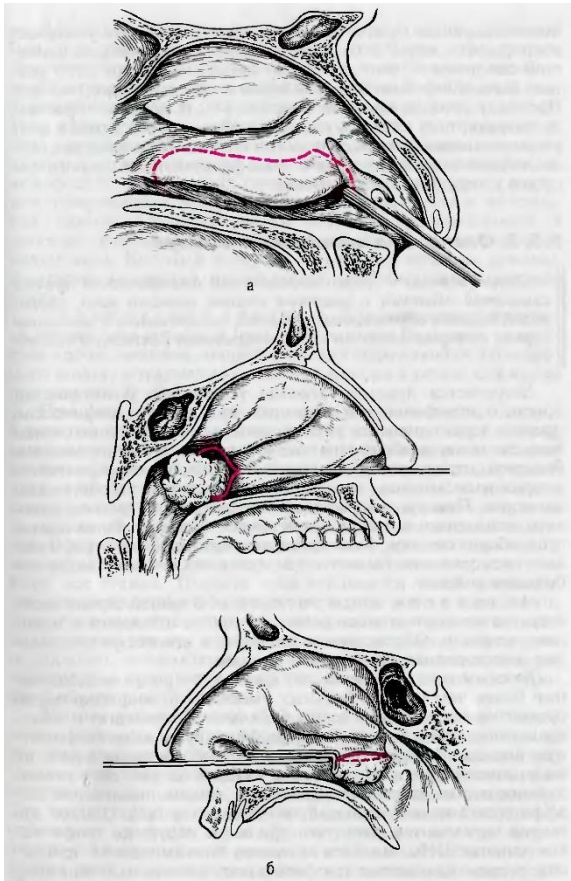


Fig.37. Specify the main methods of surgical treatment of hypertrophic rhinitis.

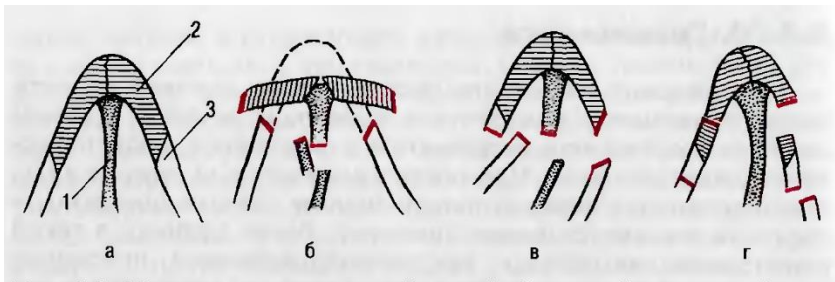


Fig.38. What nasal bone fracture patterns do you see in the picture?

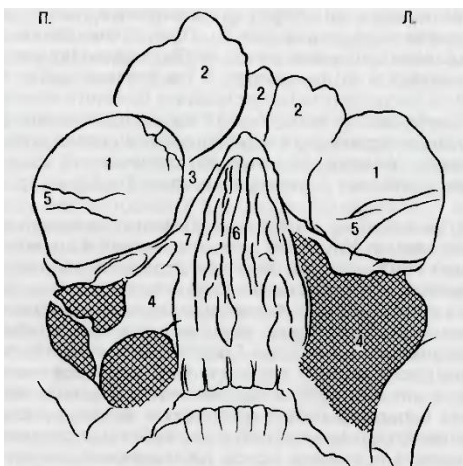


Fig.39. What diagnosis can you suggest based on the radiograph of the LP?

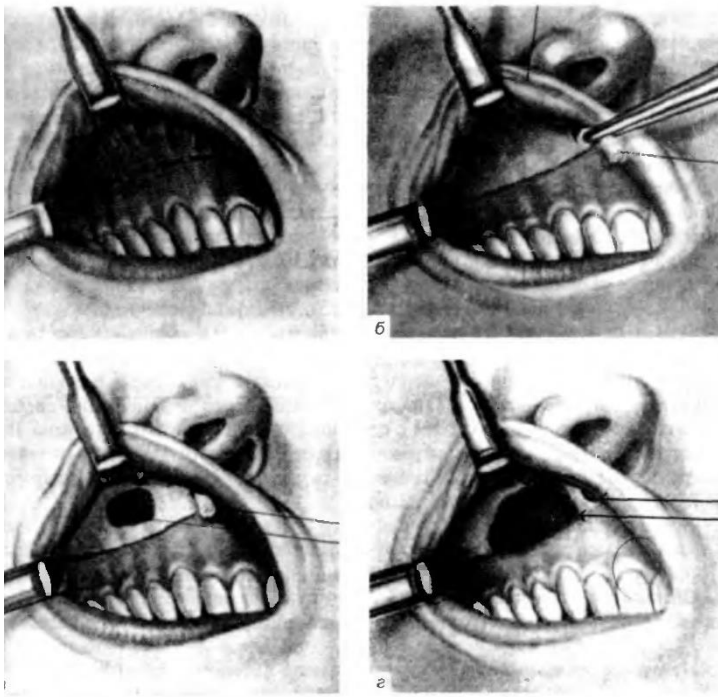


Fig. 40. What is the name of the operation and in what disease is it performed?

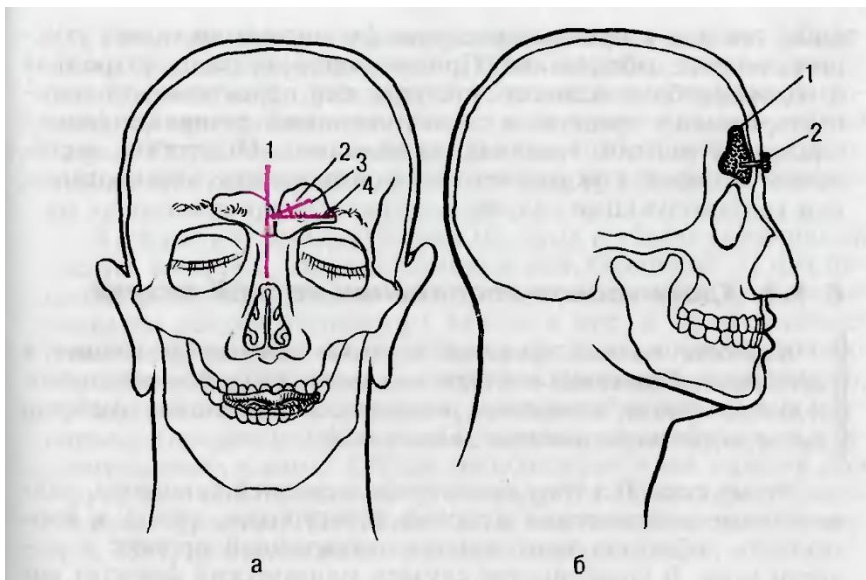


Fig.41. Name the indications and technique for performing the operation in the picture

Lesson 9

Topic: Diseases of the pharynx

Examination questions:

1. Definition, etiology, pathogenesis, clinical manifestations, diagnosis, principles of treatment of acute and chronic pharyngitis, pharyngitis and candidomycosis.
2. Tonsillitis classification of tonsillitis, pharyngeal diphtheria (pathogen, clinic, diagnosis, treatment). Paratonsillitis. Paratonsillar and glossopharyngeal abscesses.
3. Classification of tonsillitis by Soldatov, hypertrophy of the palatine and pharyngeal tonsils (adenoids). Chronic tonsillitis.
4. Classification of tumors, injuries, burns, and foreign bodies of the pharynx, pharyngeal bleeding.

Objectives.

<p><u>The student should know:</u></p> <p>1. Classification of tonsillitis, basic clinical symptoms of acute and chronic tonsillitis, its complications and related diseases, principles of conservative treatment, prevention and dispensary, clinical manifestations of pharyngocandidomycosis, paratonsillar abscess, adenoids, pharyngeal tumors.</p>	<p>References:</p> <p>1) Palchun V.T., Magamedov M.M., Luchikhin L.A. Otorhinolaryngology textbook.- 2007,-250-324p.</p> <p>2)Berbom Hans, Kaschke Oliver, Navka Tadeus. Diseases of the Ear, Throat and Nose. - MEDpress-Inform. - 2016 - 776 p.</p> <p>3)Kryukov A.I. Guide to emergency care for diseases of the ear and upper respiratory tract. - GEOTAR-Media. - 2016 - 386 p.</p>
<p><u>The student should be able to:</u></p> <p>1. Perform types of pharyngoscopy, diagnose correctly pharyngeal disease, make differential diagnosis of acute primary tonsillitis with tonsil lesions in infectious diseases and pathology of the blood system, timely identify complications, choose therapeutic tactics, perform some manipulations, namely: lubrication of the back wall of the throat with drugs, lavage of tonsil lacunae with solutions, etc.</p>	<p>References:</p> <p>1)Palchun V.T., Luchikhin L.A., Magomedov M.M.: Manual for practical otorhinolaryngology. MIA. - 2011 . - 565 p. Palchun V.T.,Luchikhin L.A., Magomedov M.M.-MIA. -2011- 344 p.</p> <p>2)Kryukov Andrey Ivanovich,: Inflammatory diseases of the pharynx. - GEOTAR-Media.- 2014.- 102-285 p.</p>

Assignment for independent work

1. The main causative agents of acute pharyngitis are _____
2. The predisposing factors of acute pharyngitis are _____
3. Tonsillitis is _____
4. Trivial forms of tonsillitis include _____
5. Atypical forms of tonsillitis include _____
6. Tonsillitis accompanying infectious diseases _____
7. Tonsillitis associated with blood diseases _____
8. Tonsillitis is treated in the _____ department
9. Plaques in diphtheria have the following signs _____
10. The following three forms of diphtheria are distinguished _____
11. According to clinical and morphological changes the following forms of paratonsillitis are distinguished _____

12. Mesopharyngoscopy in case of a pharyngeal abscess is characterized by _____

13. Chronic pharyngitis is classified as follows _____

14. Zack's sign is _____

15. Preobrazhensky's sign is _____

16. Giese's sign is _____

17. Indications for tonsillectomy are _____

18. Contraindications for tonsillectomy are _____

19. Surgery to treat hypertrophy of the palatine tonsils is called _____

20. Surgery in the treatment of adenoids is called _____

Тесты

1. CHRONIC PHARYNGITIS IS CHARACTERIZED BY

- 1) sore throat
- 2) difficulty in swallowing
- 3) scratchy throat
- 4) cough with sputum

2. CHARACTERISTIC CHANGE OF MUCOUS MEMBRANE IN CHRONIC ATROPHIC PHARYNGITIS

- 1) bright hyperemia
- 2) dryness
- 3) edema
- 4) vascular injection

3. TONSIL PLAQUE SPREADS BEYOND TONSIL SURFACE IN CASE OF

- 1) pharyngeal diphtheria
- 2) lacunar tonsillitis
- 3) ulcerative necrotic tonsillitis
- 4) catarrhal tonsillitis

4. THE CAUSE OF DISORDER OF THE SOFT PALATE MOBILITY IN PHARYNGEAL DIPHTHERIA

- 1) swelling of pharyngeal soft tissues
- 2) toxic paresis of the palatine muscles
- 3) paresis of pharyngeal nerve tongue

5. OPEN PHARYNGEAL RHINOLALIA OCCURS WITH

- 1) cleft palate
- 2) pharyngeal abscess
- 3) chronic tonsillitis
- 4) laryngitis

6. THE CAUSATIVE AGENTS OF SIMANOVSKY - PLAUTE - VENSENZA TONSILLITIS ARE

- 1) yeast-like fungi and streptococci
- 2) fusiform stick and spirochete of the oral cavity
- 3) pale treponema and Escherichia coli
- 4) Escherichia coli and Staphylococcus aureus

7 CAUSE OF PARATONSILLITIS

- 1) chronic pharyngitis
- 2) acute pharyngitis
- 3) tonsillitis
- 4) adenoiditis

8. CONE-SHAPED YELLOWISH-WHITE MASSES ON PALATINE TONSILS AND TONGUE ARE A SIGN OF

- 1) follicular tonsillitis
- 2) lacunar tonsillitis
- 3) pharyngomycosis
- 4) catarrhal tonsillitis

9. PINK GRANULES ON THE BACK WALL OF THE THROAT ARE OBSERVED AT

- 1) catarrhal pharyngitis
- 2) subatrophic pharyngitis
- 3) atrophic pharyngitis
- 4) granular pharyngitis

10. REMOVAL OF PHARYNGEAL TONSILS IS CALLED

- 1) adenotomy
- 2) tonsillectomy
- 3) tonsillotomy

Keys:

№	Answer	№	Answer
11	3	19	3
12	3	20	2
13	3		
14	4		
15	1		
16	2		
17	2		
18	2		

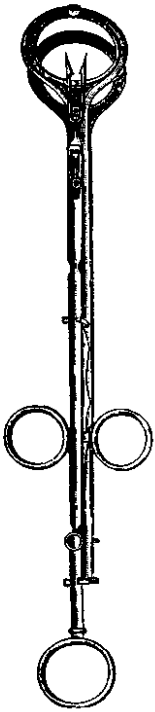


Fig.42. What is the name of the instrument, what surgery and diseases is it used for?

Признак	Дифтерия глотки	Ангины
Налеты	<p>Расположены на поверхности миндалин</p> <p>Распространяются за пределы миндалин</p> <p>Снимаются с трудом, оставляя кровоточащую поверхность</p>	<p>Расположены в глубине лакун</p> <p>Находятся в пределах свободной поверхности миндалин (за исключением скарлатинозной и язвенно-пленчатой ангины, при которых они могут выходить за пределы миндалин)</p> <p>Поверхностные и легко снимаются</p>
Гиперемия и болезненность при глотании	Большой частью незначительные	Выражены
Температура тела	<p>Субфебрильная или быстро снижающаяся</p> <p>Сравнительно низкая</p>	Держится, особенно первые 2 дня, около 39–40 °С
Пульс	Сначала замедлен, затем учащен, поверхностный и аритмичный	Соответствует температуре тела
Общее состояние	Тяжелое, прогрессивно ухудшающееся (особенно при токсической форме)	Обычно не очень тяжелое
Состояние регионарных шейных лимфатических узлов	Болезненность и припухлость. При токсической дифтерии отечность подкожной клетчатки шеи	Болезненность и припухлость
Бактериологическое исследование налетов	Коринебактерия дифтерии	В редких случаях может быть носительство коринебактерии (дифференциальная диагностика в таких случаях должна основываться на тщательном клиническом наблюдении, эффекте сывороточной терапии и учете эпидемиологических данных)

Symptom	Pharynx diphtheria	Tonsillitis
Plaques	<p>Located on the surface of the tonsils</p> <p>Spread beyond the tonsils</p> <p>Is difficult to remove, leaving a bleeding surface</p>	<p>Located inside the tonsils</p> <p>Are within the free surface of the tonsils(except for scarlatinal and necrotic tonsillitis when they can stretch beyond the tonsils)</p> <p>Are easily removed</p>

Hyperemia and pain when swallowing	Insignificant	Significant
Fever	Subfebrile or quickly going down, relatively low	About 39-40 C for the first two days
Heart rate	First slow, then rapid, shallow and irregular	Corresponds with the body temperature
General condition	Critical, progressively aggravating (especially with the toxic form)	Generally not very serious
Condition of regional cervical lymph nodes	Sore and swollen. With toxic diphtheria the subcutaneous tissue of the neck is swollen	Sore and swollen
Bacteriological examination of plaque	Corynebacterium of diphtheria	In rare cases can carry corynebacterium (differentials should be based on careful clinical observation, serum therapy effect and record of epidemiological data)

Fig 43. Table.

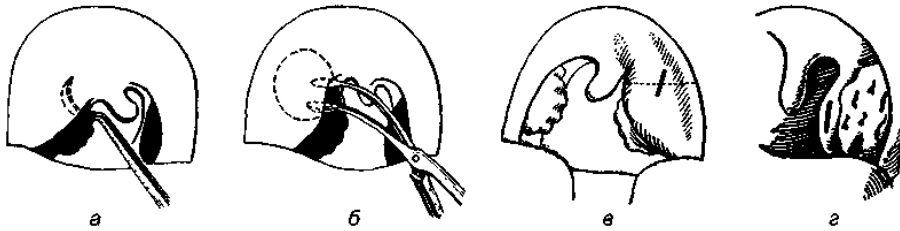


Fig.44. In what disease is this pharyngoscopic picture observed?

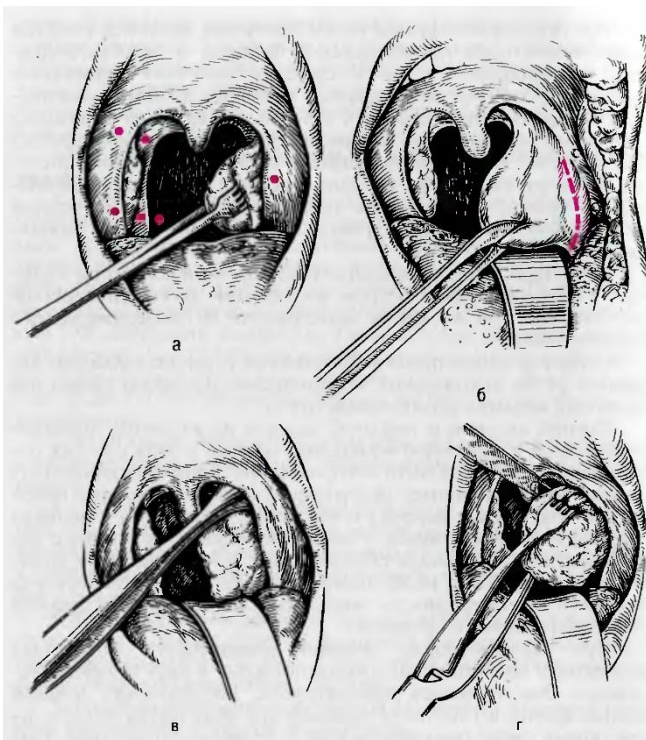


Fig.45. Name the surgery, indications and contraindications for this method of treatment.

Lesson 10

Topic: Diseases of the larynx.

Questions to check:

1. Acute and chronic laryngitis: etiology, clinical picture, treatment.
2. Acute laryngotracheitis in children, classification, clinical picture, treatment. Laryngeal edema and diphtheria.
3. Acute stenosis of the larynx, causes, classification, clinic, emergency care.

Objectives

<p><u>The student should know:</u></p> <p><u>1. The main clinical symptoms of laryngeal diseases, features of the course of laryngeal stenosis in childhood, principles of conservative treatment, indications for intubation and tracheostomy, types of tracheotomy.</u></p>	<p>References:</p> <p>1) Bogomilsky M.R. Children's Otorhinolaryngology. - Moscow: Geotar-Media. - 2006. - 432 p.</p> <p>2) Luchikhin L.A. Otorhinolaryngology. Textbook. Approved by the Ministry of Education of RF.-GEOTAR-Media.- 2016 - 584 p.</p>
<p><u>The student should be able to:</u></p> <p>1. Perform indirect laryngoscopy, diagnose and make differential diagnosis of laryngeal diseases, determine the stage of stenosis, select appropriate therapeutic tactics, perform some therapeutic manipulations, perform tracheostomy when indicated, and in extreme situations perform cricotomy or criconicotomy.</p>	<p>References:</p> <p>1) Luchikhin L.A. Examination of an otorhinolaryngological patient. - GEOTAR Media. - 2014 - 256 p.</p>

Assignment for independent work.

1. The laryngoscopic picture of subclavian laryngitis is presented _____
2. Chronic laryngitis is classified into the following forms _____
3. In its turn there are four varieties of chronic hypertrophic laryngitis _____
4. The most favorable form of laryngeal stenosis is _____
5. The adaptive responses in laryngeal stenosis include _____ mechanisms
6. There are different stages of stenosis _____
7. Laryngeal stenosis is characterized by _____ dyspnea, and tracheal stenosis by _____
8. The main types of tracheostomy _____, depending on _____

9. Laryngeal cancer is divided into three forms according to localization _____
_____ with the most unfavorable of these _____
10. There are the following treatments for malignant tumors _____

Tests.

1. FOR LARYNGOSTENOSIS IN CHILDREN IS PERFORMED
 - 1) upper tracheostomy
 - 2) middle tracheostomy
 - 3) lower tracheostomy
 - 4) conicotomy
2. URGENT TRACHEOTOMY IS INDICATED IN ACUTE LARYNGOSTENOSIS
 - 1) 1st degree
 - 2) 2nd degree
 - 3) 3rd degree
 - 4) 4th degree
3. DURING CONICOTOMY THE LIGAMENT IS DISSECTED
 - 1) signetracheal
 - 2) scapular laryngeal
 - 3) cricothyroid
 - 4) thyroid hyoid
4. ACUTE LARYNGOSTENOSIS IS CAUSED BY
 - 1) chronic hypertrophic laryngitis
 - 2) laryngeal cancer
 - 3) scleroma of the larynx
 - 4) laryngeal diphtheria
5. IN SUBCUTANEOUS NECK EMFYZEMA AFTER TRACHEOSTOMY IS MOST EFFECTIVE
 - 1) introduction of a tracheostomy tube with an inflatable cuff into the trachea
 - 2) replacement of the tracheostomy tube with a tube of larger diameter
 - 3) wide opening of the skin wound
6. THE ATTACK OF FALSE CROUP DEVELOPS MORE FREQUENTLY
 - 1) in the evening
 - 2) at night
 - 3) in the morning
 - 4) in the afternoon
7. THE MOST SEVERE COMPLICATION OF ACUTE SUBGLOTTIC LARYNGITIS
 - 1) persistent dysphonia
 - 2) acute stenosis of the larynx
 - 3) asthmatic bronchitis
 - 4) hypersensitivity of the larynx
8. COMPLEX OF SYMPTOMS CHARACTERISTIC FOR PHLEGMONOUS LARYNGITIS
 - 1) dysphonia and laryngeal pain
 - 2) dysphonia, dysphagia, laryngeal pain, dyspnea
 - 3) dysphagia, chest pain
 - 4) dysphagia, pain when swallowing
9. CLINICAL MANIFESTATION OF SINGLE NODES
 - 1) pain
 - 2) paroxysmal cough
 - 3) persistent dysphonia
 - 4) do not manifest clinically
10. SYMPTOMS CHARACTERISTIC FOR WELL –CONTROLLED LARYNGOSTENOSIS
 - 1) inspiratory dyspnea at rest, pallor of the skin, restless state of the patient
 - 2) reduction and deepening of breathing, loss of pauses between inhalation and exhalation
 - 3) breathing is frequent and shallow, forced position of the patient, cyanosis of the lips, frequent pulse

4) breathing - such as Cheyne-Stokes, fainting, involuntary urination and defecation

Keys

№	Answer	№	Answer
1	3	8	3
2	2	9	4
3	1	10	1
4	2		
5	1		
6	2		
7	3		

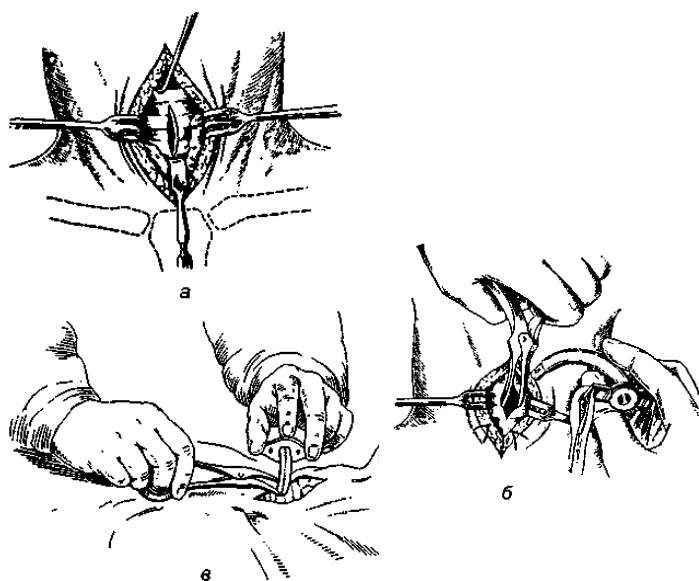


Fig.46. What surgery is shown in the picture, what types of it exist.

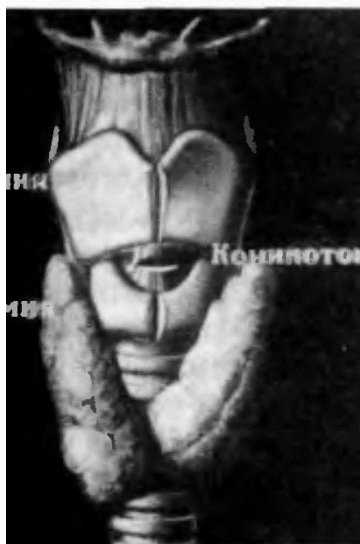

Fig.47. Indicate 3 main types of throat dissection

References:

1. Alekseeva N.S. Dizziness. Otoneurological aspects. - MedPress-Inform. - 2014 -184 p.
2. Altman Ya. A., Tavartkiladze G.A. Guide to audiology. - M.: DMKPress, 2003.-- 360 p.
3. Ananyeva S.V. Diseases of the ear, throat, nose. - Rostov on Don: Phoenix. - 2011. - 412 p.
4. Artyushkin S.A.: Chronic polypous rhinosinusitis and hypertension, - Nauka. - 2009 -112 p.
5. Atlas of ENT diseases. 4th edition. Bull T.R. Edited by M.R. Bogomilsky. - 2007 – 272p.
6. Babanov S.A. Professional sensorineural hearing loss. Monograph, - Infra-M, University textbook. - 2017 - 98 p.
7. Babiyak V.I., Goffman V.R., Nakatis Ya. A. Neurotorinolaryngology. A guide for doctors. - 2002 - 727 p.
8. Babiyak V.I., Nakatis Ya.A. Clinical otorhinolaryngology, a guide for doctors. - 2005 - 200 p.
9. Babiyak V. I., Nakatis Ya. A., Pashchinin A. N., Voronov V. A. Fundamentals of otoneurology. A guide for doctors. - SPb.: "Znanie". - 2015.-720 p.
10. Burbom Hans, Kaschke Oliver, Navka Tadeus. Diseases of the ear, nose and throat. - MEDpress-Inform. - 2016 - 776 p.
11. Blotsky A.A. Snoring phenomenon and obstructive sleep apnea syndrome. - SPb.: SpetsLit. - 2002.-- 176 p.
12. Blotsky A.A., Karpishchenko S.A. Emergencies in otorhinolaryngology. - SPb.: "Esculap", 2009. - 175 p.
13. Bogomilskiy M.R. Pediatric otorhinolaryngology. - M.: Geotar-Media. - 2006.-- 432 p.
14. Boboshko M.Yu. Auditory tube. - SPb.: SpetsLit. - 2003.-- 353 p.
15. Bork K. Diseases of the mucous membrane of the mouth and lips. Clinic, diagnosis and treatment. - M.: Medical literature. – 2011. 448 p.
16. Brandt. T. Dizziness, - Practice. - 2010 - 200 p.
17. Vasilenko Yu.S. Voice. Phoniatic aspects. - M: Energoizdat, 2002.-- 480 p.
18. Wiegand M.E., Iro X. Endoscopic surgery of the paranasal sinuses and anterior skull base. - M.: Med. lit. - 2010.-- 296 p.
19. Gappoeva E. T. Methodological Manual for Practical Lessons in Otorhinolaryngology for Medical Students (Second Edition, Revised, Enlarged) Vladikavkaz 2012, 260 p. UMO-584
20. Gappoeva E.T. A textbook on otorhinolaryngology for students enrolled in the specialty "General MEDICINE" and "MEDICAL-PREVENTIVE BUSINESS" - UMO - 17-29 / 481 - 2012 – 200p.
21. Gersdorf M., J.-M. Gerard Atlas of Middle Ear Surgery - Binom. - 2014 - 152 p.,
22. Govorun M.I.: Damage to ENT organs and neck in peacetime and wartime. A guide for doctors. - SpetsLit. - 2010 - 126 p.

23. Davudov Kh.Sh. Clinical pathology of the larynx. Manual - an atlas for postgraduate training of specialists from scientific, medical and educational medical institutions. - MIA. - 2009 - 160 p.
24. Dementyev A.S., Zhuravleva N.I., Kochetkov S.Yu., Chepanova E.Yu. Otorhinolaryngology. Medical therapy standards. - M.: GEOTAR-Media. - 2016. -- 320 p.
25. Dunnebier E.A. Radiation diagnostics. Otorhinolaryngology. - M.: MEDpress-inform. - 2013. - 360 p.
26. V. A. Epifanov. Rehabilitation for respiratory diseases - GEOTAR-Media. - 2013 - 656 p.
27. Immunology and allergology for ENT doctors. Edited by D.K. Novikov - Medical Information Agency. - 2006 - 512 p.
28. Kozorez E.S. ENT - diseases. - M.: VLADOS-PRESS. - 2005. -- 89 p.
29. Kosyakov S. Ya. Selected issues of practical otosurgery; monograph / - Moscow: MCFER. - 2012. -- 224 p.
30. Kruglikov G.G. Respiratory pathology. Atlas. - Litterra. - 2013 - 272 p.
31. Kryukov A.I. A guide to the emergency treatment of ear and upper respiratory tract diseases. - GEOTAR-Media. - 2016 - 386 p.
32. Kryukov A.I., Fedorova O.K., Antonyan R.G. et al. Clinical aspects of Meniere's disease. M. - 2006. -- 240 p.
33. Laiko A.A., Zabolotny D.I. Recurrent otitis media - 2001 - 153 p.
34. Lopatin A. S. Rhinitis: pathogenetic mechanisms and principles of pharmacotherapy. - Litterra. - 2013 - 368 p.
35. Lopatin A.S., Alexandrova I.A., Varvyanskaya A.V. Rational pharmacotherapy of diseases of the ear, nose and throat. A guide for medical practitioners. - Litterra. - 2013 - 816 p.
36. Luchikhin L. A. Diseases of the upper respiratory tract and ear. Practitioner's Handbook. - GEOTAR-Media. - 2016 - 256 p.
37. Luchikhin L.A. Otorhinolaryngology. Textbook. – Approved by the Ministry of Education of the Russian Federation. - GEOTAR- Media. - 2016 - 584 p.
38. Luchikhin LA Examination of an otorhinolaryngological patient. - GEOTAR-Media. - 2014 - 256 p.
39. Mayorov V. A. Smells. Their perception, impact, elimination. - Mir. - 2006 - 366 p.
40. Mark Remakl, Hans Edmund Eckel. Larynx and trachea surgery. - Binom. - 2015 - 368 p.
41. Martov V. Yu. Medicines in otorhinolaryngology. - M: Medical literature. - 2009 - 496 p.
42. Nosulya E.V. Propedeutics in otorhinolaryngology. - Medical news agency. - 2009 - 180 p.
43. Ovchinnikov Yu. M., Gamow V.P. Diseases of the nose, throat and ear. - M.: Medicine. - 2003 - 320 p.
44. Otorhinolaryngology national guidelines / Ed. member cor. of RAMS V. T. Palchun. - Moscow ed. Gr. GEOTAR-Media. - 2013 - 954 p.
45. Palchun V.T. Diseases of the ear, nose and throat. A textbook for students of institutions of secondary vocational education, studying in the specialty 060101.51 "General Medicine" in the discipline "Diseases of the ear, throat and nose". - GEOTAR-Media. - 2016 - 315 p.

46. Palchun V.T. Inflammatory diseases of the larynx and their complications. Management. - Moscow ed. Gr. GEOTAR - Media. - 2013 .-- 176 p.
47. Palchun V.T. Practical otorhinolaryngology. - M.: Medical Information Agency. - 2006 .-- 368 p.
48. Palchun V.T., Luchikhin L.A. Case history in the ENT hospital / Methodical recommendations. - M: Medicine. - 2004 - 32 p.
49. Palchun V.T., Luchikhin L.A., Kryukov A.I. Inflammatory diseases of the pharynx. - MIA - 2014 - 286 p.
50. Palchun V.T., Luchikhin L.A., Magomedov M.M. Guide to practical otorhinolaryngology. - MIA. - 2011 - 565 p.
51. Palchun V.T., Magomedov M.M., Luchikhin L.A. Otorhinolaryngology textbook. - Moscow ed. Gr. GEOTAR - Media. - 2011 - 656 p.
52. Palchun V.T., Magomedov M.M., Kryukov A.I. Guide to focal infection in otorhinolaryngology, - Moscow ed. gr. GEOTAR-Media. - 2015 - 224 p.
53. Parshin V. D. Tracheostomy. Indications, technique, complications and their treatment. - 2008 .-- 176 p.
54. Piskunov G.Z. Polypoid rhinosinusitis. - Moscow ed. gr. GEOTAR-Media. - 2016 - 96 p.
55. Piskunov I.S., Zavyalov F.N., Piskunov V.S., Kuznetsov M.V. Diagnostics and treatment of rhinosinusogenic orbital complications. -Kursk. - 2004 - 112 p.
56. Piskunov G.Z., Piskunov S.Z. Clinical rhinology. A guide for doctors. - 2nd edition. - M.: LLC "Medical Information Agency". - 2006 .-- 560 p.
57. Piskunov G.Z., Piskunov S.Z. Clinical rhinology. - M.: MIA. - 2013 .-- 560 p.
58. Piskunov G.Z., Piskunov S.Z., Kozlov V.S., Lopatin A.S. Diseases of the nose and paranasal sinuses: endomicrosurgery. - M.: Collection "Top secret". - 2003 .-- 208 p.
59. Pogosov V.S. Atlas of operative otorhinolaryngology. - 2003 - 413 p.
60. Potapov A. A., Lopatin A. S., Kapitanov D. N. Endoscopic diagnosis and treatment of nasal liquorrhea. - Practical medicine. - 2015 - 216 p.
61. Probst R., Grevers G., Iro G. Otorhinolaryngology in clinical practice. - M.: Practical medicine. - 2012 .-- 384 p.
62. Guide to audiology and hearing aid / Ed. Lyatkovsky Ya. B. [Transl. from Polish ed. N.A. Daikhes]. - M. - 2009.-240p.
63. Rulenkova L.I. Audiology and hearing aid. - M.: Academy, 208 p., 2003
64. Ryazantsev S. V., Naumenko N. N., Zakharova G. P. Causes of etiopathogenetic therapy of acute sinusitis / Guidelines. - SPb., 2007 .-- 38 p.
65. Semizorov A.N. X-ray and computed tomographic diagnosis of acute and chronic sinusitis. - Vidar M. - 2012 - 104 p.
66. Stratieva O.V. Clinical anatomy of the ear. - SPb.: SpetsLit. - 2004 - 256 p.
67. Tomassin J.M. Atlas of otorhinolaryngology, larynx. - 2002 - 29 p.
68. Tomassin J.M. Atlas of otorhinolaryngology, external and middle ear. - 2002 – 20p.
69. Tomassin J.M. Atlas of otorhinolaryngology, nose and paranasal sinuses. - 2002 - 28 p.
70. Tos M. Guide to middle ear surgery. In 4 volumes. V. 1. Approaches, myringoplasty, ossiculoplasty and tympanoplasty / Per. from English A.V. Davydov / Ed. A. V. Starokhi - Tomsk: Siberian state. medical university. - 2004. - 412 p.
71. Tsvetkov E.A.: Adenotonsillitis and their complications in children. - SPb.: ELBI-SPb. - 2003 -124 p.

72. Glasscock-Shambeau. Ear surgery: in two volumes – E.J. Gulya, L.B. Minor, D.S. Poe; transl. from English. Ed. S.A. Karpishchenko - M.: Panfilov Publishing House, 2015. Vol. 1. - 416 p.
73. Glasscock-Shambeau. Ear surgery: in two volumes – E.J. Gulya, L.B. Minor, D.S. Poe; transl. from English. Ed. S. A. Karpishchenko - M.: Panfilov Publishing House, 2015. Vol. 2. - 448 p.
74. Chissov V. I., Darialova S. L. Oncology. - Moscow ed. Gr. GEOTAR - Media. - 2007 - 600 p.
75. Chumakov F.I., Deryugina O. V. ENT organs and tuberculosis.- Medicine. - 2004 - 160 p.
76. Shevrygin B.V. Diseases of the ear, nose and throat. - Moscow ed. Gr. GEOTAR - Media. - 2002 - 480 p.
77. Janfaza P. Surgical anatomy of the head and neck. - Panfilov Publishing House / Binom. Knowledge laboratory. - 2014 - 896 p. V Paleri, J Hill: ENT Infections: An Atlas of Investigation and Management, 116 c., 2010