

**State budgetary educational institution of higher
professional education**

**"North Ossetian State Medical Academy" of the Ministry of
health of the Russian Federation**

Department of surgical diseases No. 2

Kalitsova M. V., Totikov Z.V.

INTESTINAL OBSTRUCTION

Textbook for students of the 4th year
of the Faculty of Dentistry in the discipline "Surgical Diseases"

Vladikavkaz

2022

Kalitsova M. V., Totikov Z.V.

Intestinal obstruction: teaching guide for students, studying at “Surgical Diseases” Dentistry faculty. - North Ossetian state medical academy. - Vladikavkaz, 2022. - 20 sh.

This teaching guide covers main issues about etiology, pathogenesis, clinical features, laboratory and instrumental diagnostics and complications of Intestinal obstruction.

Teaching guide “Intestinal obstruction” is made for “Surgical Diseases” discipline in accordance with requirements of FSES HE, and is intended for students from medical universities and faculties, studying for specialty 31.05.03 Dentistry.

Recensents:

Tomaev M.V., Chief Surgeon of the CHEC of the RNO-A, 10.03.2022.

Beslekoev U.S., MD, Associate Professor, Head of the Department of Surgical Diseases No. 1 of the Federal State Budgetary Educational Institution of Higher Education NOSMA of the Ministry of Health of Russia, 10.03.2022.

Approved and recommended for printing by Central Coordinational educational and methodical board FSES HE NOSMA of Russian Ministry of health (№ 4 22.03.22)

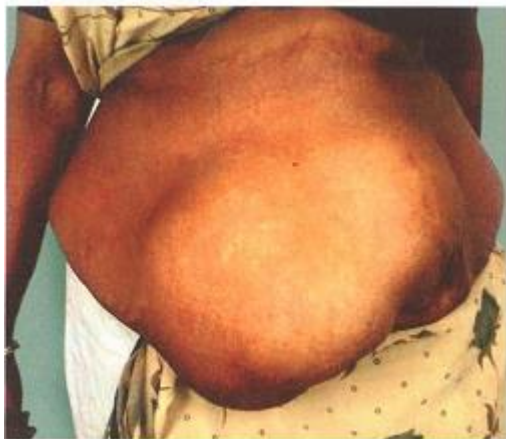© North Ossetian State Medical Academy, 2022

© Kalitsova M.V., Totikov Z.V., 2022

CONTENTS

| | |
|------------------------|----|
| INTRODUCTION..... | 4 |
| CLASSIFICATION..... | 5 |
| PATHOPHYSIOLOGY..... | 7 |
| STRANGULATION..... | 10 |
| CLINICAL FEATURES..... | 11 |
| SIGNS..... | 12 |
| INVESTIGATIONS | 13 |
| TREATMENT | 16 |

- Intestinal obstruction is a challenging surgical emergency encountered by general surgeons. This can affect any age group starting from neonate to an old man. It can affect a school going boy, working woman or a man during their peak of life. Sometimes it can be fatal either due to delay in the diagnosis, delay in the treatment or complications related to surgery. Abdomen is a Pandora's box. Sometimes, it is difficult to pinpoint the cause of obstruction.
- Adhesions and hernia are the two most common causes of intestinal obstruction. Adhesions are more common than hernias nowadays. Laparoscopic surgery has definitely decreased incidence of adhesions. In Western countries more than 50% cases of intestinal obstruction are due to adhesions and only 10-15% are due to obstructed hernia.



However, students should be able to diagnose intestinal obstruction, resuscitate the patients and refer the patient for further surgical treatment. With the availability of sophisticated investigations such as CT scan, diagnosis can be established in majority of cases before surgery. However, in other cases, 'exploratory laparotomy' will give the diagnosis.

Definition

When the intestinal contents fail to move distally, it is called intestinal obstruction. It is the most common surgical disorder (emergency) of the intestines.

Few important facts about intestinal obstruction:

- 80% occur in small bowel
- 20% occur in large bowel
- Majority (more than 80%) of small bowel obstructions are benign in nature. In the large bowel, more than 70% of colonic obstruction is due to malignancy-others being inflammatory bowel diseases, ileocaecal tuberculosis, volvulus, etc.

CLASSIFICATION

I. Depending upon the nature of obstruction

COMMONLY USED TERMINOLOGY

- **Mechanical obstruction**
There is a physical barrier which prevents the normal progress of intestinal contents.
- **Paralytic ileus**
There is no physical barrier but failure of peristalsis to propel intestinal contents due to neurogenic causes.
- **Simple obstruction**
It refers to obstruction to lumen only (early cases)
- **Strangulated obstruction**
It refers to obstruction with impairment of blood supply to the gut.
- **Closed loop obstruction**
In this condition, the intestine is occluded in two places. More chances of gangrene and perforation are present, e.g. volvulus.
- **Pseudo-obstruction:** No mechanical cause.

A. Dynamic obstruction/mechanical obstruction

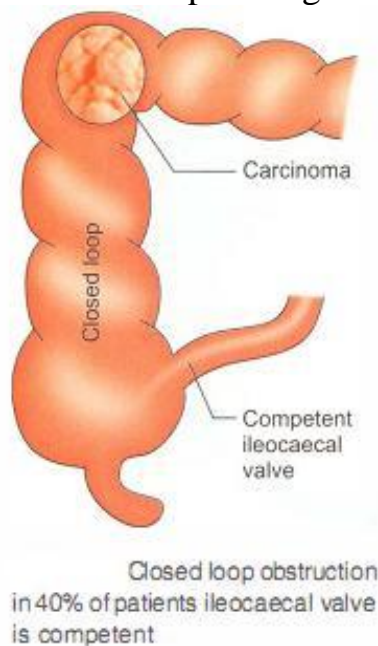
B. Adynamic obstruction-paralytic ileus or neurogenic ileus.

II. Depending on the blood supply

A. Simple obstruction: Blood supply is not seriously impaired.

B. Strangulated obstruction: Blood supply is seriously impaired.

C. Closed loop obstruction: It means both proximal and distal ends are blocked. This occurs in carcinoma of the right colon with constrictive lesions. If the ileocaecal valve is competent and the obstruction is total, the intraluminal pressure within the colon increases. As a result of this, the caecum may perforate. Thus, closed loop obstruction can be dangerous (Fig. 1). Another example is sigmoid volvulus.



(Fig. 1)

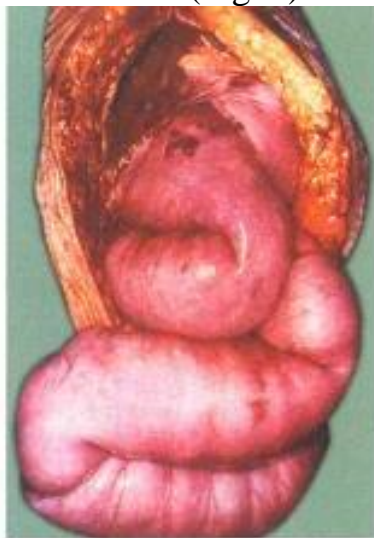
I. Depending upon the cause of obstruction

A. In the lumen of the gut

- Gall stones ileus
- Food bolus obstruction
- Roundworm mass
- Foreign body (rare)
- Meconium ileus
- B. In the wall of the gut
 - Stricture, e.g. tuberculosis
 - Crohn 's disease
 - Carcinoma
 - Atresia
 - Adhesions
- C. Outside the wall of the gut
 - Volvulus, intussusception
 - Congenital bands
 - Meckel's diverticulum with band
 - Obstructed hernia

II. Depending upon severity of obstruction

- A. Acute obstruction: Signs and symptoms appear very early. Usually, it affects small bowel, obstructed hernia, bands.
- B. Chronic obstruction (e.g. carcinoma colon) affects large bowel (colic comes first, distension later). Diverticular disease also produces chronic obstructions (Fig. 2).



Dilated small
intestinal loops in a case of
ileal obstruction

(Fig. 2)

- C. Acute on chronic obstruction develops in carcinoma colon, wherein an acute obstruction suddenly results due to the accumulation of faecal matter in the proximal bowel.

PATHOPHYSIOLOGY

- As a result of obstruction, the proximal bowel undergoes hyperperistalsis which is responsible for colicky pain abdomen. The peristalsis may continue for a few days and later the intestine may be paralysed and laccid. After 3-4 hours, distal to the obstruction, all physiological activities of the bowel are stopped. Intestine becomes contracted, pale and does not exhibit peristalsis. After a few hours, the proximal bowel gets dilated secondary to obstruction.

- The causes of distension of intestinal loop are:

A. Gaseous distension

- Swallowed air (70%). Because of colic and anxiety, the swallowed air is increased. Oxygen is absorbed and nitrogen remains as it cannot be absorbed. This results in distension.

- Diffusion of air from the blood into bowel lumen increases carbon dioxide which diffuses very rapidly.

- Gas due to bacterial activity releases H_2S , NH_3 , etc.

B. Distension due to fluids

- 1500 ml of saliva

- 2 litres of gastric juice

- 3 litres of intestinal secretions

- 1 litre of bile and pancreatic juice

Normally, all this fluid is absorbed in the bowel. In cases of intestinal obstruction, this fluid absorption is delayed. It accumulates in the intestinal loop. Excretion of water and electrolytes into the lumen is also increased.

C. Role of nitric oxide

Activated neutrophils and macrophages accumulate within the muscular layer of the bowel wall due to dilatation and inflammation of the bowel wall.

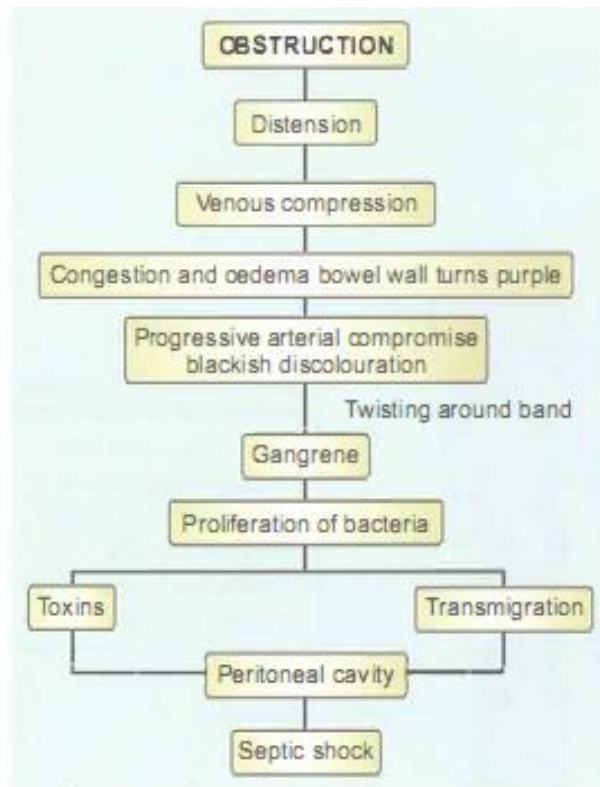
This damages the secretory and motor processes by release of reactive proteolytic enzymes and cytokines. Net result is increase in the local release of nitric oxide, itself a potent inhibitor of smooth muscle tone. It further aggravates the intestinal dilatation.

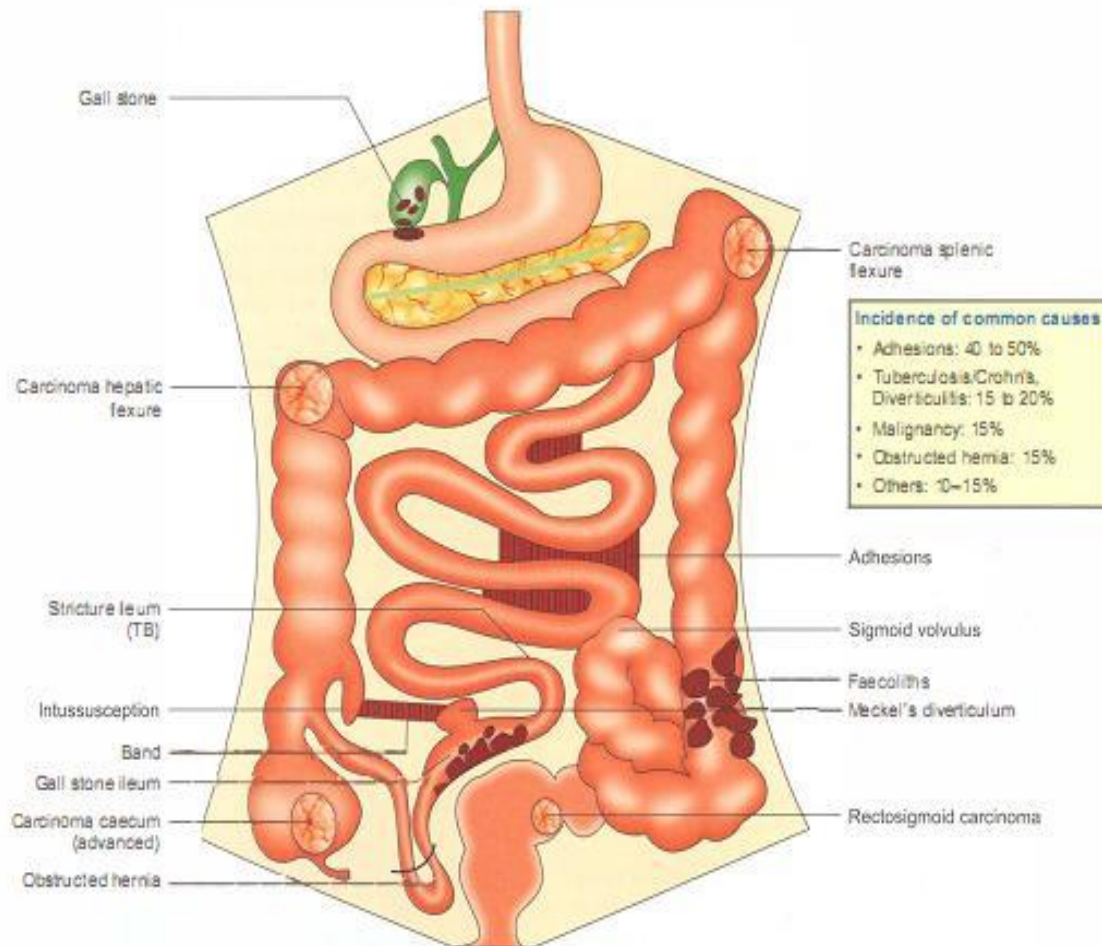
D. Role of bacteria

- Bacterial colony count increases following obstruction resulting in stasis. From less than 10^6 in jejunum and from 10^8 in ileum, counts increase.

- Bacterial translocation can occur even in simple obstruction without strangulation. Thus, bacteria can enter into lymph nodes and into systemic circulation. Abdominal distension, hypovolaemia, renal failure and sepsis set in. In addition to these changes, diaphragm gets elevated, respiration is impaired which result in respiratory complications such as atelectasis and basal pneumonia.

- In doubtful cases of viability, if facilities are available, test called fluorescein test can be done. 1000 mg of fluorescein is injected into peripheral vein and bowel is inspected under Wood light. If loops are nonviable, resection and anastomosis is done.





COMMON CAUSES OF ILEAL OBSTRUCTION

- Adhesions
- Obstructed hernia
- Stricture
- Intussusception
- Ileocaecal tuberculosis
- Bands
- Worm ball—in children
- Ileal atresia—in children

COMMON CAUSES OF COLONIC OBSTRUCTION

- Carcinoma colon
- Sigmoid volvulus
- Faecal impaction
- Mesenteric ischaemia
- Hirschsprung's disease
- Anorectal malformations
- Stricture colon—rare

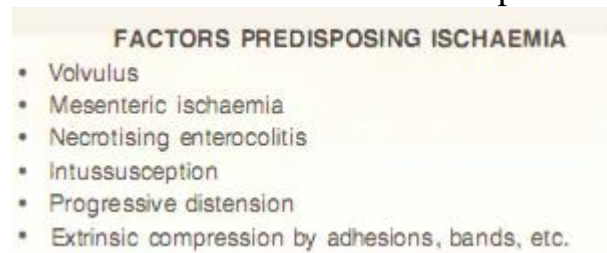
COMMON CAUSES OF GANGRENE

- Volvulus
- Intussusception
- Obstructed hernia
- Mesenteric vascular occlusion
- Twisting around a band
- Necrotising enterocolitis

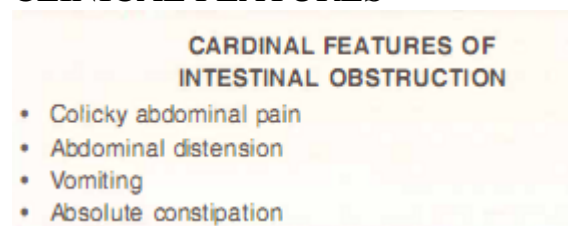
Differential diagnosis of intestinal obstruction—diagrammatic representation

STRANGULATION

- Interference with blood supply: As the tension within the loops becomes more and more, venous congestion takes place resulting in oedema of the bowel wall.
- If the obstruction is not relieved, capillary rupture and haemorrhage into bowel may ensue. In cases of volvulus and intussusception, the arterial supply gets compromised rapidly causing gangrene of bowel wall very early. Bacterial proliferation takes place and endotoxins are released.
- Transmigration (translocation) of gram-negative organisms, anaerobes and gram-positive organisms through the gangrenous bowel results in peritonitis.
- The organisms release powerful endotoxins which are absorbed from the peritoneal surface and cause gram-negative shock or septic shock. It carries very high mortality rate (30%).
- Early gangrene without obstruction is a feature of mesenteric thrombosis or embolism.
- Loss of blood volume is an important feature of massive gangrene.



CLINICAL FEATURES



1. Pain abdomen: Central abdominal pain is a feature of small intestinal obstruction and peripheral pain is a feature of large intestinal obstruction. The pain is colicky in nature, lasts for 5-10 minutes and is intermittent. On pressure, it decreases.

2. Vomiting is due to reverse peristalsis. Vomitus consists of stomach contents initially, then bile, followed by faeculent matter. Faeculent is not faecal matter but terminal ileal contents which undergo bacterial degradation and fermentation resulting in the smell of faecal matter. Vomiting of altered blood indicates haemorrhage and gangrene. Frequent vomiting reflects jejunal obstruction.

| Comparison of clinical features at different levels of intestinal obstruction | | | |
|---|----------------------------------|---------------------------------------|--|
| | High (jejunum) | Distal (ileum) | Low (colon) |
| • Vomiting | Frequent, bilious | Moderate bilious, faeculent | Late vomiting, faeculent |
| • Distension | No | Moderate distension | Marked distension |
| • Pain | Intermittent, not crescendo type | Intermittent, crescendo type, colicky | Variable pain, not classical crescendo |
| • Constipation | Not initially | Not initially | Initially present |
| • Peristalsis | Not seen | Step ladder peristalsis | Right to left peristalsis may be seen |

3. Distension of the abdomen: It may be central abdominal distension as seen in ileal obstruction, peripheral abdominal as in large bowel obstruction, or localised to one or two quadrants as in sigmoid volvulus.

4. Constipation occurs because the distal bowel does not move. Constipation to faeces and latus is called obstipation.

SIGNS

1. General signs of dehydration such as dry skin, dry tongue, sunken eyes, feeble pulse, low urinary output are seen. Dehydration occurs due to persistent vomiting and sequestration of fluid and electrolytes. Hypokalaemia is an important finding.

2. Abdominal findings

- Distension, tympanitic note on percussion

- Step ladder peristalsis is seen in terminal ileal obstruction.

Right to left colonic peristalsis is seen in left-sided colonic obstruction, large bowel obstruction.

- On auscultation-loud, noisy intestinal sounds are heard. They are called borborygmi.

- Hernial orifices have to be examined, especially for a femoral hernia in females.

Signs of strangulation

- It should be suspected when features of obstruction are present along with features of shock.

- Features of septic shock-fever, hypothermia, renal failure, respiratory failure

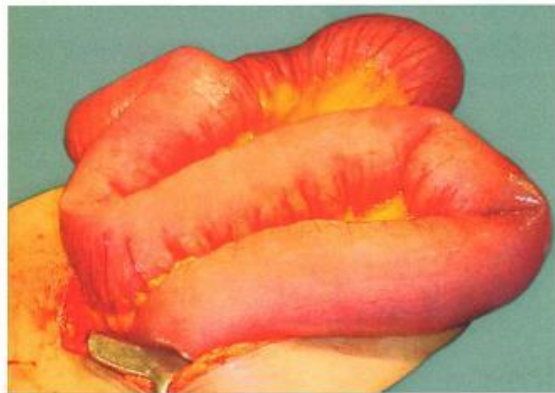
FEATURES OF STRANGULATION

- Tachycardia
- Tenderness
- Temperature—fever
- Acidosis

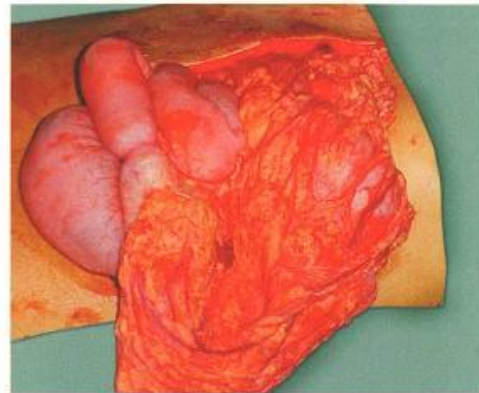
- Rebound tenderness: It is called Blomberg's sign. It is a classical sign of peritonitis.

- Guarding and rigidity of the abdominal wall.

- Absent bowel sounds because rest of the bowel loops undergo paralytic ileus.
- Sudden symptoms-spasmodic pain (due to peristalsis) and continuous pain suggest strangulation.
- Features of strangulation and perforation occur quickly in cases of closed loop obstruction (Fig. 3).



Dilated intestinal loops



Perforation due to obstruction

(Fig. 3)

CLOSED LOOP OBSTRUCTION

- This occurs when the bowel is obstructed at both proximal and distal points.
- Proximal bowel is not distended as much in this condition
- Gangrene and perforation can occur fast
- Retrograde thrombosis of mesenteric vein, can result in distension of the bowel.
- A few examples of closed loop obstruction include sigmoid volvulus, strangulated hernia, carcinoma right colon.

Rectal examination

- In small bowel obstruction, rectum is empty and is often ballooned out.
- Carcinomatous growth with or without stools can be felt.
- The finger may be stained with blood.
- The small intestine is considered dilated if loops of bowel measure more than 3 cm in diameter. Measurements for the large bowel vary among different anatomic segments, with a relative threshold of 9 cm in diameter for the proximal colon and 5 cm for the sigmoid colon.

INVESTIGATIONS

- Complete blood picture: Low Hb% indicates underlying malignancy. Increased total WBC count indicates infection and sepsis (perforation).

- **Electrolytes:** Most of the electrolytes are low in cases of intestinal obstruction and require correction preoperatively. Strangulation may be associated with deranged potassium, amylase or lactic dehydrogenase.
- **Plain X-ray abdomen in the erect position** may show multiple gas fluid levels. Gas levels appear earlier than fluid level. Normally, two insignificant fluid levels can be present, one in the terminal ileum and one in the first part of the duodenum.

**PLAIN X-RAY FINDINGS
UPRIGHT AND SUPINE**

- First get supine films. They indicate distal limit of obstruction. Erect films are asked if any doubt exists about obstruction.
- Jejunum is characterised by regularly placed mucosal folds called **valvulae conniventes** (Fig. 30.14) placed opposite to each other (**Herring bone pattern**). They are produced by **valves of Kerckring**.
- Large bowel is characterised by **haustrations** (Fig. 30.15): Incomplete, large mucosal folds, not placed opposite to each other.
- **Caecum has no haustrations**. It appears as a round gas shadow in the right iliac fossa.
- Ileum has no characters—**characterless loop of Wangensteen**.
- Plain X-ray may demonstrate gall stone ileus or foreign body.
- Gas is absent in the small bowel as in mesenteric vascular ischaemia.
- Sigmoid volvulus appears as a large dilated loop—inverted 'U' shape.

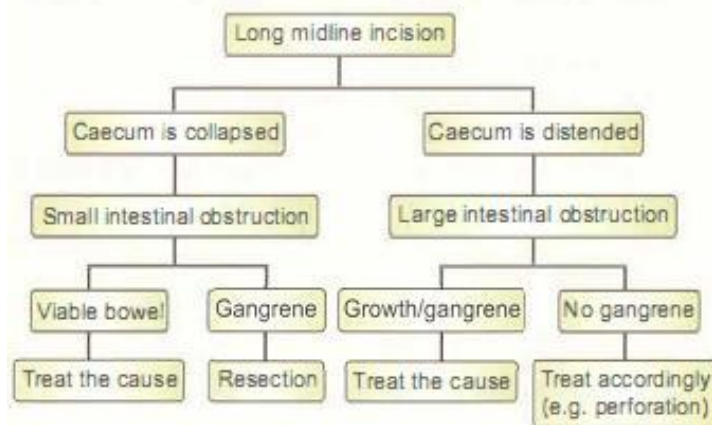
MANAGEMENT

Preoperative preparation includes correction of dehydration, electrolytes and broad spectrum antibiotics. Principles in the management of intestinal obstruction are as follows:

- A. **Aspiration with Ryle's tube.** This is the most important step in the management of intestinal obstruction. It helps in decreasing the distension and also prevents vomiting. This will help in preventing respiratory complications, such as aspiration following general anaesthesia.
- B. **Bowel care:** No purgatives because purgation can cause perforation.
- C. **Charts:** Temperature, pulse, respiration and intake-output chart. In cases of conservative management such as obstruction due to adhesions, change in temperature and increasing pulse rate suggests perforation or gangrene. These cases have to be explored immediately.
- D. **Drugs** to cover gram-positive, gram-negative and anaerobic organisms.
- E. **Exploratory laparotomy** is done and depending upon the findings, obstruction is treated.
- F. **Fluids** should be given before, during and after surgery. It forms the most important treatment of intestinal obstruction.

PRINCIPLES OF EXPLORATORY LAPAROTOMY

- Ideally done within 6–8 hours
- Long midline incision
- Resection of gangrene and anastomosis
- Adhesion—release
- Bands—divide
- Gall stone ileus—remove the stone
- Volvulus—untwist or resection
- Obstructed hernia—reduce
- Gangrene—resect
- Stricture—resection or stricturoplasty
- Advanced malignancy—bypass



Principles of management of intestinal obstruction

APPROACH TO THE MANAGEMENT OF INTESTINAL OBSTRUCTION

Ask the following questions to yourself and proceed.

1. What is the probable cause of obstruction?
2. Is it small bowel obstruction at laparotomy?
3. Is it large bowel obstruction at laparotomy?
4. Is it simple obstruction?
5. Is it strangulation?
6. Is it some kind of a surprise or a difficult case?
7. Can I manage conservatively?

1. Probable cause of obstruction

- A previous laparotomy scar may indicate that it could be an adhesive obstruction (most common).
- An obvious obstructed hernia (inguinal or femoral) can be managed with inguinal approach.
- An elderly man, hypertensive and atherosclerotic, with features of blood in the stools and acute abdominal pain may be having superior mesenteric ischaemia.

- A constipated, elderly man in poor health, with acute or chronic obstruction may be having carcinoma of the colon.

2. Diagnosis of small bowel obstruction at laparotomy

- Caecum is collapsed
- Dilated loops of small intestine are present.
- A stricture or a mass lesion may be obvious at laparotomy.

3. Diagnosis of simple obstruction

- It is done when bowel is not gangrenous.
- In doubtful cases, because of long-standing ischaemia, wrapping the bowel with warm and moist pack and administration of pure oxygen may help the bowel to recover from ischaemia.

4. Diagnosis of large bowel obstruction at laparotomy

- Caecum is distended.
- A growth may be palpable and obvious in the transverse colon or in the hidden colon, i.e. splenic flexure.
- It is very important to examine the entire colon (synchronous carcinoma is more common).

5. Diagnosis of strangulation

VIABLE BOWEL—FEATURES

- Normal peristalsis
- Normal peritoneal sheen is present
- Normal pulsations are visible or felt at the mesentery
- Normal pink colour is present

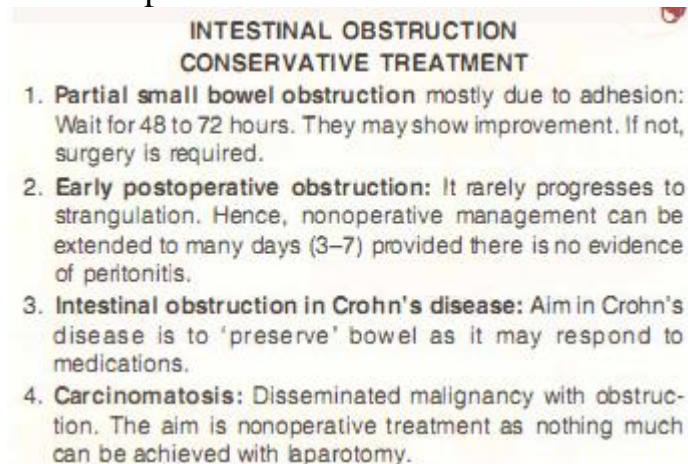
- Black, dark, foul-smelling bowel is seen as soon as laparotomy is done.
- Peritoneal fluid contains blood-stained fluid.
- Precautions must be taken not to contaminate peritoneal cavity when gangrenous segment is removed. Do not hesitate to take the help of senior experienced surgeons in treating an uncommon situation such as massive ischaemia and gangrene of small bowel and colon (due to mesenteric vascular occlusion), synchronous carcinoma and ileosigmoid knotting, etc.

6. It is a surprise

- Surprises are well known in intestinal obstruction. Congenital bands, foreign bodies, internal herniation, lymphomatous strictures are a few examples.
- The detailed management of individual cases is discussed below.

7. Can I manage conservatively?

- In these cases, a long intestinal tube called Miller-Abbott tube can be passed to decompress intestines.



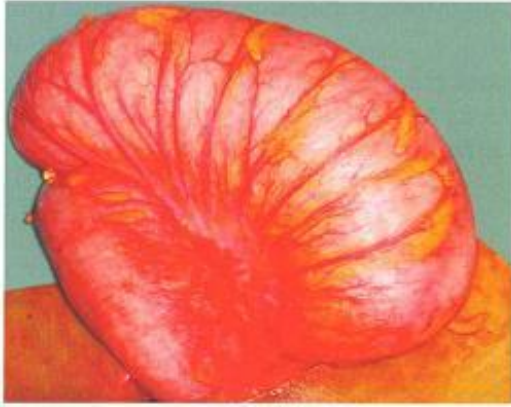TREATMENT

I. Nonoperative

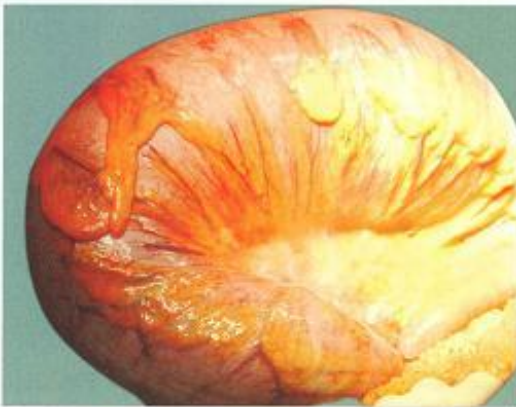- A successful passage of flatus tube or sigmoidoscope up to 25-30 cm results in release of a large amount of flatus and fluid and obstruction is relieved. If obstruction is completely relieved or if there is no gangrene and the general condition of the patient improves, an elective resection is done after 7 days. If resistance is found while passing flatus tube, instill barium for guidance.

II. Operative treatment

1. **Single-stage resection**: This can be done, provided general condition of the patient is good. If the loop is gangrenous, resection followed by end to end anastomosis is done, after giving 'on table' lavage using saline washes till the contents of the colon are clear. Sigmoid colon is hugely dilated (Figs 5).



Sigmoid colon at surgery—huge distension results in severe hypovolaemic shock



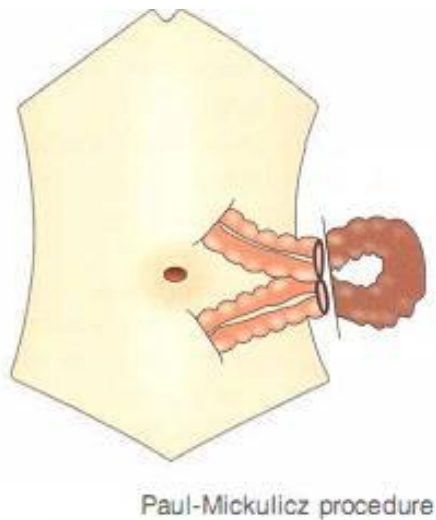
Distended sigmoid with venous congestion

(Fig. 5)

2. Hartmann's procedure: If the loop is gangrenous and proximal bowel is loaded with faecal matter, resection of the sigmoid colon is done. Proximal descending colon is brought out as an end colostomy and rectum is closed (Hartmann's procedure). After 6 weeks, colorectal anastomosis is done.

3. Sigmoidopexy: If the loop is not gangrenous, untwist the sigmoid loop and fix the sigmoid to the posterior abdominal wall (sigmoidopexy). If the mesentery is long, it can be made short by plication.

4. Exteriorisation: Paul-Mickulicz procedure is done when general condition of the patient is poor as in elderly patients, in severely dehydrated patient with impending septicaemia. In such cases, the gangrenous loop is brought outside and resected, with a proximal colostomy and a distal mucous fistula (Fig. 6).



(Fig. 6)

1. Which of the following is true for closed loop obstruction?
 - A. Can occur with constrictive growth in the hepatic flexure
 - B. Ileocaecal valve is incompetent
 - C. Perforation of the sigmoid colon is common
 - D. Occurs with partial obstruction
2. Which of the following is not the cause of gangrene in intestinal obstruction?
 - A. Ileocaecal tuberculosis
 - B. Mesenteric vascular occlusion
 - C. Necrotising enterocolitis
 - D. Volvulus
3. Feculent vomiting is pathognomonic of:
 - A. Jejunal obstruction
 - B. Terminal ileal obstruction
 - C. Duodenal obstruction
 - D. Colonic obstruction

4. Cardinal features of intestinal obstruction include all of the following except:
- A. Colicky abdominal pain
 - B. Vomiting
 - C. Diarrhoea
 - D. Abdominal distension
5. The following is true in a plain X-ray of abdomen in intestinal obstruction:
- A. Caecum can appear as round shadow
 - B. Ileum has valvulae conniventes
 - C. Colon has haustrations
 - D. Sigmoid appears shapeless
6. Features of strangulation includes all of the following except:
- A. Tachycardia
 - B. Disappearance of pain abdomen
 - C. Fever
 - D. Acidosis
7. The features of viable bowel includes all of the following except:
- A. Normal peristalsis
 - B. Normal pulsations are visible
 - C. Normal pink colour is present
 - D. Peritoneal sheen is absent
8. Conservative treatment is advocated in intestinal obstruction when there is:
- A. Disseminated malignancy with obstruction
 - B. Complete obstruction with adhesions
 - C. Postoperative obstruction with peritonitis
 - D. Crohn's disease unresponsive to medications
9. 'Bent inner tube design', 'Omega sign', 'Bird's beak design' are all seen in:
- A. Sigmoid volvulus
 - B. Caecal volvulus
 - C. Meckel's diverticulum
 - D. Bascule
10. The most common cause of intestinal obstruction in infants aged 6-18 months is:
- A. Worms
 - B. Bands
 - C. Intussusception
 - D. Adhesions

ANSWERS: 1-A 2-A 3-B 4-C 5-A 6-B 7-D 8-A 9-A 10-C

Literature:

1. K Rajgopal Shenoy, Anitha Shenoy. Manipal Manual of Surgery. CBS Publishers & Distributors. Forth Edition. 729-772.
2. Harold Ellis, Sir Roy Calne, Christopher Watson. General Surgery Lecture Notes. Wiley BlackWell. 2016. 183-193
3. Jackson PG, Raiji MT. Evaluation and management of intestinal obstruction. Am Fam Physician. 2011;83:159–165.
4. Sclabas GM, Sarosi GA, Khan S, Michael G, Sarr MG, Behrns KE. Small bowel obstruction. In: Zinner MJ, Ashley SW, editors. Maingot's abdominal operations. New York: McGraw Hill Professional; 2013. pp. 585–610.
5. Mucha P., Jr Small intestinal obstruction. Surg Clin North Am. 1987;67:597–620.
6. Catena F, Di Saverio S, Kelly MD, Biffl WL, Ansaloni L, Mandala V, et al. Bologna guidelines for diagnosis and management of adhesive small bowel obstruction (ASBO): 2010 evidence-based guidelines of the World Society of Emergency Surgery. World J Emerg Surg. 2011;6:5.
7. Markogiannakis H, Messaris E, Dardamanis D, Pararas N, Tzertzemelis D, Giannopoulos P, et al. Acute mechanical bowel obstruction: clinical presentation, etiology, management and outcome. World J Gastroenterol. 2007;13:432–437.
8. Silva AC, Pimenta M, Guimaraes LS. Small bowel obstruction: what to look for. Radiographics. 2009;29:423–439.
9. Holzheimer RG, Mannick JA, editors. Munich: Zuckschwerdt; 2001. Surgical Treatment: Evidence-Based and Problem-Oriented.
10. Perea Garcia J, Turegano Fuentes T, Quijada Garcia B, Trujillo A, Cereceda P, Diaz Zorita B, et al. Adhesive small bowel obstruction: predictive value of oral contrast administration on the need for surgery. Rev Esp Enferm Dig. 2004;96:191–200.

All the illustrated materials are taken from «Manipal Manual of Surgery. CBS Publishers & Distributors. Fourth Edition. Edited by K Rajgopal Shenoy, Anitha Shenoy»