

№ЛД -21ИИ

**State budgetary educational institution of higher professional
education
"North Ossetian State Medical Academy" of the Ministry of health of
the Russian Federation**

Department of Surgery Diseases №2

IT IS APPROVED

Minutes of the meeting of the Central
Coordinating Educational and
Methodological Council
From "23 " may 2023 № 5

Evaluation materials


by discipline « **Faculty Surgery** »

the main professional educational program of higher education - a specialty program in the
specialty 31.05.01 Medical affairs, approved by 24.05.2023.

For students of the 4th year

by specialty 31.05.02 General Medicine

Considered and approved at the meeting of the Department
Dated May 19, 2023 (Protocol No. 10)

Head of the department
academic degree of MD.
professional.  (V.Z. Totikov)

Vladikavkaz 2023

STRUCTURE OF EVALUATION MATERIALS

1. Title page
2. Structure of evaluation materials
3. Review of evaluation materials
4. Passport of evaluation materials
5. Set of evaluation materials:
 - questions about the module
 - exam questions
 - bank situational tasks
 - bank of practical tasks
 - business games
 - benchmarks of test tasks (with title sheet and table of contents)
 - exam tickets

**ФЕДЕРАЛЬНОЕ ГОСУДАРСТВЕННОЕ БЮДЖЕТНОЕ ОБРАЗОВАТЕЛЬНОЕ
УЧРЕЖДЕНИЕ ВЫСШЕГО ОБРАЗОВАНИЯ
«СЕВЕРО-ОСЕТИНСКАЯ ГОСУДАРСТВЕННАЯ МЕДИЦИНСКАЯ АКАДЕМИЯ»
МИНИСТЕРСТВА ЗДРАВООХРАНЕНИЯ РОССИЙСКОЙ ФЕДЕРАЦИИ**

**РЕЦЕНЗИЯ
на оценочные материалы**

по дисциплине Факультетская хирургия

для студентов 4 курса

по специальности 31.05.01 Лечебное дело (для студентов обучающихся на английском языке)

Оценочные материалы составлены на кафедре хирургических болезней №2 на основании рабочей программы дисциплины «Факультетская хирургия», утвержденной 2020 годом и соответствуют требованиям ФГОС ВО для специальности 31.05.01 Лечебное дело.

Оценочные материалы включают в себя:

- вопросы к модулю
- вопросы к экзамену
- банк ситуационных задач
- банк практических заданий
- банк деловых игр
- эталоны тестовых заданий (с титульным листом и оглавлением),
- экзаменационные билеты

Вопросы для оценки знаний по модулям позволяют адекватно оценить уровень подготовки студентов по дисциплине.

Банк ситуационных задач включают в себя сами задания и шаблоны ответов. Все задания соответствуют рабочей программе по дисциплине «Факультетская хирургия», формируемым при ее изучении компетенциям, и охватывают все её разделы. Банк содержит ответы ко всем ситуационным задачам.

Банк практических заданий и деловых игр соответствуют рабочей программе по дисциплине «Факультетская хирургия», формируемым при ее изучении компетенциям, и охватывают все её разделы.

Эталоны тестовых заданий включают в себя следующие элементы: тестовые задания, шаблоны ответов. Все задания соответствуют рабочей программе дисциплины

«Факультетская хирургия» формируемым при ее изучении компетенциям, и охватывают все её разделы. Сложность заданий варьируется. Количество заданий по каждому разделу дисциплины достаточно для проведения контроля знаний и исключает многократное повторение одного и того же вопроса в различных вариантах. Эталоны содержат ответы ко всем тестовым заданиям.

Количество экзаменационных билетов достаточно для проведения экзамена и исключает неоднократное использование одного и того же билета во время экзамена в течение одного дня. Экзаменационные билеты выполнены на бланках единого образца по стандартной форме, на бумаге одного цвета и качества. Экзаменационный билет включает в себя 2 вопроса. Формулировки вопросов совпадают с формулировками перечня вопросов, выносимых на экзамен. Содержание вопросов одного билета относится к различным разделам рабочей программы дисциплины, позволяющее более полно охватить материал дисциплины.

Дополнительно к теоретическим вопросам предлагается банк ситуационных задач. Ситуационные задачи дают возможность объективно оценить уровень усвоения обучающимся теоретического материала при текущем контроле успеваемости и промежуточной аттестации. Сложность вопросов в экзаменационных билетах распределена равномерно.

Замечаний к рецензируемым оценочным материалам нет.

В целом, оценочные материалы по дисциплине «Факультетская хирургия» способствуют

качественной оценке уровня владения обучающимися универсальными, общепрофессиональными и профессиональными компетенциями.

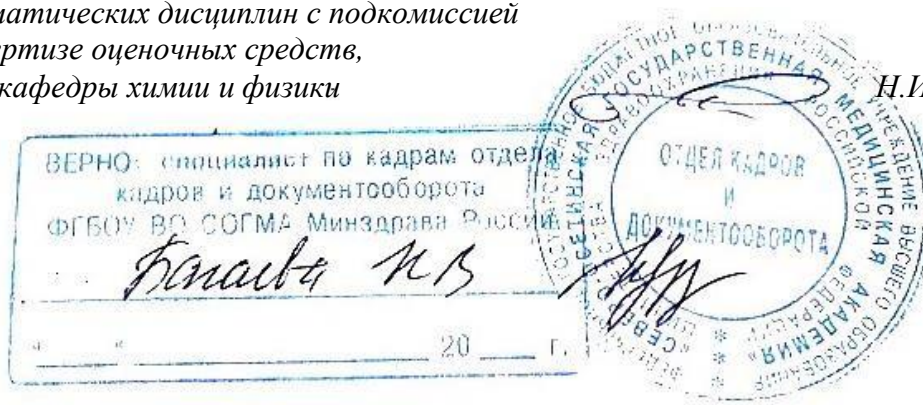Рецензируемые оценочные материалы по дисциплине «Факультетская хирургия»

могут быть рекомендованы к использованию для текущего контроля успеваемости и промежуточной аттестации на лечебном факультете у обучающихся 4 курса (для студентов обучающихся на английском языке).

Рецензент:

*Председатель ЦУМК естественнонаучных
и математических дисциплин с подкомиссией
по экспертизе оценочных средств,
доцент кафедры химии и физики*

Н.И. Боцьева



РЕЦЕНЗИЯ на оценочные материалы

по дисциплине Факультетская хирургия

для студентов 4 курса

по специальности 31.05.01 Лечебное дело для студентов обучающихся на английском языке)

Оценочные материалы составлены на кафедре хирургических болезней №2 на основании рабочей программы дисциплины «Факультетская хирургия», утвержденной 2020 годом и соответствуют требованиям ФГОС ВО для специальности 31.05.01 Лечебное дело.

Оценочные материалы включают в себя:

- вопросы к модулю
- вопросы к экзамену
- банк ситуационных задач
- банк практических заданий
- банк деловых игр
- эталоны тестовых заданий (с титульным листом и оглавлением),
- экзаменационные билеты

Вопросы для оценки знаний по модулям позволяют адекватно оценить уровень подготовки студентов по дисциплине.

Банк ситуационных задач включают в себя сами задания и шаблоны ответов. Все задания соответствуют рабочей программе по дисциплине «Факультетская хирургия», формируемым при ее изучении компетенциям, и охватывают все её разделы. Банк содержит ответы ко всем ситуационным задачам.

Банк практических заданий и деловых игр соответствуют рабочей программе по дисциплине «Факультетская хирургия», формируемым при ее изучении компетенциям, и охватывают все её разделы.

Эталоны тестовых заданий включают в себя следующие элементы: тестовые задания, шаблоны ответов. Все задания соответствуют рабочей программе дисциплины «Факультетская хирургия» формируемым при ее изучении компетенциям, и охватывают все её разделы. Сложность заданий варьируется. Количество заданий по каждому разделу дисциплины достаточно для проведения контроля знаний и исключает многократное повторение одного и того же вопроса в различных вариантах. Эталоны содержат ответы ко всем тестовым заданиям.

Количество экзаменационных билетов достаточно для проведения экзамена и исключает неоднократное использование одного и того же билета во время экзамена в течение одного дня. Экзаменационные билеты выполнены на бланках единого образца по стандартной форме, на бумаге одного цвета и качества. Экзаменационный билет включает в себя 2 вопроса. Формулировки вопросов совпадают с формулировками перечня вопросов, выносимых на экзамен. Содержание вопросов одного билета относится к различным разделам рабочей программы дисциплины, позволяющее более полно охватить материал дисциплины.

Дополнительно к теоретическим вопросам предлагается банк ситуационных задач. Ситуационные задачи дают возможность объективно оценить уровень усвоения обучающимся теоретического материала при текущем контроле успеваемости и


промежуточной аттестации. Сложность вопросов в экзаменационных билетах распределена равномерно.

Замечаний к рецензируемым оценочным материалам нет.

В целом, оценочные материалы по дисциплине «Факультетская хирургия» способствуют качественной оценке уровня владения обучающимися универсальными, общепрофессиональными, профессиональными компетенциями.

Рецензируемые оценочные материалы по дисциплине «Факультетская хирургия» могут быть рекомендованы к использованию для текущего контроля успеваемости и промежуточной аттестации на лечебном факультете у обучающихся 4 курса (для студентов обучающихся на английском языке).

Заместитель главного врача
по хирургии
ГБУЗ РКБСМП МЗ РСО-Алания



М.В.Томаев

« 10 » мая

2023 г.

Паспорт оценочных материалов
По дисциплине
« Faculty Surgery »

№п/п	Наименование контролируемой темы дисциплины	Код формируемой компетенции(этапа)	Наименование оценочного материала
1	2	3	4
Вид контроля	Входной контроль знаний		Тестовые задания
Вид контроля	Текущий контроль успеваемости		
1.	Acute appendicitis. Complications. cholelithiasish.Acute cholecystitis. Acute pancreatitis. Abdominal hernia. Complications of hernias. Acute intestinal obstruction. Pylorus stenosis. Ulcer penetration. Malignancy. Perforated gastric ulcer and duodenal ulcer. Gastrointestinal bleeding. Acute peritonitis. Diseases of the rectum. Colon diseases. Diseases of the breast. Purulent-inflammatory diseases of the lungs and pleura. Lower limb vein disease	UC -5	test tasks, questions about the module, bank situational tasks, Bank of business games, bank of practical tasks
2.	Acute appendicitis. Complications. cholelithiasish.Acute cholecystitis. Acute pancreatitis. Abdominal hernia. Complications of hernias. Acute intestinal obstruction. Pylorus stenosis. Ulcer penetration. Malignancy. Perforated gastric ulcer and duodenal ulcer. Gastrointestinal bleeding. Acute peritonitis. Diseases of the rectum. Colon diseases. Diseases of the breast. Purulent-inflammatory diseases of the lungs and pleura. Lower limb vein disease	GPC -1	test tasks, questions about the module, bank situational tasks, Bank of business games, bank of practical tasks
3.	Acute appendicitis. Complications. cholelithiasish.Acute cholecystitis. Acute pancreatitis. Abdominal hernia. Complications of hernias. Acute intestinal obstruction. Pylorus stenosis. Ulcer penetration. Malignancy. Perforated gastric ulcer and duodenal ulcer. Gastrointestinal bleeding.	PC -1	test tasks, questions about the module, bank situational tasks, Bank of business games, bank of practical tasks

	Acute peritonitis. Diseases of the rectum. Colon diseases. Diseases of the breast. Purulent-inflammatory diseases of the lungs and pleura. Lower limb vein disease		
4.	Acute appendicitis. Complications. cholelithiasish.Acute cholecystitis. Acute pancreatitis. Abdominal hernia. Complications of hernias. Acute intestinal obstruction. Pylorus stenosis. Ulcer penetration. Malignancy. Perforated gastric ulcer and duodenal ulcer. Gastrointestinal bleeding. Acute peritonitis. Diseases of the rectum. Colon diseases. Diseases of the breast. Purulent-inflammatory diseases of the lungs and pleura. Lower limb vein disease	PC -2	test tasks, questions about the module, bank situational tasks, Bank of business games, bank of practical tasks
5.	Acute appendicitis. Complications. cholelithiasish.Acute cholecystitis. Acute pancreatitis. Abdominal hernia. Complications of hernias. Acute intestinal obstruction. Pylorus stenosis. Ulcer penetration. Malignancy. Perforated gastric ulcer and duodenal ulcer. Gastrointestinal bleeding. Acute peritonitis. Diseases of the rectum. Colon diseases. Diseases of the breast. Purulent-inflammatory diseases of the lungs and pleura. Lower limb vein disease	PC -3	test tasks, questions about the module, bank situational tasks, Bank of business games, bank of practical tasks
6.	Acute appendicitis. Complications. cholelithiasish.Acute cholecystitis. Acute pancreatitis. Abdominal hernia. Complications of hernias. Acute intestinal obstruction. Pylorus stenosis. Ulcer penetration. Malignancy. Perforated gastric ulcer and duodenal ulcer. Gastrointestinal bleeding. Acute peritonitis. Diseases of the rectum. Colon diseases. Diseases of the breast. Purulent-inflammatory diseases of the lungs and pleura. Lower limb vein disease	PC -6	test tasks, questions about the module, bank situational tasks, Bank of business games, bank of practical tasks
Вид	Промежуточная аттестация		

контроля	
1	<div> Acute appendicitis. Complications. cholelithiasish.Acute cholecystitis. Acute pancreatitis. Abdominal hernia. Complications of hernias. Acute intestinal obstruction. Pylorus stenosis. Ulcer penetration. Malignancy. Perforated gastric ulcer and duodenal ulcer. Gastrointestinal bleeding. Acute peritonitis. Diseases of the rectum. Colon diseases. Diseases of the breast. Purulent-inflammatory diseases of the lungs and pleura. Lower limb vein disease </div> <div>UC -5</div> <div>bank situational tasks, exam questions, exam tickets</div>
2	<div> Acute appendicitis. Complications. cholelithiasish.Acute cholecystitis. Acute pancreatitis. Abdominal hernia. Complications of hernias. Acute intestinal obstruction. Pylorus stenosis. Ulcer penetration. Malignancy. Perforated gastric ulcer and duodenal ulcer. Gastrointestinal bleeding. Acute peritonitis. Diseases of the rectum. Colon diseases. Diseases of the breast. Purulent-inflammatory diseases of the lungs and pleura. Lower limb vein disease </div> <div>GPC -1</div> <div>bank situational tasks, exam questions, exam tickets</div>
3	<div> Acute appendicitis. Complications. cholelithiasish.Acute cholecystitis. Acute pancreatitis. Abdominal hernia. Complications of hernias. Acute intestinal obstruction. Pylorus stenosis. Ulcer penetration. Malignancy. Perforated gastric ulcer and duodenal ulcer. Gastrointestinal bleeding. Acute peritonitis. Diseases of the rectum. Colon diseases. Diseases of the breast. Purulent-inflammatory diseases of the lungs and pleura. Lower limb vein disease </div> <div>PC -1</div> <div>bank situational tasks, exam questions, exam tickets</div>
4	<div> Acute appendicitis. Complications. cholelithiasish.Acute cholecystitis. Acute pancreatitis. Abdominal hernia. Complications of hernias. Acute intestinal obstruction. Pylorus stenosis. Ulcer penetration. </div> <div>PC -2</div> <div>bank situational tasks, exam questions, exam tickets</div>

	Malignancy. Perforated gastric ulcer and duodenal ulcer. Gastrointestinal bleeding. Acute peritonitis. Diseases of the rectum. Colon diseases. Diseases of the breast. Purulent-inflammatory diseases of the lungs and pleura. Lower limb vein disease		
5	Acute appendicitis. Complications. cholelithiasish.Acute cholecystitis. Acute pancreatitis. Abdominal hernia. Complications of hernias. Acute intestinal obstruction. Pylorus stenosis. Ulcer penetration. Malignancy. Perforated gastric ulcer and duodenal ulcer. Gastrointestinal bleeding. Acute peritonitis. Diseases of the rectum. Colon diseases. Diseases of the breast. Purulent-inflammatory diseases of the lungs and pleura. Lower limb vein disease	PC -3	bank situational tasks, exam questions, exam tickets
6	Acute appendicitis. Complications. cholelithiasish.Acute cholecystitis. Acute pancreatitis. Abdominal hernia. Complications of hernias. Acute intestinal obstruction. Pylorus stenosis. Ulcer penetration. Malignancy. Perforated gastric ulcer and duodenal ulcer. Gastrointestinal bleeding. Acute peritonitis. Diseases of the rectum. Colon diseases. Diseases of the breast. Purulent-inflammatory diseases of the lungs and pleura. Lower limb vein disease	PC -6	bank situational tasks, exam questions, exam tickets

Questions of the module

Questions for module No. 1

1. Acute appendicitis. Classification. Pathological forms. Etiology, pathogenesis. Clinic, diagnosis, differential diagnosis. Features of symptoms depending on the position of the appendix. Features of the course of acute appendicitis in children, pregnant women, and the elderly. Treatment, errors, dangers, complications in the treatment of acute appendicitis. Indications and contraindications for appendectomy. Preparing patients for surgery, managing the postoperative period. Results of surgical treatment.

2. Complications of acute appendicitis (infiltrate, periappendicular abscess, interintestinal, subphrenic, pelvic abscess, pylephlebitis). Clinic of various complications, their diagnosis and treatment. The importance of sanitary educational work among the population and ambulance organizations in reducing complications and mortality in acute appendicitis.

3. Acute cholecystitis. Anatomical and physiological information about the gallbladder and bile ducts. Methodology for examining patients with diseases of the gallbladder and bile ducts.

4. Gallstone disease. Statistical data. Pathogenesis of stone formation. Clinic. Diagnostics. Differential diagnosis. Complications of cholelithiasis. Clinic. Diagnostics.

5. Acute cholecystitis. Classification. Clinic. Complications (empyema of the gallbladder, peri-vesical infiltrate, peri-vesical abscess, peritonitis, fistulas). Differential diagnosis. Diagnostics.

6. Modern principles of conservative and surgical treatment of patients with acute cholecystitis. Preparation for surgery and postoperative management. Work ability examination.

7. Principles of treatment of patients with cholelithiasis. Indications for surgery. Types of surgical interventions used. Intraoperative research methods during operations on the biliary tract. Their significance for choosing the method of operation.

8. Obstructive jaundice. Definition of the concept. Etiology and pathogenesis. Classification. Clinic, diagnosis, treatment

9. Acute pancreatitis. Definition of the concept. Etiology and pathogenesis. Classification. Pathological anatomy. Clinic, periods of progressive pancreatic necrosis. Diagnostics: Ultrasound, laparoscopy, CT, angiography, percutaneous punctures, enzyme diagnostics. Conservative treatment. The role of cytostatics, stylamine. Therapeutic endoscopy, indications for surgical treatment and types of operations. Purulent complications of acute pancreatitis, diagnosis and treatment. Outcomes of the disease.

10. Perforated ulcer of the stomach and duodenum. Definition of the concept. Etiology and pathogenesis. Classification. Clinic, diagnosis, treatment.

11. Gastrointestinal bleeding, penetration, pyloric stenosis. Classification, pathological anatomy, pathogenesis of homeostasis disorders. Gastrointestinal bleeding clinic. Diagnostics, differential diagnosis. Classification according to the severity of blood loss. Conservative and surgical treatment.

12. Mallory-Weiss syndrome. Etiology, clinical picture, diagnosis, surgical treatment.

13. Abdominal hernia. Definition of the concept. Elements of an abdominal hernia. Classification of hernias by origin, localization, course. Frequency of hernias of the anterior abdominal wall. Etiology and pathogenesis. General symptoms of hernias. Diagnostics. Principles of surgical treatment. The main stages of hernia repair surgery. Contraindications for surgery. Prevention of hernia complications.

14. Complications of hernias: inflammation, irreducibility, coprostasis, strangulation. Definition of the concept. Clinic, diagnosis, treatment.

15. Hernia of the white line of the abdomen. Anatomical prerequisites for the formation of a hernia. Clinic, diagnosis, differential diagnosis. Methods of operation.

16. Umbilical hernias. Anatomical prerequisites for the formation of a hernia. Clinic,

diagnosis, differential diagnosis. Surgical treatment: Lexer, Mayo, Sapezhko operations. Features of the treatment of umbilical hernias in childhood.

17. Inguinal hernia. Direct and oblique inguinal hernia (anatomical and clinical differences). Congenital and sliding inguinal hernia. Clinic, diagnosis, differential diagnosis of inguinal hernias. Methods of operations: plastic surgery of the anterior and posterior walls of the inguinal canal (Bassini, Kukudzhanov, McVey-Venglovsky). Plastic surgery with synthetic mesh, videoscopic operations. Features of surgical intervention for congenital and sliding inguinal hernias.

18. Femoral hernia. Anatomy of the femoral canal. Clinic, diagnostics and differential diagnostics. Methods of operations: Bassini, Rugi.

19. Postoperative hernias. Reasons for development. Clinic, diagnostics. Methods of operations. Causes of recurrence of postoperative hernias. Surgery.

20. Anatomical and physiological data of the diaphragm. Classification of diaphragm diseases. Research methods. Etiology, clinical picture, diagnosis, treatment.

21. Strangulated hernia. Definition of the concept. The mechanism of fecal and elastic strangulation. Pathoanatomical changes in the strangulated organ. Types of infringement: retrograde, parietal. Clinic for strangulated hernia. Diagnosis and differential diagnosis. Surgical treatment of strangulated hernias. Features of operational technology; determining the viability of a strangulated intestinal loop. Therapeutic tactics for a questionable diagnosis, spontaneous and forced reduction of a strangulated hernia. Imaginary reduction. False infringement.

22. Intestinal obstruction. Definition of the concept. Classification (by origin, pathogenesis, anatomical localization, clinical course). Methods for studying patients.

23. Congenital intestinal obstruction. Atresia. Pathological anatomy. Pathogenesis. Clinic, diagnosis, differential diagnosis. Principles of surgical treatment.

24. Dynamic (spastic, paralytic) intestinal obstruction. Etiology, pathogenesis. Dynamic intestinal obstruction as a symptom of acute diseases of the thoracic, abdominal and retroperitoneal organs, chronic intoxications. Clinic, differential diagnosis. Principles of treatment.

25. Mechanical intestinal obstruction. Obstructive, strangulation, mixed. Classification of mechanical intestinal obstruction.

26. Obstructive intestinal obstruction. Definition of the concept. Causes, pathogenesis. Features of disturbances of water-electrolyte and acid-base status. Clinic, diagnosis, differential diagnosis. Preoperative preparation and features of surgical treatment.

27. Strangulation intestinal obstruction. Definition of the concept. Classification for etiological reasons. Features of pathogenesis. Clinic of various types of strangulation intestinal obstruction. Diagnostics, differential diagnosis. Types of operations. Indications for intestinal resection.

28. Invagination. Definition of the concept. Types of intussusception. Causes. Pathogenesis. Intussusception as a combination of obstructive and strangulation intestinal obstruction. Clinic, diagnosis, differential diagnosis. Types of operations. Indications for disinvagination and bowel resection.

29. Preoperative preparation and management of the postoperative period in patients with acute intestinal obstruction. Combating intoxication, intestinal paresis, hydroionic disorders, changes in acid-base status.

30. Peritonitis. Definition of the concept. Anatomical and physiological information about the peritoneum. Classification of peritonitis (by clinical course, localization, nature of the effusion, by the nature of the pathogen, by stage).

31. Acute purulent peritonitis. Sources of development of acute purulent peritonitis, features of the spread of infection throughout the abdominal cavity in various acute surgical diseases of the abdominal organs. The role of defense mechanisms in preventing the spread of infection. Pathoanatomical changes in acute purulent peritonitis. Pathogenesis. The significance of impaired absorption from the abdominal cavity, intestinal paresis, intoxication, disturbance of

hydroionic balance and microcirculation in the development of the clinical picture of peritonitis. Clinic, diagnosis, differential diagnosis. The role of laparoscopy. Modern principles of complex treatment. Features of surgical intervention, indications for drainage, programmed lavages, the role of antibiotics in complex treatment, combating hemodynamic and microcirculation disorders, hydroionic disorders, intoxication and intestinal paresis in the postoperative period. Treatment outcomes. The role of emergency care in the early diagnosis and treatment of peritonitis.

32. Limited peritonitis (subhepatic, subdiaphragmatic abscess, Douglas pouch abscess, interintestinal abscesses). The causes of their occurrence, clinic, diagnosis, treatment.

33. Gynecological peritonitis. Clinic, diagnosis, treatment.

34. Tuberculous peritonitis. Classification (by flow, by morphological forms). Clinic, diagnosis and treatment of various forms.

Questions for module No. 2

1. Diseases of the breast. Anatomical and physiological information about the mammary gland. Classification of diseases. Methods for studying patients with breast diseases. Acute purulent mastitis. Clinic, diagnosis, treatment. Mastopathy.

Benign and malignant tumors.

2. Diseases of the esophagus. Anatomy-physiological information. Classification of diseases of the esophagus and diaphragm. Research methods (fluoroscopy, radiography, esophagoscopy, pneumomediastinography, X-ray cinematography, radioisotope diagnostics).

3. Congenital developmental anomalies. Foreign bodies of the esophagus. Achalasia cardia. Classification. Clinic, diagnosis, differential diagnosis. Principles of treatment, cardiodylation using a pneumatic cardiodylator. Indications for surgical treatment, principles of operations.

4. Cardiac failure and reflux esophagitis. Pathogenesis, clinical picture, diagnosis and indications for surgical treatment. Principles of surgical treatment.

5. Esophageal diverticula. Classification. Clinic, diagnosis, treatment.

6. Chemical burns and cicatricial narrowing of the esophagus. Pathogenesis. Acute clinic. First aid and principles of treatment in the acute period. Early and late bougienage.

7. Clinic of cicatricial narrowing of the esophagus, localization and forms of narrowing. Diagnostics. Bougienage treatment. Surgery.

8. Benign and malignant tumors of the esophagus.

9. Vein diseases. Classification. Developmental defects (Parks disease, Weber disease, Klippel/Trenaunay disease). Clinic, diagnosis, treatment. Varicose veins of the lower extremities. Etiology, pathogenesis (the role of constitutional features, connective tissue, muscular-venous pump, arteriovenous shunts, etc.), pathological anatomy. Clinic of the disease depending on the stage of the disease. Diagnostics. Methods for determining the patency of deep veins, assessing the condition of the valve apparatus of superficial and communicating veins (functional tests, contrast venography, ultrasound angioscanning, phleboscintigraphy). Treatment: surgery, sclerosing therapy. Indications and contraindications for surgery. Types of operations and methods of ligation of communicating veins. Endoscopic dissection of communicating veins. Management of the postoperative period. Causes of recurrence of varicose veins.

10. Complications of varicose veins of the lower extremities: acute thrombophlebitis, bleeding, trophic ulcer. Clinic, diagnosis, treatment.

11. Acute thrombosis of the inferior vena cava system. Classification of localization (thrombosis of deep veins of the leg, femoral vein, iliofemoral segment with and without transition to the inferior vena cava). Etiology and pathogenesis of venous thrombosis. Clinic of acute venous thrombosis depending on the location and extent of thrombosis. Diagnostics: ultrasound angioscanning, contrast venography. The role of ilio-cavography in the diagnosis of common thrombosis. Treatment is conservative: the use of anticoagulants, nonspecific anti-

inflammatory drugs, antiplatelet agents. Surgical treatment, indications and contraindications. Methods of surgery: thrombectomy, vein ligation, plication of the inferior vena cava, implantation of a vena cava filter. Prevention of phlebothrombosis.

12. Complications of acute venous thrombosis: venous gangrene of the limb, pulmonary embolism. Venous gangrene of the limb, pathogenesis, clinical picture, diagnosis and differential diagnosis. Principles of conservative treatment. Indications for limb amputation.

13. Pulmonary embolism. Causes of the development of the disease, clinical picture and diagnosis (radiography of the lungs, radioisotope scanning, angiopulmonography in combination with registration in the right side of the heart, retrograde ilio-cavography). Treatment (use of antithrombotic and thrombolytic agents). Indications for embolectomy.

14. Postthrombophlebitic disease of the lower extremities. Definition of the concept. Pathogenesis. Classification: varicose, edematous-painful, ulcerative and mixed forms. Clinic of various forms of the disease. Special diagnostic methods. Conservative treatment. Indications for surgery and types of surgical interventions.

15. Paget-Schretter syndrome. Causes of development of subclavian vein thrombosis. Clinic, diagnosis and treatment.

16. Insufficiency of the lymphatic system. Classification of lymphostasis. Clinic, diagnostic methods, surgical treatment. Creation of lymphovenous anastomoses using microsurgical techniques. Chyloperitoneum. Chylothorax. Indications for drainage of the thoracic lymphatic duct.

Exam questions

1. Acute abscess and gangrene of the lung. (Classification, etiology, clinic, diagnosis, treatment).
2. Acute appendicitis (Clinic, differential diagnosis, treatment).
3. Obstructive intestinal obstruction. (Etiology, pathogenesis, clinic, diagnostics).
4. Features of surgical treatment of acute purulent peritonitis.
5. Injuries of esophagus. (Classification of injuries, clinic, diagnostics treatment).
6. Invaginational intestinal obstruction. (Clinic, diagnosis, differential diagnosis).
7. Peptic ulcer of the stomach and duodenum. (Etiology, pathogenesis, pathological changes, stages of ulcerative development disease).
8. Abdominal hernias. (Definition, elements of a hernia of the abdomen, classification, etiology, pathogenesis).
9. Mechanical intestinal obstruction. (Etiology, pathogenesis, clinical features, differential diagnosis).
10. Modern principles of the complex treatment of acute purulent peritonitis.
11. Mellory-Weiss syndrome. (Etiology, clinic, diagnosis, treatment),
12. Postoperative hernia. (Etiology, cynics, diagnostics, methods of operations).
13. Classification of breast diseases. Methods of examination of patients with breast diseases.
14. Pyopneumothorax. (Etiology, valvular and intense pneumothorax, diagnosis and treatment).
15. Symptomatic ulcers. (Hormonal and drug, syndrome Zollinger-Ellison, etiology, pathogenesis, clinic, treatment).
16. Hernias of the white line of the abdomen. (Clinic, diagnostics, methods of operations).
17. Foreign bodies of the esophagus. (Diagnosis, treatment).
18. Strangulated intestinal obstruction. (Etiology, clinic, diagnostics).
19. Bronchiectatic disease. (Etiology, pathogenesis, classification, treatment)
20. Appendicular infiltrate. (Definition, differential diagnosis, treatment).
21. Cicatricial deformities of the stomach and duodenum. (Clinic, diagnosis, treatment).
22. Femoral hernias. (Etiology, clinic, diagnostics, methods of operations).
23. Esophagospasm and achalasia. (Definition of concepts, clinic, diagnostics, treatment methods - conservative, surgical).
24. Paraproctitis and pararectal fistula. (Etiology, pathogenesis, classification, clinic, diagnosis, treatment).
25. Acute purulent pleurisy. (Definition, classification by etiological factor, clinic, diagnosis, treatment).
26. Surgical tactic about obscure forms of appendicitis.
27. Comprehensive treatment of acute pancreatitis.
28. Varicose veins of the lower extremities. (Classification, etiology pathogenesis)
29. Fistulas of the pancreas. Etiology, diagnosis, differential diagnosis, treatment.
30. Clinic of thrombophlebitis of superficial and deep veins. (diagnostics, differential diagnosis).
31. Differential diagnosis of acute pancreatitis.

32. Methods for determining venous patency, assessment of the state of the valvular apparatus and communicative veins.
33. Pancreatic cysts. (Classification, etiology, treatment, diagnosis, treatment.)
34. Thrombophlebitis of the lower extremities. (Definition. Classification Etiology).
35. Congenital malformations of the esophagus. (Classification, diagnosis, treatment.).
36. Diseases of the rectum.
37. Chemical burn of the esophagus. (Clinic, diagnosis, treatment).
38. Dyshormonal diseases of the breast - mastopathy, (causes, classification, diagnosis, treatment).
39. Benign tumors of the esophagus. (Clinic, diagnosis, treatment),
40. Hemorrhoids. (Definition, classification, etiology, pathogenesis, treatment).
41. Regime and rehabilitation of patients after acute pancreatitis.
42. Conservative and surgical methods for the treatment of post-thrombophlebitis syndrome.
43. Research methods for patients with diseases of the liver, gall bladder and bile ducts.
44. Clinical forms of obliterating atherosclerosis. (Lerish's syndrome, occlusion of the femoral and popliteal arteries. Clinic of various forms).
45. Methods of examination of patients with intestinal obstruction.
46. Acute purulent peritonitis, sources of its development, prevention, treatment.
47. Obstruction of the common bile duct. (Cholelithiasis, cicatricial strictures tumors, clinic, diagnosis).
48. Obliterating thrombophlebitis. Etiology, pathogenesis. Flow patterns diseases. Clinic, stages of the disease. Principles of conservative treatment.
49. Intestinal obstruction. Definition of a concept. Classification by origin, pathogenesis of anatomical localization, clinical adrift.
50. Peritonitis. Classification of peritonitis (according to the clinical course, localization, the nature of the effusion, according to the stage.).
51. The importance of laboratory research methods for diseases of the pancreas.
52. Postthrombophlebitis syndrome. Definition of a concept. Classification, pathogenesis, treatment.
53. Dynamic intestinal obstruction. (Etiology, pathogenesis and treatment),
- 54.. Pathological and anatomical changes in acute purulent peritonitis.
55. Perforated ulcer of the stomach and duodenum. (Clinic, diagnosis, treatment).
56. Complications of hernias. Types of entrapments .
57. Bleeding ulcer of the stomach and duodenum (Clinic, diagnosis, classification, pathogenesis of disorders, treatment).
58. A strangulated hernia. Definition. The mechanism of fecal and elastic entrapments.

59. Complications of acute pancreatitis. (Abscess, pancreatic fistula, false cyst, peritonitis).
60. Treatment of varicose disease. (Surgical, conservative treatment).

BANK SITUATION TASKS

Example of a situational task №1

A 60-year-old patient was hospitalized in the surgical department 6 days after the onset of pain in the right iliac region. The patient's condition is satisfactory. Temperature - 37.2 °. There was no chill. On palpation of the abdomen - pain in the right iliac region, where the compaction is determined by the size of 7 × 8 cm with fuzzy borders, painful. Symptom Shchetkina-Blumberg weakly positive. Symptoms of Rowzing and Sitkovsky are positive. According to the patient, over the past 6 months, there has been a slight increase in constipation. Leukocytosis - $10.2 \times 10^9 / L$

- 1) What is your presumptive diagnosis?
- 2) What disease should be excluded?
- 3) Is emergency surgery indicated?
- 4) Your medical tactics and examinations?

Answer

- 1) Acute appendicitis, appendicular infiltrate.
- 2) Cancer of the cecum.
- 3) No.
- 4) Conducting conservative anti-inflammatory therapy. When resorption of the infiltrate, an examination is necessary - irrigoscopy or colonoscopy. Then the operation in a planned manner for chronic appendicitis (appendectomy) after 3 months. When the abscessing clinic appears, an emergency operation is indicated - opening and draining the abscess.

Example of a situational task №2

A 52-year-old patient complains of periodically appearing paroxysmal pains in the right hypochondrium with radiation to the right shoulder and shoulder blade with an increase in body temperature up to 39-39.5 °C, heavy sweats during the last year. Over the past month, such attacks have become more frequent and began to appear every 2-3 days. Sometimes attacks were accompanied by the appearance of jaundice, which quickly disappeared, and then reappeared. General condition remained satisfactory. She noted some weakness. The abdomen is of normal shape, soft. The liver is not enlarged. The gall bladder is not palpable. Soreness on palpation in the epigastric region. White blood cells 9.2×10^3 in 1 μl , ESR 38 mm / h. With ultrasound, the gallbladder is of normal size, contains calculi, there is dilatation of the intrahepatic ducts, choledoch 1.2 cm.

- 1) What diagnosis do you make?
- 2) What is the tactics of additional examination and treatment?

Answer

- 1) There is a complication of gallstone disease - cholangitis.
- 2) Performing ERCP and EPST to eliminate the causes of cholangitis - choledocholithiasis and / or BDS stenosis, after which cholecystectomy is necessary

Example of a situational task №3

A patient with fatty pancreatic necrosis on the 5th day from the onset of the disease in the epigastric region began to determine a dense, moderately painful, without clear boundaries infiltration. Against the background of the conservative therapy, it slightly decreased in size, but by the third week of the disease the pain intensified, hectic temperature appeared, and tachycardia increased. On examination: the patient's condition is severe, the skin is pale. Pulse 96 per minute, blood pressure - 120/80 mmHg The tongue is dry. The abdomen is swollen, soft, in the epigastrium, a painful tumor formation is determined up to 10 cm in diameter; peritoneal symptoms are negative, peristalsis is audible. Blood test: Hb - 105 g / l, leukocytes - $18 \times 10^9 / l$, eos. 3, p / a - 29, s / I - 52, mon - 8, lymph - 8, ESR 48 mm / hour .

- 1) What is your presumptive diagnosis?
- 2) What additional studies can clarify the diagnosis?
- 3) What is your treatment tactic?

Answer

- 1) Abscess of the stuffing bag.
- 2) Ultrasound of the pancreas, depending on the pathology found, puncture. If possible, computed tomography.
- 3) When confirming the diagnosis, puncture and drainage under ultrasound control are indicated.

Business game on the topic “Hernia of the abdomen”

Imitation of a real diagnostic and treatment situation - establishing a diagnosis and determining treatment tactics.

Students perform the following roles:

- patient
- relatives of the patient
- emergency surgeon
- surgeon at the emergency department
- LD doctor
- ultrasound doctor
- radiologist
- endoscopist
- chief physician
- nursing and junior medical personnel

The rest of the students are actively working from the spot, discussing and forming a public opinion about what is happening.

The game is moderated by the teacher.

During the game, great importance is attached to ethics and deontology in the work of doctors of various specialties, in communication with the patient, his relatives, and nursing staff.

Students examine the “patient,” answer his questions, make a diagnosis and determine treatment tactics.

The main goal of the game is to establish the correct diagnosis and determine the correct

treatment tactics while observing all the norms of ethics and deontology.

Business game on the topic "Acute pancreatitis."

Imitation of a real diagnostic and treatment situation - establishing a diagnosis and determining treatment tactics.

Students perform the following roles:

- patient
- relatives of the patient
- emergency surgeon
- surgeon at the emergency department
- LD doctor
- ultrasound doctor
- radiologist
- endoscopist
- chief physician
- nursing and junior medical personnel

The rest of the students are actively working from the spot, discussing and forming a public opinion about what is happening.

The game is moderated by the teacher.

During the game, great importance is attached to ethics and deontology in the work of doctors of various specialties, in communication with the patient, his relatives, and nursing staff.

Students examine the "patient," answer his questions, make a diagnosis and determine treatment tactics.

The main goal of the game is to establish the correct diagnosis and determine the correct treatment tactics while observing all the norms of ethics and deontology.

PRACTICAL TASK ON THE TOPIC " ACUTE PANCREATITIS "

Students are given a patient according to the topic of the lesson.

The student must independently collect complaints, anamnesis, objective data and establish a preliminary diagnosis (according to modern classifications), determine an examination plan and a treatment plan. At the same time, strictly observing the rules of ethics and deontology in communication with the patient and medical personnel.

The student writes the results of the work in the form of a short essay:

Full name of the student, group, faculty.

Patient's name, room number.

Based on complaints (...), anamnesis (...), objective data (...) a preliminary diagnosis (...) was made.

Examination plan:

1. ...

Treatment plan:

1. Mode (...).

2. Table (...).

3. ...

Note: All drugs with dosage and route of administration.

The purpose of the practical task is to establish the correct diagnosis and determine the correct treatment tactics while observing all the norms of ethics and deontology.

For each practical task, the teacher conducts a collective analysis (with the whole group), identifying errors and evaluating the work.

PRACTICAL TASK

ON THE TOPIC " DISEASES OF THE RECTUM "

Students are given a patient according to the topic of the lesson.

The student must independently collect complaints, anamnesis, objective data and establish a preliminary diagnosis (according to modern classifications), determine an examination plan and a treatment plan. At the same time, strictly observing the rules of ethics and deontology in communication with the patient and medical personnel.

The student writes the results of the work in the form of a short essay:

Full name of the student, group, faculty.

Patient's name, room number.

Based on complaints (...), anamnesis (...), objective data (...) a preliminary diagnosis (...) was made.

Examination plan:

1. ...

Treatment plan:

1. Mode (...).

2. Table (...).

3. ...

Note: All drugs with dosage and route of administration.

The purpose of the practical task is to establish the correct diagnosis and determine the correct treatment tactics while observing all the norms of ethics and deontology.

For each practical task, the teacher conducts a collective analysis (with the whole group), identifying errors and evaluating the work.

ЛД -21ИИ

State budgetary educational institution of higher professional education
"North Ossetian State Medical Academy" of the Ministry of health of the Russian
Federation

Department of Surgery Diseases №2

Test Job Benchmarks

by discipline « Faculty Surgery »

the main professional educational program of higher education - a specialty program in
the specialty 31.05.01 Medical affairs, approved by 24.05.2023.

For students of the 4 th year

by specialty 31.05.02 General Medicine

Incoming control of the level of training of students

1. In a patient operated on acute phlegmonous appendicitis and diffuse peritonitis through an approach in the right iliac area right-sided subdiaphragmatic abscess was diagnosed. What was the possible reason of its formation? 1. A patient didn't take Trendelenburg's position after the surgery 2. A patient didn't take Fowler's position after the surgery 3. The wrong approach had been chosen, inferomedian laparotomy had to be performed 4. Exudate in the abdominal cavity hadn't been drained 5. Tamponade of the abdominal cavity hadn't been performed

- a) 1, 3, 5
- b) 1 and 4
- c) 1 and 5
- +d) 2, 3, 4
- e) 2, 3, 5

2. Which of the following methods are not used for abscesses detection in the abdominal cavity? 1. Ultrasonic scanning 2. Plan radiography of the abdominal cavity 3. Colonoscopy 4. Computer tomography 5. Laparoscopy

- a) 1, 3, 5
- b) 2, 4
- +c) 3, 5
- d) 2, 4, 5
- e) 1, 5

3. In 76-year-old patient with transmural myocardial infarction phlegmonous appendicitis was detected. What are your actions?

- +1. Emergency surgery
- 2. Observation and surgery in case of peritonitis symptoms
- 3. Indication of massive doses of antibiotics and surgery in case of ineffective antibioticotherapy
- 4. Laparoscopy, in case of diagnosis confirmation - surgery
- 5. All variants are wrong

4. In complication of acute appendicitis with appendicular infiltrate conservative therapy is indicated because: 1. Self-recovery is possible 2. Infiltrate resorption is possible 3. In attempt to carry out appendectomy small bowel perforation is possible 4. After infiltrate resorption the mild case of the disease is chronic appendicitis 5. In attempt to expose the vermiform appendix from the infiltrate peritonitis can develop Choose the right answer combination:

- a) 1, 3
- b) 2, 4
- c) 1, 2, 3
- d) 3 and 5
- +e) All variants are correct

5. In differentiation of subdiaphragmatic abscess from right-sided lower lobe pneumonia the most evident sign for establishing the diagnosis is: 1. Restriction of motions of the right cupula of diaphragm in chest radiography 2. Superhepatic liquid in a plan radiography of the abdominal cavity 3. Presence of pus in puncture of the pleural cavity 4. Presence of pus in puncture of subdiaphragmatic area 5. Fluoroscopic picture: shadowing of the lower lobe of the right lung Choose the right answer combination:

- a) 1, 3, 5
- +b) 1, 2, 4
- c) 1, 2, 5
- d) 2, 3, 4
- e) 2, 4, 5

6. At the primary stage of large intestinal obturation obstruction the following therapeutic approach is reasonable:

1. Emergency surgery, allowing to prevent intestinal necrosis and perforation
2. Surgery within 48-72 hours after examination and detection of the obstruction reasons
3. Emergency surgery - double barrel colostomy or enterostomy
- +4. Conservative measures. In absence of the effect emergency surgery should be performed
5. All the listed variants are correct

7. Factors, promoting the development of strangulated intestinal obstruction are: 1. Long narrow mesentery 2. Commissural process in the abdominal cavity 3. Comissuring of Meckel's diverticulum with mesentery 4. Alcohol intake 5. Intake of roasted food Choose the right answer combination:

- +a) 1, 2, 3
- b) 1, 4, 5
- c) 2, 3, 4
- d) 2, 4, 5
- e) All variants are correct

8. What is developed in the early period of acute small bowel obstruction? 1. Hyperkalemia 2. Dehydration 3. Hematocrit reduction 4. Hematocrit increase 5. hypokalemia Right variants:

- a) 1, 2, 3
- b) 1, 3, 5
- +c) 2, 4, 5
- d) 2, 3, 5
- e) 1, 4, 5

9. Following symptoms are pathognomic for obturation intestinal obstruction: 1. Constant abdominal pains 2. Colicky abdominal pains 3. Coffee-grounds vomiting 4. Abdominal distension 5. Recession of epigastric area Choose the right answer combination:

- +a) 2, 4
- b) 1, 4
- c) 1, 3, 5
- d) 2, 3, 5
- e) 2, 3, 4

10. What are the deciding examination techniques for acute intestinal obstruction diagnosing? 1. Plain roentgenoscopy of abdominal cavity 2. Examination of barium passage along the gastrointestinal tract 3. Esophagogastroduodenoscopy 4. Laparoscopy 5. Biochemical blood analysis Choose the right answer combination:

- a) 1, 2, 3
- b) 2, 4, 5
- +c) 1 and 2
- d) 2 and 3
- e) 1, 4, 5

11. Normally, an adult's abdominal cavity contains serous fluid of:

- +1. 20 ml
2. 80 ml
3. 120 ml
4. 200 ml
5. 220 ml

12. Hemorrhagic exudate in the abdominal cavity is not observed in:

1. Acute pancreatitis
- +2. Acute cholecystitis
3. Mesenteric vessels thrombosis
4. Mesenteric vessels embolism
5. Intestinal obstruction

13. Onset of acute peritonitis is accompanied by abdominal pains in:

1. 50% of patients
2. 50-75% of patients
3. 75-90% of patients
- +4. 100% of patients

14. Onset of acute peritonitis is accompanied by tension of abdominal muscles in:

1. 15-25% of patients
2. 35-50% of patients
- +3. 85-90% of patients
4. 100% of patients

15. Free gas in abdominal cavity in perforation of hollow organs occurs in:

1. 20-40% of patients
- +2. 60-75% of patients
3. 100% of patients

16. What is not used to reduce throes in acute pancreatitis?

1. Vagosympathetic block
2. Peridural anesthesia
3. Paraneuritic block
4. Block of round ligament of liver
- +5. Morphine

17. Exposure of haemorrhagic exudates into the abdominal cavity and foci of fat necrosis on the peritoneum points to:

1. Damage of the hollow organ
2. Liver rupture
- +3. Acute pancreatitis
4. Perforated stomach ulcer
5. Mesenteric thrombosis

18. The most common symptom of acute pancreatitis is:

1. Nausea and vomiting
2. Hyperthermia
3. Jaundice
4. Bloating
- +5. Pains in the upper part of the abdomen

19. Postnecrotic complications of acute pancreatitis are:

1. Pancreatic shock
2. Acute hepatic insufficiency
- +3. Omentum bursa abscess
4. Pancreatogenous pancreatitis
5. Haemorrhagic pancreatitis

20. What does not take part in pathogenesis of acute pancreatitis?

1. Enterokinase
2. Elastase
3. Phospholipase
4. Trypsin
- +5. Streptokinase

21. Following are disorders of the pharyngo-oesophageal junction except:

1. Stroke
2. Myasthenia
3. Cricopharyngeal achalasia
- +4. Nutcracker oesophagus

22. Following are true for oesophageal lymphatics except:

1. Extensive lymphatic plexus in the submucosa
2. They are classified as perioesophageal, paraesophageal and lateral oesophageal lymph nodes
3. Presence of coeliac nodes indicate inoperability
- +4. Longitudinal lymphatics are 6 times less than transverse

23. Which one of the following is highest percentage of premalignant condition or carcinoma oesophagus?

- +1. Tylosis
2. Lye strictures
3. Achalasia
4. Oesophagus

24. Factors of adenocarcinoma oesophagus are following except:

1. Barrett's oesophagus
2. Obesity
3. Reflux esophagitis
- +4. Oesophageal web

25. Factors for development of reflux disease of oesophagus include following except:

1. Obesity
2. Absence of intra-abdominal length of oesophagus
- +3. Helicobacter pylori infection
4. Defective angle of His

26. In terms of location, gastrointestinal (GI) bleeding is generally classified as which of the following?

- +1. Upper and lower
2. Internal and external
3. Acute and chronic

4.hematemesis and hematochezia

27.Upper gastrointestinal bleeding may be caused by all of the following conditions EXCEPT:

- 1.Mallory-Weiss tear (tears where the esophagus joins the stomach)
- 2.Gastritis
- +3Colitis
- 4.peptic ulcers

28.What is the most common cause of upper gastrointestinal bleed?

- 1.Cancers
- +2peptic ulcers
- 3.Esophagitis
- 4.fistulas

29.Which of the following conditions is NOT a cause of lower gastrointestinal bleeding?

- 1.colorectal cancer
- 2.Hemorrhoids
- 3.esophageal varices
- +4diverticular disease

30.Which of these listed is the medical term for vomiting of blood?

- +1.hematochezia
- 2.hematuria
- 3.hematemesis
- 4.hemoptysis

Acute appendicitis. Complications

1.In a patient operated on acute phlegmonous appendicitis and diffuse peritonitis through an approach in the right iliac area right-sided subdiaphragmatic abscess was diagnosed. What was the possible reason of its formation?1. A patient didn't take Trendelenburg's position after the surgery 2. A patient didn't take Fowler's position after the surgery 3. The wrong approach had been chosen, inferomedian laparotomy had to be performed 4. Exudate in the abdominal cavity hadn't been drained 5. Tamponade of the abdominal cavity hadn't been performed

- a) 1, 3, 5
- b) 1 and 4
- c) 1 and 5
- +d) 2, 3, 4
- e) 2, 3, 5

2.Which of the following methods are not used for abscesses detection in the abdominal cavity?1. Ultrasonic scanning 2. Plan radiography of the abdominal cavity 3. Colonoscopy 4. Computer tomography 5. Laparoscopy

- a) 1, 3, 5
- b) 2, 4
- +c) 3, 5
- d) 2, 4, 5
- e) 1, 5

3. In 76-year-old patient with transmural myocardial infarction phlegmonous appendicitis was detected. What are your actions?

- +1. Emergency surgery
- 2. Observation and surgery in case of peritonitis symptoms
- 3. Indication of massive doses of antibiotics and surgery in case of ineffective antibioticotherapy
- 4. Laparoscopy, in case of diagnosis confirmation - surgery
- 5. All variants are wrong

4. In complication of acute appendicitis with appendicular infiltrate conservative therapy is indicated because: 1. Self-recovery is possible 2. Infiltrate resorption is possible 3. In attempt to carry out appendectomy small bowel perforation is possible 4. After infiltrate resorption the mild case of the disease is chronic appendicitis 5. In attempt to expose the vermiform appendix from the infiltrate peritonitis can develop Choose the right answer combination:

- a) 1, 3
- b) 2, 4
- c) 1, 2, 3
- d) 3 and 5
- +e) All variants are correct

5. In differentiation of subdiaphragmatic abscess from right-sided lower lobe pneumonia the most evident sign for establishing the diagnosis is: 1. Restriction of motions of the right cupula of diaphragm in chest radioscopy 2. Superhepatic liquid in a plan radiography of the abdominal cavity 3. Presence of pus in puncture of the pleural cavity 4. Presence of pus in puncture of subdiaphragmatic area 5. Fluoroscopic picture: shadowing of the lower lobe of the right lung Choose the right answer combination:

- a) 1, 3, 5
- +b) 1, 2, 4
- c) 1, 2, 5
- d) 2, 3, 4
- e) 2, 4, 5

6. You suspect Douglas abscess in a patient. What examinations should be carried out for its diagnosing? 1. Proctoscopy 2. Digital investigation of the rectum 3. Ultrasonography 4. Laparoscopy 5. Plan radiography of the abdominal cavity Choose the right answer combination:

- a) 1, 3, 5
- b) 2, 4, 5
- +c) 2, 3
- d) 3, 4
- e) 1, 5

7. A 23-year-old patient with 32 weeks of pregnancy has been staying at a surgery department for 18 hours. Case follow-up can't exclude acute appendicitis. What is your therapeutic approach?

- +1. A patient should be operated
- 2. Continue supervision of a patient
- 3. Ultrasonography of abdominal cavity
- 4. To bring on induced termination of pregnancy together with gynecologist
- 5. Perform laparoscopy and surgery if diagnosis is approved

8. Douglas abscess after appendectomy is characterized by following signs: 1. Hectic temperature 2. Pains deep in the pelvis and tenesmus 3. Limited diaphragm mobility 4. Overhanging vaginal walls or anterior walls of the rectum 5. Muscles tension of the anterior abdominal wall Choose the right answer combination:

- a) 1, 3, 5
- +b) 1, 2, 4
- c) 1, 3, 4
- d) 2, 3, 4
- e) 2, 3, 5

9. Emergency appendectomy is not indicated in:

- 1. Acute catarrhal appendicitis
- 2. Acute appendicitis in late pregnancy
- 3. The first attack of acute appendicitis
- +4. Obscure diagnosis of acute appendicitis in elderly patients
- 5. Acute appendicitis in children

10. Symptoms of appendicular infiltrate are following except:

- 1. Low grade fever
- 2. Disease duration of 4-5 days
- +3. Intractable diarrhea
- 4. Increased level of blood leukocytes
- 5. Palpable tumor-like mass in the right iliac area

11. Local painfulness reduced in a patient 5 days after appendectomy, but he felt worsening of general condition: temperature increase, its hectic character, increase of leukocytes level. Moderate pains appeared deep in the pelvis as well as transient dysuric symptoms, tenesmus. What additional examination technique will you indicate to find out the reasons of such clinical representation?

- 1. Pyromocystoscopy
- 2. Repeated blood and urine tests
- +3. Digital rectal examination
- 4. Proctoscopy
- 5. Control irrigoscopy

12. The reason of wound abscess after appendectomy is:

- 1. Fecal fistula
- +2. Wound infection during a surgery
- 3. Actinomycosis
- 4. Blind gut cancer
- 5. Foreign body (tissue)

13. Abdominal cavity tamponade after appendectomy due to acute appendicitis is not indicated in:

- 1. Unstopped capillary bleeding
- 2. Uncertainty in total removal of impacted feces, fallen out of the ruptured vermiform appendix
- +3. Turbid exudates in the right iliac area
- 4. Uncertainty in adequate appendix stump immersion
- 5. Leaving of the appendix tip in the wound in retrograde appendectomy

14. What symptoms are characteristic of gangrenous form of acute appendicitis? 1. «Wooden belly» 2. Sudden pains increase in the right iliac area 3. Reduction of pain sensation 4. Tachycardia 5. Blumberg's sign in the right iliac area
Choose the right answer combination:

- a) 1, 2, 5
- +b) 3, 4, 5
- c) 1, 4, 5
- d) 2, 3
- e) 2, 5

15. Tamponade of the right iliac fossa after appendectomy is indicated in: 1. Vermiform appendix gangrene 2. Retrocecal location of the vermiform appendix 3. Capillary bleeding from the tissues in the area of the vermiform appendix location 4. Suspected appendix tip avulsion in its retrograde removal 5. Impacted feces dropping during the vermiform appendix exposure Choose the right answer combination:

- a) 1, 2, 3
- b) 2, 3, 4
- +c) 3, 4, 5
- d) 1, 4, 5
- e) All variants are correct

16. The most important symptoms of abscess in differential diagnosing of subdiaphragmatic abscess from right-sided pneumonia of the lower lobe are: 1. Limitation of the right diaphragm cupula mobility in chest radiography 2. Superhepatic liquid level in plan radiography of the abdominal cavity 3. Pus in puncture of the pleural cavity 4. Pus in puncture of subdiaphragmatic area 5. Shadowing of the lower lobe of the right lung in chest radiography Choose the right answer combination:

- a) 1, 3, 4
- +b) 1, 2, 4
- c) 1, 2, 5
- d) 2, 3, 4
- e) 3, 4, 5

17. Pylephlebitis development is most probable in one of the following forms of acute appendicitis:

- 1. Appendicular colic
- 2. Catarrhal appendicitis
- 3. Phlegmonous appendicitis
- 4. Phlegmonous appendicitis, accompanied by vermiform appendix mesentery inflammation
- +5. Primary gangrenous appendicitis

18. What method would you choose to diagnose Douglas abscess?

- 1. Proctoscopy
- 2. Laparoscopy
- 3. Percussion and auscultation of the abdomen
- +4. Digital rectal investigation
- 5. Abdominal cavity radiography

19. What measures would you take to differentiate acute appendicitis from right-sided renal colic? 1. Spasmolytics injection 2. Narcotics injection 3. Urgent urine test 4. Chromocystoscopy 5. Renal arteries angiography Choose the right answer combination:

- a) 1, 3, 5
- b) 2, 3, 4
- c) 3, 4, 5
- +d) 1, 3, 4

e) All variants are correct

20. Following features are characteristic of perforated appendicitis: 1. Free gas in the abdominal cavity 2. Reduction of volume of circulating erythrocytes 3. Sudden pains increase in the abdomen 4. Muscle tension of the anterior abdominal wall 5. Positive Blumberg's sign Choose the right answer combination:

a) 1, 2, 3

b) 2, 4, 5

+c) 3, 4, 5

d) 1, 4, 5

e) All variants are correct

21. Abscess of the small pelvis developed in an 18-year-old patient 7 days after appendectomy. What would you undertake?

1. Massive antibiotic therapy

2. Open the abscess through inferomedian approach and drain the small pelvis

3. Open the abscess through the right iliac area

+4. Drain the abscess through the anterior wall of the rectum

5. Open the abscess through right-sided extra-abdominal approach

22. In a 40-year-old patient 2 days after appendectomy due to gangrenous appendicitis enteroparesis, shivering, pains in the right side of the abdomen and jaundice developed, the liver became enlarged. Symptoms of peritoneum are absent. What complication should be suspected first?

1. Peritonitis

2. Subdiaphragmatic abscess

3. Interintestinal abscess

+4. Pylephlebitis

5. Subhepatic abscess

23. Phlegmon of the retroperitoneal space as a complication of acute appendicitis develops in:

1. Anterior subhepatic vermiform appendix location

2. Local peritonitis in the right iliac area

+3. Retroperitoneal location of the vermiform appendix

4. Medial location of the vermiform appendix

5. Lateral location of the vermiform appendix from the blind gut

24. Opening of the subdiaphragmatic abscess is performed through: 1. P• horacolaparotomy 2. Lumbotomy 3. Two-staged transpleural approach 4. Fedorov's laparotomy in the right hypochondrium 5. Extrapleural extraperitoneal approach Choose the right answer combination:

a) 1, 2, 3

b) 1, 4, 5

c) 2, 3, 5

+d) 3, 4, 5

e) All variants are correct

25. During the surgery on acute appendicitis appendicular infiltrate was detected. What tactic solution should be taken?

1. Carry out diagnostic puncture of the infiltrate

- +2. Refuse further manipulations and suture the incisional wound tight
- 3. Bound the inflamed infiltrate with gauze tampons
- 4. Drain the abdominal cavity
- 4. Expose the vermiform appendix from the infiltrate and perform appendectomy

26. In treatment of diffuse peritonitis of appendicular origin first it is necessary to:

- 1. Elimination of peritonitis source
- 2. Antibacterial therapy
- 3. Correction of water-electrolyte disorders
- 4. Abdominal cavity sanitation
- +4. All variants are correct

27. What can develop before or after appendectomy? 1. Appendicular infiltrate 2. Diffuse peritonitis 3. Periappendicular abscess 4. Local abscess of abdominal cavity 5. Retroperitoneal phlegmon

- a) 1, 2, 3, 4
- b) 1, 3, 5
- +c) 2, 4, 5
- d) 3, 4, 5
- e) 2, 3, 4, 5

28. Perforation of the vermiform appendix exposes in: 1. The sharpest pain in the iliac area, especially evident together with subsided imaginary pains in gangrene development 2. Abdominal wall tension first in the right iliac area and then spreading to other areas 3. Increasing abdominal distension 4. Leukocytosis 5. Lowering of the body temperature Right variants:

- +a) 1, 2, 3, 4
- b) 2, 3, 4, 5
- c) 1, 2, 3, 5
- d) 1, 3, 4, 5
- e) 1, 2, 4, 5

29. In acute appendicitis and perforated ulcer following symptoms can be observed: 1. Volkovich-Kocher's sign 2. Spizharniy's symptom 3. Blumberg's sign 4. Voskresensky's symptom 5. Krymov's symptom

- +a) 1, 2, 3, 4
- b) 1, 2, 4, 5
- c) 1, 2, 3, 5
- d) 1, 3, 4, 5
- e) 2, 3, 4, 5

30. Following measures help to differentiate acute appendicitis from perforated ulcer: 1. Thoroughly gathered and correctly interpreted close and remote anamnesis 2. Plain abdominal cavity X-ray picture 3. Selective celiacography 4. Laparoscopy 5. Laparocentesis using a "wandering" catheter Right variants:

- a) 1, 2, 3, 4
- +b) 1, 2, 4, 5
- c) 1, 2, 3, 5
- d) 2, 3, 4, 5
- e) 1, 3, 5

31. In acute appendicitis as well as in acute pancreatitis the following common symptoms can be observed: 1. Sudden onset 2. Localisation of pains in the epigastric area 3. Girdle pains 4. Localisation of pains in the right iliac area 5. Recurrent bile vomiting without a relief Right variants:

- a) 1, 2, 5
- b) 2, 3, 4, 5
- +c) 1, 2, 4
- d) 1, 2, 3, 4
- e) 1, 2, 4, 5

32. Indications for abdominal cavity tamponade after appendectomy are: 1. Impossibility to remove the whole vermiform appendix or its part 2. Periappendicular abscess opening 3. Unreliable hemostasis 4. Danger of failure of sutures, immersing the appendix stump due to blind gut cupula infiltration 5. Retrocecal appendicitis. Right variants:

- +a) 1, 2, 3, 4
- b) 2, 3, 4, 5
- c) 1, 2, 3, 4, 5
- d) 2, 3, 5
- e) 1, 4, 5

33. Tamponade after appendectomy is indicated after appendectomy in: 1. Opening of the appendicular infiltrate abscess formation 2. Phlegmonous appendicitis with abundant exudates in the abdominal cavity 3. Retrocecal appendicitis 4. Peritonitis 5. Capillary bleeding from the bed of the vermiform appendix Right variants:

- a) 1, 2, 3, 4
- b) 2, 3, 4
- +c) 1, 5
- d) 3, 4, 5
- e) 2, 3, 4, 5

34. What measures should be taken for treatment of dense pelvic infiltrates without signs of abscess formation: 1. Elevate the head of the bed 2. Use broad spectrum antibiotics 3. Give warm camomile tea enemas 4. Sparing digestible high-calorie diet 5. Regular cleansing enemas Right variants:

- a) 1, 2, 3, 4
- b) 1, 3, 4, 5
- c) 1, 2, 4, 5
- d) 1, 2, 3, 5
- +e) 2, 3, 4, 5

35. What modern methods can be used today for diagnosing subdiaphragmatic abscess? 1. X-ray examination 2. Ultrasonic scanning 3. Selective celiacography 4. Computer tomography 5. Thermography Right variants:

- a) 1, 2, 3, 4
- b) 1, 2, 3, 5
- c) 3, 4, 5
- d) 2, 3, 4, 5
- +e) 1, 2, 4, 5

36. Conditions favouring the development of appendicular infiltrate are: 1. Late visit to a doctor 2. Diagnostic mistakes in pre-hospital and hospital periods 3. 3 - 5 days from the onset 4. Phlegmonous changes of the vermiform appendix 5. Vermiform appendix perforation Right variants:

- +a) -1, 2, 3, 4
- b) 1, 2, 4, 5
- c) 1, 2, 3, 5
- d) 1, 3, 4, 5

e) 2, 3, 4, 5

37. The primary period of appendicular infiltrate formation is characterized by: 1. Reduction of pains, evident in the first days of the disease 2. Improvement of patients' general condition 3. Body temperature increase 4. Leukocytosis increase and shift of the leukogram to the left 5. Dense, non-mobile, non-painful lump in the right iliac area Right variants:

- a) 1, 2, 3, 4
- b) 1, 2, 3, 5
- c) 1, 4, 5
- +d) 1, 2, 3, 4, 5
- e) 2, 3, 4, 5

38. What is characteristic of acute appendicitis complicated with appendicular infiltrate in comparison with the blind gut tumor? 1. Short anamnesis 2. Acute character of the pains in the right iliac area accompanied by increased temperature 3. Volkovich-Kocher's sign 4. Frequent signs of partial intestinal obstruction in anamnesis 5. Tendency to tumor mass reduction during the observation Right variants:

- a) 1, 2, 5
- b) 1, 3, 4, 5
- +c) 1, 2, 3, 5
- d) 3, 4, 5
- e) 1, 2, 3, 4, 5

39. The question on appendicular infiltrate abscess formation can arise in case of: 1. High temperature especially if it has hectic character 2. Pain resumption and increase 3. Symptoms of peritoneum irritation 4. Leukocytosis increase and shift of the leukogram to the left, ESR increase 5. Absent tendency to infiltrate reduction in 7-10 days of intensive therapy, especially while antibiotics administration. Right variants:

- a) 1, 2
- b) 2, 4, 5
- +c) 1, 2, 3, 4
- d) 2, 3, 4, 5
- e) 3, 4, 5

40. When opening the appendicular infiltrate after abscessation: 1. The surgery is performed under the general anaesthetization 2. Extraperitoneal (Pirogov's) approach is used if possible 3. Infiltrate is carefully carefully separated by blunt, not damaging the infiltrated intestinal loops 4. Destructively altered vermiform appendix is exposed and removed 5. Abscess cavity is carefully washed and drained Right variants:

- a) 1, 3, 4, 5
- b) 1, 2, 3, 4, 5
- +c) 1, 2, 3, 5
- d) 2, 4, 5
- e) 2, 3, 4, 5

41. On the sixth day after laparotomy on appendicular peritonitis a patient felt pains in the lower part of the abdomen, tenesmus, dysuric symptoms, fever. Temperature rose to 39,50C and acquired a hectic character. Tongue was wet, the abdomen was soft and moderately painful above the pubis. Rectal investigation through the anterior wall of the rectum detected large painful infiltrate with softening. What would you diagnose?

- 1. Pylephlebitis
- +2. Small pelvis abscess
- 3. Periappendicular abscess

- 4. Intrafilar abscess
- 5. Sepsis

42. Rigors are characteristic of pyelophlebitis:

- 1. No
- +2. Yes

43. A 34-year-old patient was operated on plegmonous gangrenous appendicitis. 7 days after the surgery he felt shivering, rectal pains, tenesmus, frequent painful urination. Rectal investigation detected an infiltrate in the small pelvis. 3 days after the therapy (warm chamomile tea enemas and antibiotics) the patient's condition didn't improve. Rectal re-investigation showed the infiltrate softening. Temperature acquired a hectic character. What therapy should be prescribed?

- 1. Antibiotics, physiotherapy, hyperbaric oxygenation
- +2. Drain of the pelvic abscess via the rectum
- 3. Other methods

44. Evident local tension of the abdominal wall in normal pulse rate and bradycardia is observed in acute appendicitis and is characteristic of the following peritonitis stage:

- 1. Toxic
- 2. Terminal
- +3. Reactive

45. Moderate tension of the abdominal wall in normal pulse rate of good filling is observed in acute appendicitis and is characteristic of the following peritonitis stage:

- 1. Terminal
- +2. Toxic
- 3. Reactive

46. The most often reason of surgical sepsis after appendectomy is:

- 1. Blind gut cancer
- 2. Foreign body (tissue)
- 3. Actinomycosis
- +4. Wound infecting during the surgery
- 5. Fecal fistula

47. One of the following examination technique allows to approve appendicitis in a patient:

- 1. Colonoscopy
- 2. Laparoscopy
- 3. Ultrasonic scanning of the abdomen
- +4. Irrigoscopy
- 5. Plain abdominal cavity film

48. What diseases chronic appendicitis should be differentiated from? 1. Right kidney pathology 2. Chronic adnexitis 3. Chronic colitis 4. Cholelithiasis 5. Helminthic invasion Choose the correct answer combination:

- a) 2, 3, 4

- b) 1, 2, 3
- c) 2, 3, 5
- d) 1, 2, 4
- +e) All the mentioned diseases

49. A patient operated was on acute phlegmonous appendicitis and local peritonitis through a typical approach. The 9th day after the surgery right-sided subdiaphragmatic abscess was diagnosed. What is the reason of its formation? 1. Trendelenburg's position wasn't used in a patient 2. Fowler's position wasn't used in a patient 3. Inferomedial laparotomic approach had to be used 4. Exudate in the abdominal cavity wasn't drained 5. The tamponade of the abdominal cavity wasn't performed

- a) 1, 4
- +b) 2, 4
- c) 3, 4, 5
- d) 1, 3, 4
- e) 2, 3, 5

50. During the surgery in a patient with acute appendicitis you have found a dense infiltrate. What would you undertake?

- 1. Perform midline laparotomy and appendectomy under narcosis
- +2. Suture the abdominal cavity wound and indicate antibiotics and cold locally.
- 3. Expose the vermiform appendix from the inflammatory infiltrate and perform appendectomy
- 4. Introduce tamponade and drain in the abdominal cavity
- 5. All variants are incorrect

51. You have diagnosed an appendicular infiltrate in a patient. Complex of what conservative measures is most reasonable in the first three days? 1. Cold on the stomach 2. Antibiotics indication 3. UHF or ultraviolet irradiation locally 4. Warm compress on the right iliac area 5. Proteolytic ferments parenterally

- a) 2, 3
- b) 4, 5
- +c) 1, 2
- d) 1 and 5
- e) Only 2

52. The most characteristic signs of chronic appendicitis are: 1. Voskresensky's sign 2. Moderate blood leukocytosis 3. Continuous retention of barium meal in the vermiform appendix during the roentgenological examination 4. Frequent pains in the right iliac area 5. Positive Sitkovsky's symptom Choose the correct answer combination:

- a) 1, 2, 4
- b) 1 and 3
- +c) 3 and 4
- d) 2, 3, 4

Acute intestinal obstruction.

1. At the primary stage of large intestinal obturation obstruction the following therapeutic approach is reasonable:

- 1. Emergency surgery, allowing to prevent intestinal necrosis and perforation
- 2. Surgery within 48-72 hours after examination and detection of the obstruction reasons
- 3. Emergency surgery - double barrel colostomy or enterostomy

+4. Conservative measures. In absence of the effect emergency surgery should be performed
5. All the listed variants are correct

2. Factors, promoting the development of strangulated intestinal obstruction are: 1. Long narrow mesentery 2. Commissural process in the abdominal cavity 3. Comissuring of Meckel's diverticulum with mesentery 4. Alcohol intake 5. Intake of roasted food Choose the right answer combination:

- +a) 1, 2, 3
- b) 1, 4, 5
- c) 2, 3, 4
- d) 2, 4, 5
- e) All variants are correct

3. What is developed in the early period of acute small bowel obstruction? 1. Hyperkalemia 2. Dehydration 3. Hematocrit reduction 4. Hematocrit increase 5. hypokalemia Right variants:

- a) 1, 2, 3
- b) 1, 3, 5
- +c) 2, 4, 5
- d) 2, 3, 5
- e) 1, 4, 5

4. Following symptoms are pathognomic for obturation intestinal obstruction: 1. Constant abdominal pains 2. Colicky abdominal pains 3. Coffee-grounds vomiting 4. Abdominal distension 5. Recession of epigastric area Choose the right answer combination:

- +a) 2, 4
- b) 1, 4
- c) 1, 3, 5
- d) 2, 3, 5
- e) 2, 3, 4

5. What are the deciding examination techniques for acute intestinal obstruction diagnosing? 1. Plain roentgenoscopy of abdominal cavity 2. Examination of barium passage along the gastrointestinal tract 3. Esophagogastroduodenoscopy 4. Laparoscopy 5. Biochemical blood analysis Choose the right answer combination:

- a) 1, 2, 3
- b) 2, 4, 5
- +c) 1 and 2
- d) 2 and 3
- e) 1, 4, 5

6. Choose the type of acute intestinal obstruction symptom of which is blood-tinged discharge from the anus:

- 1. Paralytic
- 2. Spastic
- 3. Intestinal infarction
- 4. Volvulus of small bowel
- +5. Invagination

7. Effect of conservative therapy is most probable in following types of acute intestinal obstruction: 1. Volvulus of small bowel 2. Node formation between the loop of small and sigmoid bowel 3. Spastic intestinal obstruction 4. Traumatic intestinal paresis 5. Coprostasis Choose the right answer combination:

- a) 1, 3, 4
- b) 1, 3, 5
- c) 2, 4, 5
- +d) 3, 4, 5
- e) Only 1 and 2

8. A 50-year-old patient with blind gut cancer suffers from acute intestinal obstruction. Urgent surgery detected, that regional lymph nodes are not enlarged, remote metastases are absent. What measures are reasonable?

- +1. Right-sided hemicolectomy
- 2. Cecostomy
- 3. Blind gut resection
- 4. Hartmann's surgery
- 5. Mikulich's surgery

9. Everything mentioned below is characteristic of large bowel obstruction, except:

- 1. Gradual increase of intoxication symptoms
- 2. Abdominal distension
- +3. Kloyber's cups
- 4. Stool retention
- 5. Rapid dehydration

10. A 76-year-old patient suffering from chronic colitis appealed for a medical aid. He suffers from bursting pain and absence of stool for 7 days. Rectal examination detected dense fecal masses. What measures should be taken? 1. Urgent surgery 2. Injection of a drug, increasing intestinal peristalsis 3. Spasmolytics injection 4. Siphon enema 5. Laxative intake Right variants:

- a) Only 1
- b) 2 and 5
- c) Only 2
- +d) Only 4
- e) 3 and 5

11. What examination methods can confirm acute intestinal obstruction?

- +1. Plain radiography of abdominal cavity
- 2. Intravenous cholangiography
- 3. Laparoscopy
- 4. Gastroduodenoscopy
- 5. Ultrasonic scanning of abdominal cavity

12. The most often reason for small bowel mechanical obstruction is:

- 1. Foreign bodies in the intestinal tract
- 2. Bile stones
- 3. Intestinal tumors
- +4. Adhesions of abdominal cavity
- 5. Helminths in the intestinal tract

13. Clinical picture of acute obturation large bowel obstruction is characterized by: 1. Colicky abdominal pains 2. Abdominal distension 3. Boat-shape abdomen 4. Constant abdominal pains 5. Stool and gases retention Choose the

right answer combination:

- a) 1, 3, 5
- +b) 1, 2, 5
- c) 1 and 3
- d) 4 and 5
- e) 2, 4, 5

14. Severe small bowel obstruction is characterized by following signs: 1. Colicky abdominal pains 2. «Splashing sound» 3. Recurrent vomiting 4. Tsege - Manteuffel symptom 5. «Kloyber's cups», detected during the abdominal cavity radioscopy Choose the right answer combination:

- a) 1, 2, 3
- b) 1, 2, 3, 4
- +c) 1, 2, 3, 5
- d) 2, 3, 4
- e) 3 and 5

15. What proves the effectiveness of conservative measures in treatment of acute intestinal obstruction? 1. Prolongation of interval between episodes of pain 2. Defecation and passage of gases 3. Reduction of abdominal distension 4. Weakening of peristalsis 5. Pain disappearance Choose the right answer combination:

- a) 1, 3, 5
- +b) 2, 3, 5
- c) 1, 3, 4
- d) 3, 4, 5
- e) 1, 4, 5

16. What treatment should be applied in dynamic intestinal obstruction?

- +1. Only conservative
- 2. Only operative
- 3. Operative if the effect of the conservative one is absent
- 4. Laparoscopic ileostomy
- 5. Intubation of large bowel with colonoscope

17. Dehydration in acute intestinal obstruction develops due to: 1. Vomiting 2. Diuresis increase 3. Liquid sequestration in the intestinal lumen 4. Liquid sequestration in the retroperitoneal space 5. Perspiration increase Choose the right answer combination:

- a) 1, 2
- b) 3, 4
- +c) 1, 3
- d) 2, 5
- e) 4, 5

18. Following surgeries are performed in acute intestinal obstruction due to sigmoid colon volvulus: 1. Noble's surgery 2. Sigmoid colon resection with end-to-end anastomosis 3. Hartmann's surgery 4. Gagen-Torn's mesosigmoidoplication 5. Bowel detorsion Choose the right answer combination:

- a) 1, 2, 3
- +b) 3, 4, 5
- c) 3, 4
- d) 1, 2, 4, 5

e)2, 3, 4, 5

19. While examining a 70-year-old patient you have detected abdominal distension, increased resonating peristalsis and “splashing sound”. What disease is this clinical picture characteristic of?

1. Compensated ulcerative stenosis
2. Biliary colic
- +3. Acute intestinal obstruction
4. Intestinal infarction
5. Peritonitis

20. In nonviable loop of small bowel following measures are taken:

1. Afferent limb resection 20 cm off necrosis
2. Bowel resection within necrosis borders
3. Bypass
4. Bowel exteriorization
- +5. Resection of the efferent limb 15-20 cm off necrosis

21. What is indicated in tumor perforation of ascending colon with metastases into the liver?

1. Right-sided hemicolectomy with ileotransverse anastomosis
- +2. Right-sided hemicolectomy, terminal ileostomy
3. Perforation suturing, ileotransverse anastomosis
4. Right-sided hemicolectomy, colostomy and ileostomy
5. Cecostomy

22. Everything mentioned below is characteristic of low large bowel obstruction, except:

1. Gradual symptoms intensifying
2. Abdominal distension
3. «Kloyber's cups», stool retention
- +4. Rapid (during 24 hours) dehydration

23. Blood circulation in intestine mesentery is not disturbed in:

1. Volvulus
- +2. Obturation
3. Node formation
4. Invagination
5. Entrapment

24. Blood-tinged discharge from the rectum can be observed in the following type of intestinal obstruction:

1. Paralytic
2. Spastic
- +3. Invaginated
4. Commissural
5. Strangulated

25. The quickest intestinal necrosis development occurs in:

1. Obturation of the ileum with a tumor
2. Obturation of the large bowel with a tumor
3. Obturation of the jejunum lumen with a bile stone
- +4. Node formation
5. Obturation of the jejunum large bowel lumen by impacted feces

26. What does not influence the choice of therapeutic approach in acute intestinal obstruction?

1. Type of obstruction
2. Stage of obstruction
- +3. Presence of peritoneal symptoms
4. Intensity of pains
5. Radiological data

27. What should be first performed if acute intestinal obstruction is suspected?

- +1. Plain radiography of the abdominal cavity
2. Examination of barium passage along the intestine
3. Esophagogastroduodenoscopy
4. Laparoscopy
5. Biochemical blood analysis

28. Loud peristaltic noises in the early phase of a disease are characteristic of:

1. Paralytic intestinal obstruction
2. Perforated stomach ulcer
- +3. Mechanical bowel obstruction
4. Gangrenous cholecystitis
5. Mesenterial thrombosis

29. The most often invagination localization is:

1. Blind gut
- +2. Ileocecal segment
3. Ilio-iliac segment
4. Sigmoid colon

Peritonitis

1. Normally, an adult's abdominal cavity contains serous fluid of:

- +1. 20 ml
2. 80 ml
3. 120 ml
4. 200 ml
5. 220 ml

2. Hemorrhagic exudate in the abdominal cavity is not observed in:

1. Acute pancreatitis

- +2. Acute cholecystitis
- 3. Mesenteric vessels thrombosis
- 4. Mesenteric vessels embolism
- 5. Intestinal obstruction

3. Onset of acute peritonitis is accompanied by abdominal pains in:

- 1. 50% of patients
- 2. 50-75% of patients
- 3. 75-90% of patients
- +4. 100% of patients

4. Onset of acute peritonitis is accompanied by tension of abdominal muscles in

- 1. 15-25% of patients
- 2. 35-50% of patients
- +3. 85-90% of patients
- 4. 100% of patients

5. Free gas in abdominal cavity in perforation of hollow organs occurs in:

- 1. 20-40% of patients
- +2. 60-75% of patients
- 3. 100% of patients

6. In what acute peritonitises peristaltic intestinal murmurs are observed?

- 1. Colibacillary peritonitis
- 2. Abdominal typhoid peritonitis
- +3. Pneumococcal peritonitis
- 4. Mixed infection

7. A 14-year-old girl has been suffering from acute bronchitis during 3 days, after what she felt acute pains in the abdomen. She had vomiting, diarrhea, lips cyanosis, 110 bpm pulse, abdominal wall muscle tension, pain in the whole abdomen. Leucocytosis was $38 \times 10^9/l$, ESR was 24 ml/h. Pneumococcal peritonitis was diagnosed. What is your therapeutic approach?

- 1. Emergency surgery
- +2. Antibiotic therapy
- 3. Disintoxication therapy

8. A 46-year-old patient had appendectomy on acute gangrenous appendicitis. 5 days later he felt dull underbelly pains, tenesmus, pains during defecation, insignificant whites in urination. Temperature increased to 37,8 - 38,5°C. What is your supposed diagnosis?

- 1. Acute proctitis
- 2. Acute hemorrhoids
- 3. Diffuse peritonitis
- +4. Douglass abscess
- 5. Acute cystitis

9. The most often reason of peritonitis is:

- +1. Acute appendicitis

2. Perforated ulcer
3. Salpingitis
4. Small bowel strangulation
5. Stomach cancer

10. Reactive stage of peritonitis lasts:

- +1. 4 - 6 hours
2. -24 hours
3. 48 hours
4. 72 hours
5. More than 72 hours

11. In primary peritonitis the peritoneum infection occurs:

1. In stomach ulcer perforation
2. In vermiform appendix perforation
3. In ansextitis
- +4. By hematogenic way
5. In the intestinal wound

12. Following sign are not characteristic of peritonitis:

1. Abdominal wall muscles tension
- +2. Courvoisier's symptom
3. Rapid pulse
4. Flatus retention
5. Vomiting

13. Following sign are not characteristic of peritonitis:

1. Tachycardia
2. Dry tongue
3. Anterior abdominal wall muscles tension
4. Absence of intestinal peristalsis
- +5. Diarrhea

14. The main peritonitis symptom is:

1. Vomiting
2. Stomach pains
3. Melena
4. Stool and gases retention
- +5. Anterior abdominal wall muscles tension

15. Peritonitis can be the result of all following diseases except:

1. Diverticulum of Meckel perforation
2. Crohn's disease
- +3. Large duodenal papilla stenosis
4. Richter hernia strangulation
5. Acute intestinal obstruction

16. Symptoms that don't correspond to subdiaphragmatic abscess are:

1. Pain while breathing in the right part of the chest and in the upper abdomen.
2. Painfulness when pressing the lower ribs
3. Hectic temperature
- +4. Kloyber's cups

17. All symptoms mentioned below can take place in subdiaphragmatic abscess except:

1. Reduction of respiratory lung excursion
 2. High-riding cupula of diaphragm
 3. Consensual exudates in the pleural cavity
 4. Pains irradiated in supraclavicular area
 - +5. Diarrhea
18. The best variant of subdiaphragmatic abscess treatment is:

1. Conservative therapy
2. Extraperitoneal opening and drainage
3. Laparotomy, opening and cavity tamponade
- +4. Ultrasound guided puncture of an abscess with a thick needle
5. Everything mentioned is correct

19. The best method of subdiaphragmatic abscess opening is:

1. Thoracolaparotomy
2. Lumbotomy
3. Two-stage transpleural approach
4. Laparotomy by Fedorov
- +5. Extrapleural extraperitoneal method

20. What is indicated in Douglas abscess?

1. Puncture via abdominal wall
2. Therapeutic enema
3. Opening via abdominal wall
- +4. Puncture, opening and drainage via the rectum
5. Conservative therapy

21. Midline laparotomy should be performed in:

- +1. Diffuse peritonitis
2. Local diffuse peritonitis
3. Douglas abscess
4. Appendicular infiltrate
5. Acute appendicitis

22. Bile-coloured fluid in the abdominal cavity is observed in all cases except:

1. Ruptured gallbladder
- +2. Rupture of a suppurated hepatic hydatid
3. Lasting obstructive jaundice
4. Duodenal ulcer perforation
5. Spontaneous bile peritonitis

23. Blood-coloured fluid in the abdominal cavity is observed in all cases except:

- +1. Tuberculosis peritonitis
- 2. Extrauterine pregnancy disorders
- 3. Mesenterial thrombosis
- 4. Acute pancreatitis
- 5. Twisted ovarian cyst

24. Fibrinous overlay on the peritoneum is impossible in following type of peritonitis:

- +1. Serous
- 2. Fibrinous
- 3. Purulent
- 4. Putrid
- 5. Fecal

25. All the symptoms are characteristic of the late peritonitis stage, except:

- 1. Bloating
- 2. Hypovolemia
- 3. Intestinal murmur disappearance
- 4. Hypoproteinemia
- +5. Increased peristalsis

26. How is peritonitis diagnosed before the surgery?

- 1. Roentgenologically
- 2. Anamnestically
- 3. By laboratory definition of signs of the inflammatory reaction
- +4. According to clinical signs
- 5. By the level of gastric juice secretion

27. A 70-year-old patient with circulatory deficiency of the II-III stage has symptoms of a five-day diffuse peritonitis. What is the therapeutic approach?

- 1. Emergency surgery after 24-hour preparation
- +2. Emergency surgery after cardiac drugs injection
- 3. Emergency surgery after a short-term 2-3-hour infusion therapy
- 4. Surgery after total liquidation of blood volume and protein electrolyte components deficit

28. What is the most common cause of peritonitis?

- a) Appendicitis**
- b) Diverticulitis
- c) Cholecystitis
- d) Pelvic inflammatory disease

29. Which imaging test is commonly used to diagnose peritonitis?

- a) Ultrasound
- b) MRI
- c) CT scan**
- d) X-ray

30. What is the primary goal of surgical treatment for peritonitis?

- a) Drain the infected fluid from the abdomen

b) Repair the perforated organ or structure causing the infection

c) Administer intravenous antibiotics

d) Remove the entire affected organ

31. Which of the following is NOT a common symptom of peritonitis?

a) Abdominal pain

b) Nausea and vomiting

c) Constipation

d) Fever

32. What is the gold standard test for diagnosing peritonitis and determining the underlying cause?

a) Laparoscopy

b) Abdominal ultrasound

c) Barium enema

d) Upper endoscopy

33. What type of surgery involves creating an opening in the abdominal wall to drain infected fluid from the peritoneal cavity?

a) Appendectomy

b) Cholecystectomy

c) Peritoneal lavage

d) Laparotomy

34. What is the primary cause of secondary peritonitis?

a) Ruptured appendix

b) Bacterial infection in the bloodstream

c) Perforated stomach ulcer

d) Trauma to the abdomen

35. Which blood test is commonly used to assess the severity of peritonitis and monitor the patient's response to treatment?

a) Complete blood count (CBC)

b) Liver function tests

c) Coagulation profile

d) Serum electrolytes

36. Which of the following is NOT a common source of infection leading to peritonitis?

a) Bowel perforation

b) Gallbladder infection

c) Pelvic abscess

d) Bladder rupture

37. What is the primary role of antibiotics in the management of peritonitis?

a) Prevent recurrence of peritonitis

b) Relieve symptoms of peritonitis

c) Treat the underlying cause of peritonitis

d) Control and eliminate the infection in the abdomen

38. Which of the following is a symptom of peritonitis?

✓ - Severe abdominal pain

X - Headache

X - Chest pain

X - Back pain

39. How is peritonitis diagnosed?

X - Urine test

X - Stool test

✓ - **Physical examination and imaging tests**

X - Blood test

40. Which type of peritonitis is caused by bacteria spreading from another site of infection in the body to the peritoneal cavity?

a) Primary peritonitis

b) Secondary peritonitis

c) Tertiary peritonitis

d) Fungal peritonitis

41. What is the peritoneum lining the inner side of the parietes called?

X - Mesothelium

X - Peritoneal defect

✓ - **Parietal peritoneum**

X - Visceral peritoneum

42. Which surgical procedure involves removing an inflamed or infected gallbladder to treat peritonitis caused by cholecystitis?

a) Appendectomy

b) Cholecystectomy

c) Colectomy

d) Herniorrhaphy

43. What is the most common form of peritonitis?

X - Primary peritonitis

✓ - **Secondary peritonitis**

X - Spontaneous peritonitis

X - Tuberculous peritonitis

44. Which medication is commonly used to reduce inflammation and control infection in patients with peritonitis?

a) Proton pump inhibitors (PPIs)

b) Nonsteroidal anti-inflammatory drugs (NSAIDs)

c) Intravenous antibiotics

d) Antifungal agents

45. Which organisms are the commonest in producing peritonitis?

X - Bacteroides

✓ - **Gram-negative organisms**

X - Gonococci

X - Enterococci

46. What is the term for inflammation of the peritoneum?

X - Penetrating injury

X - Perforation

X - Peritoneum

✓ - **Peritonitis**

47. What is the function of the omentum in peritonitis?

X - Supplying collateral blood supply

✓ - **Sealing the area of infection or perforation**

X - Producing fibrin

X - Destroying unopsonised bacteria

48. What are the factors that decide the severity of peritonitis?

X - Infected bile peritonitis

X - Postoperative peritonitis

✓ - **Clean perforation**

X - Retrocaecal appendicitis

49. Which blood product is commonly transfused to replace lost blood volume in patients with severe peritonitis?

a) Platelets

b) Fresh frozen plasma (FFP)

c) Packed red blood cells (PRBCs)

d) Cryoprecipitate

50. What are the clinical features of generalised peritonitis?

X - Severe pain in the right iliac fossa

X - Diffuse peritonitis

X - Minimal abdominal signs

51. Which surgical procedure involves creating an opening in the abdominal wall to divert stool away from an injured or diseased segment of the intestine in patients with severe peritonitis?

a) Ileostomy

b) Colostomy

c) Bowel resection

d) Anastomosis

52. What is one potential cause of primary peritonitis in patients with chronic kidney disease?

a) Uremic peritonitis

b) Renal artery stenosis

c) Nephrotic syndrome

d) Renal cell carcinoma

53. What is the function of the peritoneum in peritonitis?

X - Exuding fluid

X - Absorbing fluid

X - Participating in fluid exchange

✓ - **Secreting prostaglandins, interferons, and free radicals**

54. What is one potential complication of untreated or severe secondary peritonitis?

a) Pancreatitis

b) Pneumothorax

c) Osteomyelitis

d) Anemia

55. What is the largest cavity in the body?

X - Cranial cavity

X - Thoracic cavity

X - Abdominal cavity

✓ - **Peritoneal cavity**

56. What is one potential cause of primary peritonitis in patients with chronic liver disease?

a) Spontaneous bacterial peritonitis

b) Hepatic encephalopathy

c) Esophageal varices

d) Cholecystitis

57. What is one potential cause of secondary peritonitis in infants and young children?

- a) **Ruptured appendix**
- b) Necrotizing enterocolitis
- c) Hirschsprung's disease
- d) Intussusception

58. What is the function of the peritoneal fluid?

- X - Absorption of fluid
- X - Secretion of fluid
- X - Protection against peritonitis
- ✓ - **Smooth gliding of intestines**

59. What is the definition of peritonitis?

- X - Infection of the peritoneal cavity
- X - Fluid accumulation in the peritoneal cavity
- ✓ - **Inflammation of the peritoneum**
- X - Damage to the peritoneal lining

60. What are the causes of primary peritonitis?

- X - Perforation of a hollow viscus
- X - Direct spread of infection
- X - Penetrating injuries to the abdomen

Acute pancreatitis.

1.What is not used to reduce throes in acute pancreatitis?

- 1. Vagosympathetic block
- 2. Peridural anesthesia
- 3. Paranephric block
- 4. Block of round ligament of liver
- +5. Morphine

2.Exposure of haemorrhagic exudates into the abdominal cavity and foci of fat necrosis on the peritoneum points to:

- 1. Damage of the hollow organ
- 2. Liver rupture
- +3. Acute pancreatitis
- 4. Perforated stomach ulcer
- 5. Mesenteric thrombosis

3.The most common symptom of acute pancreatitis is:

- 1. Nausea and vomiting
- 2. Hyperthermia
- 3. Jaundice
- 4. Bloating
- +5. Pains in the upper part of the abdomen

4.Postnecrotic complications of acute pancreatitis are:

- 1. Pancreatic shock
- 2. Acute hepatic insufficiency
- +3. Omentum bursa abscess

- 4. Pancreatogenous pancreatitis
- 5. Haemorrhagic pancreatitis

5. What does not take part in pathogenesis of acute pancreatitis?

- 1. Enterokinase
- 2. Elastase
- 3. Phospholipase
- 4. Trypsin
- +5. Streptokinase

6. The most informative method of pancreas cyst diagnosing is:

- 1. ERCP
- 2. Investigation of barium passage along the intestine
- 3. Biochemical investigation
- +4. Ultrasonic scanning
- 5. Nothing of the mentioned above

7. The most common clinical-morphological form of acute pancreatitis is:

- +1. Edematous pancreatitis
- 2. Fatty pancreatonecrosis
- 3. Haemorrhagic pancreatonecrosis
- 4. Purulent pancreatitis
- 5. Fatty pancreatonecrosis with enzymatic peritonitis

8. What kind of pains is characteristic of acute pancreatitis?

- 1. Dull
- +2. Girdle
- 3. Cramping
- 4. knife-like
- 5. Aching

9. In a 30-year-old patient with destructive pancreatitis appeared hectic temperature, fever, tachycardia, shift of the leukogram to the left, infiltrate in the epigastrium on the 14th day of the disease. It can be conditioned by:

- 1. Cholangitis
- 2. Pneumonia
- 3. Pancreas cyst
- 4. Supraperitoneal phlegmon
- +5. Suppurated pancreatic pseudocyst

10. What is indicated in suppurated pseudocyst of the pancreas?

- 1. Conservative antibioticotherapy
- 2. Conservative desintoxicating therapy
- +3. Surgery
- 4. Observation
- 5. Continuation of earlier indicated therapy

11. Clinical picture of pancreatonecrosis is not characterized by:

1. Gridle pains in the stomach
2. Recurrent vomiting
- +3. Pneumoperitoneum
4. Collapse
5. Tachycardia

12. What is indicated in fatty pancreatonecrosis:

1. Laparotomy, abdominal cavity drainage
2. Laparotomy with capsula glandularis excision
- +3. Infusion therapy, antienzymatic and cytostatic drugs
4. Distal resection of the pancreas
5. All variants are correct

13. The main starting point for the development of acute pancreatitis is:

1. Infection
2. Spasm of the duodenum
3. Inflammation of the pancreas and biliary tracts
- +4. Reflux of bile and duodenal contents into Wirsung's duct

14. The main, the least dangerous and accessible method of pancreas examination is:

1. Radiography of abdominal cavity organs
- +2. Ultrasonic scanning of the pancreas
3. General blood test
4. Laparoscopy
5. Computer tomography

15. In acute pancreatitis laparoscopy allows to do everything mentioned below, except:

1. Approve diagnosis of acute pancreatitis; determine the character of pathologic process.
2. Aspirate the exudates from the abdominal cavity, drain abdominal cavity and minor omentum bursa, fulfill catheterization of round ligament of liver for drugs injection
3. Carry out cholecystectomy for bile ducts decompression
4. Avoid ungrounded laparotomy
- +5. Carry out papillotomy

16. Fatty pancreatonecrosis develops as a result of:

1. Proteolytic necrobiosis of albuminous cells under the influence of proteolytic enzymes.
2. Action of elastase on the venule walls and interlobular connective tissue
3. Infections accompanying interstitial pancreatitis (edematous)
- +4. Destructive effect on albuminous cells and interstitial fatty tissue of lipolytic enzymes
5. Spontaneous reduction of autolytic processes

17. Haemorrhagic pancreatonecrosis develops as a result of:

1. Infection accompanying pancreas edema
2. Destructive effect of lipolytic enzymes on albuminous cells and interstitial tissue

- +3. Protheolytic necrobiosis of albuminous cells and damage of the vessel wall by protheolytic enzymes.
- 4. Reverse development of autolytic processes
- 5. Forming of demarcation inflammatory process around the foci of fat necrosis

18. What is not characteristic of pain syndrome in acute pancreatitis?

- 1. Constant severe girdle pains, accompanying by vomiting
- 2. Palpation detects transversal painfulness, moderate tense in projection to the pancreas (Körte's symptom)
- 3. Pain appears after fatty, spicy, fried food and alcohol; long interval in taking meals.
- +4. Positive Mayo-Robson's symptom
- 5. Pains increase at the height of peristalsis

19. The most characteristic vomiting in acute pancreatitis is:

- 1. One-time
- +2. Recurrent, not giving relief
- 3. One-time, giving relief
- 4. Vomiting, that reduces and passes after fluid intake
- 5. Coffee-grounds vomiting

20. Edema of the pancreas was detected in a patient during a surgery. The gallbladder is not intense, stones are absent. What are the ways to finish the surgery?

- 1. Suture the wound without other surgical interventions.
- 2. Cholecystostomy
- +3. Drain the omentum bursa, inject antibiotics, actienzyme on procaine in the tissue, surrounding the pancreas, catheterize round ligament of the liver for injection of drugs after the surgery.
- 4. Cholecystectomy
- 5. Abdominization of the pancreas

21. Reasons of tail of pancreas necrosis after spleen removal are:

- 1. Anatomical organization
- 2. Trauma of the pancreas
- +3. Ligation of caudal artery
- 4. Ligation of great pancreatic artery

22. What is the main function of the pancreas?

- X - Filtering blood
- ✓ - **Producing insulin**
- X - Producing bile
- X - Storing nutrients
- ✓ - **Producing digestive enzymes**
- ✓ - **Regulating blood sugar levels**

23. Which of the following is NOT a common complication of pancreatic surgery?

- a) Pancreatitis
- b) Intra-abdominal abscess
- c) Pancreatic fistula
- d) Gastric ulcer**

22. What is the primary goal of surgical treatment for chronic pancreatitis?

- a) Resecting the entire pancreas
- b) Relieving pain and improving quality of life**
- c) Removing the spleen
- d) Bypassing the pancreas

23. Which imaging test is commonly used to diagnose pancreatic cancer?

- a) **CT scan**
- b) MRI
- c) Ultrasound
- d) PET scan

24. Which surgical procedure involves removing the entire pancreas?

- a) **Total pancreatectomy**
- b) Distal pancreatectomy
- c) Whipple procedure
- d) Pancreaticoduodenectomy

25. What is one potential complication of untreated or severe acute pancreatitis?

- a) **Sepsis**
- b) Atrial fibrillation
- c) Pneumonia
- d) Anemia

26. What is one potential cause of postoperative complications in patients who have undergone pancreatic surgery?

- a **Pancreatic fistula**
- b Surgical site infection
- c Hemorrhage
- d Bowel obstruction

27. Which surgical procedure involves removing the head of the pancreas, part of the small intestine, gallbladder, and part of the bile duct?

- a **Whipple procedure**
- b Total pancreatectomy
- c Distal pancreatectomy
- d Pancreaticoduodenectomy

28. Which part of the pancreas is relatively inaccessible?

- ✓ - **Head**
- X - Tail
- X - Body
- X - Neck

29. What is the main blood supply of the pancreas?

- X - Opening an avascular part of the lesser omentum
- X - Peritoneum lateral to the second part of the duodenum
- ✓ - **Arteries arising from major branches of the coeliac and superior mesenteric arteries**
- X - Hepatic flexure and Kocher manoeuvre

30. What is essential for safety during pancreatic surgery?

- X - Using absorbable suture material for ligature of major vessels, anastomosis, and closure of the abdomen
- X - Using silk, nylon, prolene, etc. for ligature of major vessels, anastomosis, and closure of the abdomen
- X - Providing inadequate drainage
- ✓ - **Using nonabsorbable suture material for ligature of major vessels, anastomosis, and closure of the abdomen**

31. What is the main focus of the textbook 'Diseases of the Pancreas'?

- X - Normal functions of the pancreas
- X - Methods of investigating the pancreas
- X - Surgical anatomy of the pancreas
- ✓ - **Endoscopic and interventional surgery**

32. Which of the following statements about the pancreas is true?

- X - It is easily seen and palpated even at laparotomy
- ✓ - **It is relatively inaccessible and hidden by other abdominal organs**
- X - It is located in the lower abdomen
- X - It derives its blood supply from the superior mesenteric artery only

33. What surgical manoeuvres are necessary to properly inspect and palpate the pancreas?

- X - Extending the opening of the gastrocolic omentum and retracting the transverse colon and mesocolon
- ✓ - **Mobilizing the hepatic flexure of the colon, incising the peritoneum lateral to the second part of the duodenum, and performing blunt dissection to elevate the duodenum and pancreatic head**
- X - Opening an avascular part of the lesser omentum and retracting the lesser curvature of the stomach
- X - Dividing the gastrosplenic ligament and mobilizing the spleen, splenic vessels, and tail of the pancreas

34. Why is a detailed knowledge of the pancreas and peripancreatic vasculature essential for a pancreatic resection?

- X - To plan the extent of the procedure and removal of adjacent organs
- ✓ - **To assess the resectability of a pancreatic tumor and avoid damage to vital structures**
- X - To identify the variations in pancreaticobiliary ductal anatomy
- X - To determine the lymphatic drainage of the pancreas

35. Why is it important to provide adequate drainage in pancreatic surgery?

- X - To ensure proper healing of the surgical incisions
- X - To minimize the risk of infection
- ✓ - **To prevent local damage caused by accumulation of enzymes in the peritoneal cavity**
- X - To control bleeding during the procedure

36. What controls the secretion of water and bicarbonate from the ductal system of the exocrine pancreas?

- X - Parasympathetic vagal fibres
- ✓ - **Neural and hormonal controls**
- X - Sympathetic fibres
- X - Smooth muscle cells in the ducts

37. What is the main function of the sympathetic fibres in the pancreas?

- X - Distribution to blood vessels
- X - Distribution to acinar cells
- X - Control of pancreatic secretion
- ✓ - **Regulation of pancreatic blood flow**

38. What is the main topic of the textbook?

- X - Surgical anatomy
- ✓ - **Diseases of the pancreas**
- X - Endoscopic and interventional surgery
- X - Normal functions of the pancreas

39. What is the retroperitoneal location of the pancreas mean?

- ✓ - **It is located behind the peritoneum**
- X - It is located in the chest cavity
- X - It is located in the abdominal cavity
- X - It is located in front of the peritoneum

40. What is the cellular composition of the exocrine pancreas?

- X - Muscular and nervous systems
- X - Respiratory and circulatory systems
- ✓ - **Acinar and ductal systems**

X - Endocrine and exocrine systems

41. What is the role of the pancreas in the body?

X - Cuddles the left kidney and tickles the spleen

X - Opposes the inferior vena cava and dallies with the right renal pedicle

X - Derives its blood supply from numerous arteries

✓ - **Secretes enzymes and regulates fluid and electrolyte balance**

42. Why is the pancreas difficult to manage surgically?

✓ - **It is relatively inaccessible and hidden by other organs**

X - It has a complex anatomical crossroads

X - It is located in the upper abdomen

X - It has a retroperitoneal location

43. What is necessary to inspect and palpate the pancreas properly?

X - A detailed knowledge of the pancreas and peripancreatic vasculature

X - Widely opening the gastrocolic omentum

✓ - **Three surgical manoeuvres**

X - A coeliac and a superior mesenteric arteriogram

44. What is the most demanding part of a pancreatic resection?

X - Opening an avascular part of the lesser omentum

X - Assessment of the resectability of a pancreatic tumour

X - Division of the gastrosplenic ligament

✓ - **Dissection of the neck and head of the gland from the superior mesenteric and portal veins**

45. What is the lymphatic drainage of the pancreas?

✓ - **Radially disposed along several major routes**

X - Into the foregut and midgut

X - Into the coeliac, splenic, hepatic, and superior mesenteric nodal basins

X - Into the portal venous trunk

46. What is the first principle of pancreatic surgery?

✓ - **Provision of adequate drainage**

X - Dissection of the neck and head of the gland

X - Use of nonabsorbable suture material

X - Removal of the spleen, duodenum, gallbladder, and common bile duct

47. What is the blood supply of the pancreas?

X - The coeliac axis and the superior mesenteric artery

✓ - **Numerous arteries arising from major branches of the coeliac and superior mesenteric arteries**

X - The portal vein

X - The splenic artery

48. How can the neck of the pancreas be palpated?

X - By incising the peritoneum lateral to the second part of the duodenum

X - By opening an avascular part of the lesser omentum

✓ - **By a finger passed through the epiploic foramen and directed inferiorly**

X - By mobilizing the hepatic flexure of the colon

49. What surgical manoeuvres are necessary to inspect and palpate the pancreas properly?

X - Widely opening the gastrocolic omentum and retracting the transverse colon and mesocolon

X - Opening an avascular part of the lesser omentum and retracting the lesser curvature of the stomach

✓ - **Mobilizing the hepatic flexure of the colon, incising the peritoneum lateral to the second part of the duodenum, and elevating the duodenum and pancreatic head by blunt dissection**

X - Dividing the gastrosplenic ligament and mobilizing the spleen, splenic vessels, and tail of the pancreas

50. What surgical manoeuvres are necessary to inspect and palpate the pancreas properly?

X - Widely opening the gastrocolic omentum and retracting the transverse colon and mesocolon

X - Opening an avascular part of the lesser omentum and retracting the lesser curvature of the stomach

✓ - **Mobilizing the hepatic flexure of the colon, incising the peritoneum lateral to the second part of the duodenum, and elevating the duodenum and pancreatic head by blunt dissection**

X - Dividing the gastrosplenic ligament and mobilizing the spleen, splenic vessels, and tail of the pancreas

51. What is necessary to assess the resectability of a pancreatic tumor?

X - Mobilizing the hepatic flexure of the colon and incising the peritoneum lateral to the second part of the duodenum

✓ - **Further dissection and mobilization, and a detailed knowledge of the pancreas and peripancreatic vasculature and its variations**

X - Dividing the gastrosplenic ligament and mobilizing the spleen, splenic vessels, and tail of the pancreas

X - Opening an avascular part of the lesser omentum and retracting the lesser curvature of the stomach

52. What does the exocrine pancreas secrete?

✓ - **Water, bicarbonate, and enzymes**

X - Hormones

X - Digestive juices

X - Insulin and glucagon

53. Which of the following best describes the author's purpose in including the passage by Durmen in the text?

A. To provide a historical perspective on surgical anatomy

B. To highlight the complexity of the pancreas' anatomical relationship

C. To showcase Durmen's expertise in surgical anatomy

D. To explain the surgical techniques used for pancreatic resection

54. According to the passage, why is the pancreas difficult to manage surgically?

A. It is located in the upper abdomen

B. It is hidden behind the stomach and colon

C. It is retroperitoneal

D. It derives its blood supply from numerous arteries

55. Based on the information in the passage, which of the following is NOT one of the three surgical manoeuvres necessary to properly inspect and palpate the pancreas?

A. Mobilizing the hepatic flexure of the colon downwards and medially

B. Incising the peritoneum lateral to the second part of the duodenum

C. Dividing the gastrosplenic ligament

D. Opening the avascular part of the lesser omentum

56. According to the passage, why is a detailed knowledge of the peripancreatic vasculature essential for pancreatic resection?

A. It helps assess the resectability of a pancreatic tumour

B. It allows visualization of the superior part of the body of the pancreas

C. It provides information about the blood supply to the pancreas

D. It helps identify the region of the neck and uncinate process

57. Which of the following statements is supported by the passage?

A. The pancreas is completely hidden by the stomach and colon.

B. The pancreas weighs about 2-3% of the whole gland.

- C. The islets of Langerhans form the exocrine portion of the pancreas.
- D. The exocrine tissue accounts for 75% of the pancreas by weight.

58. What is the role of secretin according to the passage?

- A. To stimulate fluid and electrolyte secretion from the pancreas**
- B. To initiate enzyme secretion in the duodenum
- C. To inhibit insulin and glycogen release
- D. To cause an increase in enzyme secretion

59. Which of the following is NOT one of the cell types found in the islets of Langerhans?

- A. A-cells
- B. B-cells
- C. C-cells**
- D. F-cells

60. What is the primary function of D-cells according to the passage?

- A. To synthesize and store glucagon
- B. To synthesize and release insulin
- C. To supply somatostatin and gastrin**
- D. To secrete pancreastatin and amylin

Esophagus

1. Following are disorders of the pharyngo-oesophageal junction except:

- 1. Stroke
- 2. Myasthenia
- 3. Cricopharyngeal achalasia
- +4. Nutcracker oesophagus

2. Following are true for oesophageal lymphatics except:

- 1. Extensive lymphatic plexus in the submucosa
- 2. They are classified as perioesophageal, paraesophageal and lateral oesophageal lymph nodes
- 3. Presence of coeliac nodes indicate inoperability
- +4. Longitudinal lymphatics are 6 times less than transverse

3. Which one of the following is highest percentage of premalignant condition or carcinoma oesophagus?

- +1. Tylosis
- 2. Lye strictures
- 3. Achalasia
- 4. Oesophagus

4. Factors or adenocarcinoma oesophagus are following except:

- 1. Barrett's oesophagus
- 2. Obesity
- 3. Reflux esophagitis
- +4. Oesophageal web

5. Factors for development of reflux disease of oesophagus include following except:

1. Obesity
2. Absence of intra-abdominal length of oesophagus
- +3. Helicobacter pylori infection
4. Defective angle of His

6. Clinical features of reflux disease of oesophagus include following except:

1. Heartburn
 - +2. Vomiting
 3. Epigastric pain
 4. Regurgitation
7. Gold standard of the treatment of reflux disease is:

1. Barium meal
- +2. Esophagoscopy
3. 24-hour pH monitoring
4. Endosonography

8. The most effective drugs of reflux disease are:

1. Alginates
2. Antacids
3. H₂ receptor antagonists
- +4. Proton pump inhibitors

9. The most effective curative treatment for carcinoma oesophagus is:

1. Radiotherapy
- +2. Oesophagectomy
3. Photodynamic therapy
4. Chemotherapy

10. Following are features of Barrett's oesophagus except:

1. 3 cm or more of columnar epithelium
2. Cardiac metaplasia
- +3. Development of squamous cell carcinoma
4. Presence of mucus secreting goblet cells (intestinal metaplasia)

11. Which of the following conditions predisposes to volvulus of the stomach?

1. Sliding hernia
- +2. Para-oesophageal hernia
3. Following gastrojejunostomy
4. Wide hiatus

12. Following are true for PET scan except:

- +1. Drug used is oral fludeoxyglucose
2. Combining PET with CT is better for diagnosis
3. Can be used after chemotherapy to see the response of the tumour
4. High metabolic activity-glycolytic pathway

13. Following are true for transhiatal oesophagectomy except:

- +1. Thoracotomy is a must for completion of the procedure
- 2. Anastomosis is in the neck
- 3. Ideal for lower oesophageal cancers
- 4. Upper oesophagus mobilisation is blind

14. About achalasia cardia following are true except:

- 1. It affects lower oesophageal end
- 2. It is due to loss of inhibitory neurons
- +3. Dilated oesophagus above contains normal ganglion cells
- 4. In vigorous achalasia normal ganglion cells are present

15. About treatment of achalasia cardia following are true except:

- 1. Balloon dilatation is ideal for patients above the age of 45 years
- +2. Botulinum toxin injection gives the permanent relief from dysphagia
- 3. Sublingual nifedipine can relieve symptoms
- 4. Myotomy with anterior fundoplication is a good surgical procedure

16. Schatzki's ring is associated with:

- 1. Proximal oesophagus
- 2. Carcinoma oesophagus
- +3. Reflux oesophagitis
- 4. Congenital ring

17. For normal swallowing stricture should be dilated to at least

- 1). 12 mm diameter
- 2). 14 mm diameter
- +3). 16 mm diameter
- 4). 18 mm diameter

18. Following are true for Mallory-Weiss syndrome except:

- +1. The vertical split occurs in the lower end of oesophagus in majority of cases
- 2. Surgery is rarely required
- 3. Endoscopic sclerotherapy is very useful treatment
- 4. More often it is a mucosal tear than rupture

19. For the diagnosis of intraperitoneal metastasis, which is the ideal investigation?

- 1. Ultrasound
- 2. CT scan
- 3. MRI
- +4. Diagnostic laparoscopy

20. Following are true about Heller's cardiomyotomy except:

- 1. It is best done by laparoscopic method

- 2.Many surgeons add fundoplication
- +3.Myotomy should be more in length in the stomach side than oesophagus
- 4.Reflux is a major complication

21. Most accurate method for the diagnosis of T stage for oesophageal cancer is by:

- 1. Upper gastroduodenal scopy
- 2. Barium swallow
- 3. CT scan
- +4. Endosonogram

Breast disease.

1. Following are true of lymphatic drainage of the breast except:

- 1. Apical nodes are also called infraclavicular nodes
- 2. Apical nodes drain into subclavian lymph trunk
- +3. Posterior third of the breast drain into supraclavicular nodes
- 4. For detection of sentinel node, ideal site is subdermal plexus around nipple

2. Following are true for advantages of MRI in the breast except:

- 1. It is the best modality for women with breast implants
- 2. Screening in women with strong family history
- +3. It is also better than ultrasound to image axilla
- 4. It can distinguish scar from recurrence in women who have undergone breast conservative surgery

3. Following are true for retraction of the nipple except:

- 1. Slit-like retraction is seen in duct ectasia
- 2. Circumferential retraction is seen in carcinoma breast
- 3. Extension of the growth along lactiferous duct causes retraction of the nipple
- +4. Horizontal retraction can occur at puberty suggests fibroadenosis

4. Following are true Lactational mastitis except:

- 1. Retracted nipple is one of the cause
- +2. Majority of the cases are due to anaerobic infection
- 3. Repeated aspiration is recommended treatment
- 4. Fluctuation is a late sign

5. Smoking is associated with which of the following breast disease?

- 1. Tuberculosis
- 2. Duct ectasia
- +3. Breast abscess
- 4. Mondor's disease

6. Following is not the common sign of Periductal mastitis:

- 1.Discharge per nipple
- 2.Indurated mass
- 3.Fistula
- +4.Circumferential retraction of the nipple

7.The widely used first investigation of choice in a lady of 25 years with lump breast is:

- +1.Ultrasonography
- 2.CT scan
- 3.MRI
- 4.FNAC

8.Which one of the following is not the treatment for mastalgia?

- 1.Evening primrose oil
- 2.Danazol
- +3.Steroids
- 4.Bromocriptine

9.Following are true for Phylloides tumour except:

- +1.Usual age of presentation is 20 years
- 2.Large tumour with bosselated surface
- 3.It may have high mitotic index
- 4.Rarely develop into sarcoma

10.Which one of the following is the treatment of choice or early breast cancer in a 30-year-old lady who is 4 months pregnant?

- 1.Chemotherapy
- 2.Tamoxifen
- 3.Local wide excision
- +4.Modified radical mastectomy

11.Which is the drug used in a patient to prevent breast cancer with positive family history but unlikely carrier of breast cancer gene?

- 1.Adriamycin
- +2.Tamoxifen
- 3.Letrozole
- 4.Trastuzumab

12.Which one of this operative step is not done in Modified radical mastectomy?

- 1.Total mastectomy
- 2.Axillary block dissection
- +3.Removal of pectoralis major
- 4.Removal of pectoralis minor

13.Following are the components of breast conservative surgery except:

- 1.Excision of tumour plus a rim of 1 cm of normal breast tissue

- 2. Axillary block dissection
- +3. Routine removal of the skin over the tumour
- 4. Sentinel node biopsy in selected patients

14. Following are true for radiotherapy in carcinoma breast except:

- 1. It should be given after breast conservative surgery
- 2. Large tumours after surgery require radiotherapy
- 3. Extensive lymphovascular invasion is an indication
- +4. Routinely given to axilla after a complete block dissection

15. Following are true for aromatase inhibitors except:

- +1. Maximum use in the premenopausal patients
- 2. Relapse free survival is prolonged
- 3. Reduction in the contralateral disease
- 4. Increase in the bone density loss

16. Which of the following is the most important aetiological factor for carcinoma breast?

- 1. Oral contraceptive pills
- +2. Childhood irradiation for Hodgkin's lymphoma
- 3. Duct ectasia
- 4. Racial factors

17. Following are true for Ductal carcinoma in situ (DCIS) except:

- 1. It is usually unilateral
- +2. Multifocal
- 3. Excision with or without radiotherapy is the treatment of choice
- 4. No role for chemotherapy

18. Following are true for inflammatory carcinoma except:

- 1. It results in blockage of dermal lymphatics
- 2. It is considered as locally advanced breast cancer
- 3. Neoadjuvant chemotherapy is the treatment of choice
- +4. Severe degree of inflammation present pathologically

19. Following are true for lobular carcinoma in situ except:

- +1. It is usually unilateral
- 2. Multifocal
- 3. Excision with or without radiotherapy is the treatment of choice
- 4. 20 % will develop into invasive carcinoma

20. Following are true about internal mammary lymph nodes except:

- 1. They drain posterior part of the breast
- 2. They communicate with subdiaphragmatic lymph nodes
- 3. They are included in the staging system now
- +4. Their involvement indicates metastatic disease

21. Following are true for sentinel node biopsy in carcinoma breast except:

- 1. Injection of patent blue localises the sentinel node
- 2. Injecting into subdermal plexus around the nipple is ideal
- 3. Hand held gamma camera detects this
- +4. It is ideal in clinically node positive axilla

22. Following is an indication for radiotherapy to chest wall in carcinoma breast except:

- 1. Extensive lymphovascular invasion
- 2. Large number of positive nodes in the axilla
- 3. Base is involved by the tumour
- +4. Skin is infiltrated

23. Following are true for tamoxifen except:

- 1. It is widely used as hormonal treatment in premenopausal patients
- 2. It decreases the annual recurrence by 25%
- 3. It also has benefit in preventing contralateral breast cancer
- +4. It is not recommended in patients who have family history of carcinoma breast but unlikely carriers of breast cancer gene

24. Treatment option for carcinoma breast in pregnancy is:

- 1. Local wide excision
- 2. Radiotherapy
- 3. Chemotherapy
- +4. Mastectomy

25. Which one of the following is not true in male breast cancer?

- 1. Most commonly it is infiltrating duct carcinoma
- +2. Mostly it presents as bleeding per nipple
- 3. Mostly mastectomy is required
- 4. Gynaecomastia is a predisposing factor

26. What is the most common type of breast cancer?

- a) Ductal carcinoma in situ
- b) Lobular carcinoma in situ
- c) Inflammatory breast cancer
- d) Invasive ductal carcinoma**

27. Which imaging test is commonly used to screen for breast cancer in asymptomatic women?

- a) Mammogram**
- b) CT scan
- c) MRI
- d) Ultrasound

28. Which type of breast cancer spreads through the lymphatic vessels in the skin of the breast?

- a) Inflammatory breast cancer**
- b) Metastatic breast cancer
- c) Ductal carcinoma in situ

d) Lobular carcinoma in situ

29. What is the most common site for breast cancer metastasis?

- a) Lungs
- b) Liver
- c) Bones**
- d) Brain

30. Which imaging test is commonly used to diagnose and stage breast cancer?

- a) Mammogram**
- b) CT scan
- c) MRI
- d) PET scan

31. What is the primary goal of surgical treatment for benign breast conditions such as fibroadenomas?

- a) Complete removal of the affected breast tissue
- b) Minimizing scarring and preserving breast appearance**
- c) Preventing recurrence of the condition
- d) Reducing breast size

32. What is the most common surgical procedure for treating early-stage breast cancer?

- a) Lumpectomy**
- b) Mastectomy
- c) Axillary lymph node dissection
- d) Sentinel lymph node biopsy

33. Which of the following is NOT a risk factor for developing breast cancer?

- a Family history of breast cancer
- b Early menarche
- c Late menopause
- d High-fiber diet**

34. What is the most common surgical procedure for treating early-stage breast cancer?

- a Lumpectomy**
- b Mastectomy
- c Axillary lymph node dissection
- d Sentinel lymph node biopsy

35. What is the most common benign breast condition?

- a Fibroadenoma**
- b Mastitis
- c Ductal ectasia
- d Phyllodes tumor

36. What is the most common surgical procedure for treating early-stage breast cancer?

- a Lumpectomy
- b Mastectomy
- c Axillary lymph node dissection**
- d Sentinel lymph node biopsy

37. Which of the following is NOT a common symptom of breast cancer?

- a Breast pain
- b Nipple discharge
- c Skin dimpling
- d Enlarged lymph nodes in the armpit**

38. What is the function of the breast?

- X - Regulating body temperature**

✓ - **Supporting the glandular structure**

✓ - **Modified sweat gland**

X - Producing hormones

X - Digesting food

✓ - **Secreting milk**

X - Filtering blood

39. Where is the nipple located?

✓ - **4th intercostal space**

X - 2nd intercostal space

X - Axilla

✓ - **Midaxillary line**

✓ - **Midclavicular line**

X - 6th intercostal space

X - Sternum

40. What is the structure that gives support to the glandular structure of the breast?

X - Areola

X - Nipple

X - Lobule

✓ - **Stroma**

✓ - **Ligaments of Cooper**

✓ - **Parenchyma**

X - Lactiferous duct

41. How many lobes are there in the breast?

X - More than 20

✓ - **Each lobe is drained by a lactiferous duct**

X - 1-5

X - 5-10

✓ - **Many lobules join to form a lobe**

X - No lobes, only lobules

✓ - **15-20**

42. Which lymph nodes are commonly involved in carcinoma of the breast?

✓ - **Central group**

X - Apical

X - Supraclavicular

X - Internal mammary

X - Posterior

✓ - **Lateral group**

✓ - **Anterior or pectoral**

43. What percentage of lymph from the breast drains into axillary nodes?

X - 100%

X - 50%

✓ - **75%**

✓ - **Internal mammary nodes receive lymphatics not only from inner quadrant but also from outer quadrant**

X - 20%

X - 5%

✓ - **Most of the lymphatics eventually drains into central to apical and then to supraclavicular lymph nodes**

44. Which artery supplies the upper part of the breast?

- ✓ - **Pectoral branches of thoraco-acromial artery**
- X - Internal mammary artery
- ✓ - **Lateral branches of posterior intercostal arteries**
- ✓ - **Lateral thoracic artery**
- X - Deep circumflex iliac artery
- X - Inferior epigastric artery
- X - Superficial epigastric artery

45. How is the breast drained by veins?

- X - Deep veins
- ✓ - **Perforating branches of internal mammary veins**
- ✓ - **Tributaries of axillary veins**
- ✓ - **Perforating branches of posterior intercostal veins**
- X - Superficial veins
- X - Renal veins
- X - Portal veins

46. What is the treatment for acute bacterial mastitis?

- X - Antibiotics are not necessary
- ✓ - **For nonlactational breast abscess, add metronidazole**
- ✓ - **The abscess should be drained-incision and drainage (I and D) under antibiotic cover**
- X - Surgical removal of the breast
- X - Radiation therapy
- X - Chemotherapy
- ✓ - **Cloxacillin, Anti-inflammatory drugs, Good support to the breast**

47. What is the classification of cystic swellings of the breast?

- X - Neoplastic: Benign - Fibroadenoma, Malignant - Ductal carcinoma in situ
- X - Retention cyst: Galactocoele
- ✓ - **Neoplastic: Benign - Phyllodes tumour, Malignant - Intracystic carcinoma**
- X - Non-neoplastic cyst: Fibroadenosis-cyclical mastalgia
- X - Inflammatory: Chronic bacterial mastitis with abscess
- ✓ - **Inflammatory: Acute bacterial mastitis with abscess**
- ✓ - **Inflammatory, Neoplastic, Non-neoplastic cyst, Retention cyst**

48. What is the most common cause of lactational mastitis?

- X - Breast trauma
- X - Hormonal imbalance
- ✓ - **Crack/fissure in the nipple**
- ✓ - **Oral cavity infection in the child**
- X - Breast cancer
- ✓ - **Retracted nipple**
- X - Excessive milk production

49. What is the classification of cystic swellings of the breast?

- X - Phyllodes tumour, Intracystic carcinoma, Galactocoele
- ✓ - **Inflammatory, Neoplastic, Non-neoplastic, Retention cyst, Other rare causes**
- X - Benign, Malignant, Simple cysts
- X - Fibroadenoma, Duct ectasia, Duct papilloma

50. What is the treatment for stage of cellulitis in acute bacterial mastitis?

- X - Incision and drainage (I and D) under antibiotic cover
- ✓ - **Cloxacillin 500 mg, 6th hourly, orally for 7-10 days**
- X - Ibuprofen 400 mg, three times a day
- X - Metronidazole 400 mg, 3 times a day for 5-7 days

51. Where is the nipple located?

- X - In the 4th intercostal space, in the midaxillary line
- X - In the 2nd intercostal space, in the midaxillary line
- X - In the 6th intercostal space, in the midclavicular line
- ✓ - **In the 4th intercostal space, in the midclavicular line**

52. Which lymph nodes are commonly involved in carcinoma breast?

- X - Posterior group
- X - Apical group
- X - Lateral group
- ✓ - **Anterior and central group**

53. What is the first lymph node draining the tumor-bearing area called?

- ✓ - **Sentinel node**
- X - Supraclavicular node
- X - Axillary node
- X - Central node

54. How much of the lymph from the breast drains into axillary nodes?

- X - 25%
- X - 100%
- X - 50%
- ✓ - **75%**

55. Which structure of the breast is responsible for secreting milk?

- a. Nipple and areola complex\
- b. Stroma\
- c. Lobule\
- d. Parenchyma of breast**

Purulent-inflammatory diseases of the lungs and pleura.

1. What time is necessary for acute lung abscess to become chronic one:

- 1). 4-6 weeks
- 2). 6-8 weeks
- 3). 8-10 weeks
- 4). More than 10 weeks

2. A 25-year-old patient complains of cough with mucopurulent sputum to 700 ml per day. As a child he was frequently hospitalized with left-sided pneumonia. He left the hospital with substantial improvement, though exacerbations often happened in spring and autumn. Over the last year his general condition has worsened: rapid fatigability, increase of phlegm amount with blood streaks, increased temperature. The medical examination shows acrocyanosis and clubbed fingers. While breathing the delayed expiration of the left side of the chest is observed.

Below the scapula angle, where the percussion sound is blurred and shortened, the breathing is weak with single coarse rales. What diseases can be suspected? 1. Acute pneumonia with abscess formation 2. Chronic pneumonia 3. Multiple bronchiectasis 4. Bronchial asthma 5. Pulmonary tuberculosis Right variants:

- 1) 1,3,5
- +2) 2,3
- 3) 1,2,4
- 4) 3,5
- 5) 1,2,5

3. Characteristic features of pulmonary gangrene are: 1. Development of the disease in organism areactivity 2. Absence of granulation bank on the border of the lung lesion 3. Extensive necrosis of the pulmonary tissue 4. Putrid infection 5. Evident intoxication Right variants:

- 1) 2 and 3
- 2) 1,2,5
- 3) 1,3,4
- 4) 3,4,5
- +5) All the variants are correct

4. A 65-year-old patient was treating herself for hyperthermia during 2 weeks. She connects her illness with supercooling, after which the temperature rose to 38.0, cough at first dry and then with mucopurulent sputum appeared. The state of health was steadily worsening; the patient felt weakness, chill and fever. Three days ago during the coughing 200 ml of fetid phlegm exuded. What disease can be suspected?

- 1. Pleural empyema
- +2. Acute lung abscess
- 3. Exacerbation of chronic nonspecific pneumonia
- 4. Lung cancer with pneumonitis
- 5. Bronchiectatic disease

5. Three days after acute lung abscess evacuation a patient felt sharp pains in the right side of the chest while coughing and short breath. Medical examination showed delayed expiration of the right side of the chest while breathing. In the upper-right parts the vesiculotympanic resonance is detected. Dull sound is heard below the scapula. Breathing in all parts of the right lung is weakened. Development of what state can be suspected?

- 1. Lung gangrene
- +2. Pyopneumothorax
- 3. Hydrothorax
- 4. Hemothorax
- 5. Pneumothorax

6. What measures should be taken at first to specify the diagnosis in patients with suspected acute lung abscess?

- 1. Pulmonary angiography
- 2. Bronchoscopy
- +3. Fluoroscopy of lungs
- 4. Lungs tomography
- 5. Lung perfusion scan

7. A 68-year-old patient was operated on blind gut cancer. 16 days later the abscess of the inferior lobe of right lung has developed. The diameter of the abscess equaled 8 cm. What treatment mode would you prefer?

- 1. Thoracotomy with lobectomy

2. Thoracotomy with abscess cavity tamponade
3. Bronchoscopy with abscess cavity catheterization
4. Indication of antibiotic therapy and proteolytic enzymes for spontaneous lancing of the abscess into the bronchus.
- +5. Percutaneous drainage of the abscess cavity (thoracocentesis)

8. A 63-year-old patient had right hemicolectomy for cancer. 12 days later the abscess of the inferior lobe of right lung has developed. The diameter of the abscess equaled 8 cm. What treatment mode would you prefer?

1. Thoracotomy with lobectomy
2. Thoracotomy with abscess cavity tamponade
- +3. Percutaneous drainage of the abscess cavity (thoracocentesis)
4. Bronchoscopy with abscess cavity catheterization
5. Indication of antibiotic therapy and proteolytic enzymes for spontaneous lancing of the abscess into the bronchus.

9. What test should be carried out in the first place if abscess of the lung is suspected?

1. Lungs tomography
2. Bronchoscopy
3. Perfusion lung scan
- +4. Biplane fluoroscopy of the lungs
5. Pulmonary angiography

10. Acute pleural empyema was detected in a 67-year-old patient who suffered from pneumonia. What measures should be taken in that case?

1. Artificial pneumothorax
- +2. Paracentetic percutaneous drainage of the pleural cavity with active aspiration
3. Thoracotomy with pleural cavity tamponade
4. Decortication of the lung and pleural cavity drainage
5. One-time puncture of the pleural cavity with aspiration of the content and following antibiotics injection

11. According to genesis acute lung abscesses can be subdivided into: 1. Postpneumatic 2. Traumatic 3. Aspiration-occlusive 4. Hematogenic-embolic 5. Lymphogenous Right variants:

- 1) 1 and 3
- 2) 1, 2, 4
- 3) 1, 2, 5
- 4) 2, 3, 4
- +5) All the variants are correct

12. Everything is characteristic of gangrene except:

1. Absence of granulation bank on the border of a lesion
- +2. Presence of pyogenic membrane
3. Spread of pulmonary tissue necrosis
4. Disease development in patients with suppressed cellular immunity
5. Lung field shadowing without clear boundaries, that is detected in roentgenograms

13. A patient with prolonged right-sided pneumonia felt a sharp deterioration of general condition. X-ray detected right lung collapse, wide horizontal fluid level and sharp shift of mediastinum shadow to the left. What is the diagnosis?

1. Acute lung abscess with burst into the bronchus

- +2. Pleural empyema
- 3. Pyopneumothorax
- 4. Pulmonary-bronchial sequestration
- 5. Thromboembolism of the pulmonary artery right branch

14. What are the indications for lobectomy in acute lung abscess? 1. Increase of purulent intoxication, despite conservative therapy 2. Repeated bleedings from a burst lung abscess 3. Development of pneumonia in a healthy lung 4. Development of acute hepatonephric insufficiency 5. Suspected cavitary form of lung cancer Right variants:

- 1) 1,2,4
- 2) 1,2,5
- 3) 1,3,5
- 4) 2,3,4
- +5) All variants are correct

15. What microorganism is the most common reason of purulent destructive process in lungs?

- 1. Streptococcus
- +2. Haemolytic staphylococcus
- 3. Colon bacillus
- 4. Viruses

16. Give the ways of pathogen penetration into the lung tissue: 1. Aspiration-inhalation 2. Hematogenic-embolic 3. Lymphogenous 4. Traumatic The right variant is:

- 1) 1,3
- 2) 2,4
- 3) 3,2
- +4) All variants are correct

17. Pyogenic abscesses situated predominantly in the right lung are explained by:

- 1. Short left main bronchus being the continuation of the trachea
- +2. Short and wide right main bronchus being continuation of the trachea
- 3. 3 lobes in the right lung
- 4. 2 lobes in the left lung

18. In the 2nd period of acute lung abscess formation X-ray examination detects:

- +1. Single or multiple cavities with horizontal fluid level and inflammatory infiltration of the surrounding pulmonary tissue
- 2. Poorly defined focal shadow of different size with irregular boundaries
- 3. Single or multiple cavities with horizontal fluid level without inflammatory infiltration of the surrounding pulmonary tissue

19. Give the complications of acute lung abscess: 1. Pyopneumothorax 2. Pleural empyema 3. Pus aspiration in healthy parts of bronchial tree with appearance of new abscesses 4. Pulmonary hemorrhage 5. Mediastinitis Right variants:

- 1) 1,3
- 2) 2,4
- 3) 5
- +4) All the variants are correct

20. What is detected with the help of X-ray examination in the first period of acute abscess formation?

- 1. Focal shadowing with horizontal fluid level
- +2. Focal shadowing of different size and intensity with poorly defined circuits and uneven boundaries
- 3. Focal shadowing with horizontal fluid level and poorly defined circuits

21. From what diseases is acute lung abscess differentiated? 1. Suppurative pulmonary cyst 2. Encapsulated pleural empyema 3. Pulmonary tuberculosis 4. Lung cancer Right variants:

- 1) 1,3
- 2) 2,4
- +3) All variants are correct

22. What is the essence of microtracheostomy by Cuno?

- 1. Percutaneous catheterization of lung abscesses
- 2. Percutaneous catheterization of bronchi
- +3. Percutaneous catheterization of trachea and bronchi
- 4. Endoscopic catheterization of lung abscesses

23. In Fowler's position a patient:

- 1. Is placed on the right side
- 2. Is placed on the left side
- +3. Is placed in a semi-upright sitting position
- 4. Is placed in posteriorly declined position

24. What is the most rational combination of drugs when combined antibioticotherapy is indicated?

- 1. Cephalosporin + penicillin
- 2. Aminoglycoside + penicillin + sulfanilamide
- +3. Cephalosporin + aminoglycoside + metronidazole

25. What is the essence of immunomodulating therapy in surgery of suppurative pulmonary diseases? 1. Indication of interleukin-2 2. Indication of roncoleukin 3. Quantum blood modification Right variants:

- 1) 2
- 2) 1
- +3) All the variants are correct
- 4) 3

26. What pulmonary disease is characterized by presence of phlegm, which gives 3-layer sediment: lower layer consists of islets of pulmonary tissue; middle layer is turbid and liquid; upper layer is mucopurulent and foamy?

- 1. Lung abscess
- 2. Multiple bronchiectasis
- +3. Pulmonary gangrene
- 4. Chronic pneumonia

27. What pulmonary disease is characterized by presence of phlegm, which gives 3-layer sediment: lower layer is purulent; middle layer consists of serous fluid; upper layer is foamy?

- +1.Lung abscess
- 2.Multiple bronchiectasis
- 3.Pulmonary gangrene
- 4.Chronic pneumonia

28.What pulmonary disease is characterized by presence of phlegm, which gives 3-layer sediment: lower layer is purulent; middle layer consists of serous fluid; upper layer is mucus?

- 1.Lung abscess
- +2.Multiple bronchiectasis
- 3.Lung gangrene
- 4.Chronic pneumonia

29.How does atelectasis of a lung lobe look like on the X-ray picture?

- +1.The affected part of the lung is reduced in volume and appears to be a triangle shadow with top in the root
- 2.The affected part of the lung is enlarged and appears as a rectangular shadow
- 3.The affected part of the lung is reduced, mediastinum is shifted to the opposite side

30.What surgical approach should be chosen in patients with bronchoectatic disease in case of limited involvement of both lungs into pathologic process?

- 1.Lung resection is performed step-by-step beginning with the lung which is affected to a lesser extent.
- +2.Lung resection is performed step-by-step or simultaneously, beginning with the lung which is the most affected.

31.What lung disease is characterized by arachnoid net symptom detected by pulmonary angiography

- 1.Abscess
- 2.Solitary cyst
- +3.Cystic disease
- 4.Chronic pneumonia

32.What is the essence of assisted thoracoscopic surgery?

- 1.Videothoracoscopy in addition to large thoracotomy
- +2.Videothoracoscopy in addition to small thoracotomy (length of incision is from 3,5 to 5cm)
- 3.Videothoracoscopy in addition to wide thoracotomy

33.How should the pleural cavity be drained in a patient with total pleural empyema with the aim of constant lavage and active aspiration?

- +1.One drain is directed to the pleural cavity through the second intercostal space along the midclavicular line, another is directed to the pleural cavity through the seventh and eighth intercostal space along the posterior axillary line
- 2.One drain is directed to the pleural cavity through the second intercostal space along the midclavicular line,another is directed to the pleural cavity through the fifth and seventh intercostal space along the midaxillary line.
- 3.One drain is directed to the pleural cavity through the second intercostal space along the anterior clavicular line, another is directed to the pleural cavity through the sixth and seventh intercostal space along the posterior axillary line.

34.What is the essence of A.V. Vishnevsky method in treatment of acute pleural empyema?

- +1. Resection of one rib with incision of 10 cm at the bottom of empyema, its emptying and filling of residual cavity with ointment impregnated tampons
- 2. Resection of two ribs with incision of 5-7 cm at the bottom of empyema cavity, its emptying and filling of residual cavity with ointment-impregnated tampons
- 3. Wide thoracotomy, empyema cavity inspection and sanitization

35. What is the essence of Konnors method in therapy of acute pleural empyemas?

- 1. Resection of one rib with incision of 10 cm at the bottom of empyema cavity, its emptying and filling of residual cavity with ointment impregnated tampons
- +2. Resection of two ribs with incision of 5-7 cm at the bottom of empyema cavity, its emptying and filling of residual cavity with ointment-impregnated tampons
- 3. Wide thoracotomy, empyema cavity inspection and sanitization

36. Give the essence of Delorme's operation:

- +1. Release of the lung from cicatrization, covering visceral pleura
- 2. Removal of commissures, situated on the lung and costal pleura
- 3. Resection of both lobes of the lung

37. What is the essence of pleurectomy in surgery of chronic pleural empyemas?

- +1. Obliteration of pleural cavity by removing of commissures, situated on the lung and costal pleura; lung smoothing
- 2. Resection of two ribs with incision of 5-7 cm at the bottom of empyema cavity, its emptying and filling of residual cavity with ointment-impregnated tampons
- 3. Wide thoracotomy, empyema cavity inspection and sanitization

38. What is the essence of resections in surgery of chronic pleural empyemas? What is the essence of resections in surgery of chronic pleural empyemas?

- +1. Removal of affected part of the lung, decortications and pleurectomy
- 2. Removal of the affected part of the lung only
- 3. Wide thoracotomy, empyema cavity inspection and sanitization

39. On the basis of clinical-roentgenological data gangrene of the middle lobe of the right lung was detected in a 40-year-old patient. Method of choice in treatment is:

- 1. Thoracocentesis
- 2. Intensive therapy with injection of antibiotics in pulmonary artery
- +3. Lobectomy
- 4. Intensive therapy with endobronchial injection of antibiotics
- 5. Pneumonectomy

40. Chronic pulmonary abscess should be differentiated from: 1. Lung tuberculosis 2. Lung cancer 3. Lung actinomycosis 4. Chronic pneumonia Right variants:

- 1) 1,4
- 2) 2,4
- 3) 3,4
- +4) 1,2,3

41. What is the most common cause of respiratory insufficiency following chest trauma?

- 1 - **Pneumothorax**
- 2 - Hemothorax
- 3 - Pulmonary contusion
- 4 - Bronchopleural fistula

42. Which type of pneumothorax requires urgent treatment?

- 1 - Simple pneumothorax
- 2 - Closed pneumothorax
- 3 - Open pneumothorax
- 4 - **Tension pneumothorax**

43. What is the treatment for hemothorax?

- 1 - **Intercostal chest tube insertion**
- 2 - Fluid restriction
- 3 - Steroids
- 4 - Chest physiotherapy

44. What is the term for alveolar collapse due to shock?

- 1 - Hemothorax
- 2 - **Shock lung**
- 3 - Pneumothorax
- 4 - Pulmonary contusion

45. What is the most common type of lung injury in deceleration injuries or crush trauma?

- 1 - Pneumothorax
- 2 - **Contusion of the lung**
- 3 - Bronchopleural fistula
- 4 - Hemothorax

46. What is the emergency treatment for tension pneumothorax?

- 1 - **Needle thoracocentesis**
- 2 - Fluid restriction
- 3 - Intercostal chest tube insertion
- 4 - Steroids

47. What is the classical sign of hemothorax?

- 1 - **Reduced chest expansion**
- 2 - Dullness to percussion
- 3 - All of the above
- 4 - Absent breath sounds on affected side

48. What is the treatment for tension pneumothorax?

- 1 - Steroids
- 2 - **Needle thoracocentesis**
- 3 - Fluid restriction
- 4 - Chest physiotherapy

49. What are the classical signs of hemothorax?

- 1 - Continuous valvular air leak
- 2 - Haemoptysis and excessive tracheobronchial secretions
- 3 - **Reduced chest expansion, dullness to percussion, absent breath sounds on affected side**
- 4 - Patchy consolidation on chest X-ray

50. Where is the ideal location for intercostal chest tube insertion?

- 1 - **Second intercostal space-anteriorly midclavicular line**
- 2 - Fifth intercostal space midclavicular line
- 3 - Fourth intercostal space midaxillary line
- 4 - Sixth intercostal space midaxillary line

51. What is the treatment for surgical emphysema?

- 1 - **Observation for localized emphysema, intercostal chest tube for pneumothorax, multiple incisions for cosmetic purposes**
- 2 - Chest physiotherapy
- 3 - Steroids
- 4 - Fluid restriction

52. What is the net result of shock lung?

- 1 - Increased capillary permeability
- 2 - Diffuse inflammation of the lung
- 3 - **Pulmonary consolidation, decrease in lung compliance, poor gas exchange**
- 4 - Alveolar collapse due to shock

53. What is the treatment for surgical emphysema?

- X - Steroids
- ✓ - **Observation for localized emphysema, intercostal chest tube for pneumothorax, multiple incisions for cosmetic purposes**
- X - Chest physiotherapy
- X - Fluid restriction

54. What are the indications for thoracotomy in the case of haemothorax?

- X - Small simple pneumothorax does not need any treatment
- ✓ - **Initial volume of blood loss is not as important as the amount of ongoing bleeding**
- X - Injury to the lung results in continuous valvular air leak
- X - Reduced chest expansion, dullness to percussion, absent breath sounds on affected side

55. What is the most common cause of penetrating thoracic wounds?

- X - Hemothorax
- ✓ - **Stab wounds**
- X - Pneumothorax
- X - Projectile wounds

56. What is the treatment for bomb fragment wounds?

- ✓ - **Urgent thoracotomy**
- X - Needle thoracocentesis
- X - Chest physiotherapy
- X - Fluid restriction

57. What is the classical sign of hemothorax?

- ✓ - **Dullness to percussion**
- X - Excessive tracheobronchial secretions
- ✓ - **Reduced chest expansion**
- X - Patchy consolidation on chest X-ray
- X - Haemoptysis

58. What is the treatment for surgical emphysema?

- ✓ - **Intercostal chest tube insertion**
- X - Fluid restriction
- X - Steroids
- X - Chest physiotherapy
- ✓ - **Observation**

59. What is the net result of shock lung?

- X - Alveolar collapse
- X - Impaired perfusion
- X - Reduction in alveolar space
- ✓ - **Decreased lung compliance**
- ✓ - **Pulmonary consolidation**

60. What are the types of surgical emphysema?

- ✓ - **Extensive**
- X - Bilateral
- X - Recurrent
- X - Chronic
- ✓ - **Localized**

61. What are the indications for thoracotomy in haemothorax?

- ✓ - **Drainage is more than 1000 ml or 100 ml each hour for 4 hours**
- X - ICD insertion is unsuccessful
- X - Initial volume of blood loss is not as important as the amount of ongoing bleeding
- X - Bleeding continues or features of shock develop
- ✓ - **Clotted haemothorax is suspected**

62. What is the most common cause of shock lung?

- ✓ - **Major chest trauma with multiple rib fractures and lung contusion**
- X - Massive blood transfusion
- X - Cardiopulmonary bypass
- X - Disseminated intravascular coagulation
- ✓ - **Septic shock and septicaemia**

63. What is the treatment for shock lung?

- ✓ - **Ventilatory support**
- X - Steroids
- ✓ - **Antibiotics**
- X - Fluid restriction
- X - Chest physiotherapy

64. Which of the following is a common disease of the lungs and pleura?

- a) Pneumonia
- b) Asthma
- c) Lung cancer
- d) All of the above**

65. What is the most common cause of pleural effusion?

- a) Infection
- b) Heart failure
- c) Cancer
- d) All of the above**

66. Which of the following is a surgical treatment for lung cancer?

- a) **Lobectomy**
- b) Chemotherapy
- c) Radiation therapy
- d) Immunotherapy

67. What is the most common symptom of chronic obstructive pulmonary disease (COPD)?

- a) **Shortness of breath**
- b) Chest pain
- c) Coughing up blood
- d) Wheezing

68.. Which of the following is a risk factor for developing lung cancer?

- a) Smoking
- b) Air pollution
- c) Family history
- d) **All of the above**

69. What is the most common type of lung cancer?

- a) **Non-small cell lung cancer**
- b) Small cell lung cancer
- c) Mesothelioma
- d) Carcinoid tumor

70. Which imaging technique is commonly used to diagnose diseases of the lungs and pleura?

- a) X-ray
- b) MRI
- c) **CT scan**
- d) Ultrasound

71. What is the primary cause of tuberculosis (TB)?

- a) **Bacteria**
- b) Virus
- c) Fungus
- d) Parasite

72. What is the most common cause of acute respiratory distress syndrome (ARDS)?

- a) **Sepsis**
- b) Pneumonia
- c) Trauma
- d) Aspiration

73. Which of the following is a symptom of pulmonary embolism?

- a) Chest pain
- b) Shortness of breath
- c) Coughing up blood
- d) **All of the above**

74. What is the primary treatment for pleural mesothelioma?

- a) **Surgery**
- b) Chemotherapy
- c) Radiation therapy
- d) Immunotherapy

75. What is the primary cause of emphysema?

- a) **Smoking**
- b) Air pollution
- c) Genetic factors

d) Occupational exposure to dust and chemicals

76. Which of the following conditions is characterized by inflammation and narrowing of the airways?

- a) **Asthma**
- b) Bronchitis
- c) Emphysema
- d) Pneumonia

77. What is the primary cause of cystic fibrosis?

- a) **Genetic mutation**
- b) Environmental factors
- c) Infection
- d) Allergies

78. Which of the following is a common symptom of lung cancer?

- a) Persistent cough
- b) Chest pain
- c) Unexplained weight loss
- d) **All of the above**

79. What is the primary cause of pulmonary fibrosis?

- a) **Unknown**
- b) Smoking
- c) Occupational exposure to toxins
- d) Genetic factors

80. Which type of lung cancer is strongly associated with smoking?

- a) **Small cell lung cancer**
- b) Non-small cell lung cancer
- c) Mesothelioma
- d) Carcinoid tumor

81. What is the primary cause of bronchiectasis?

- a) **Infection**
- b) Genetic factors
- c) Allergies
- d) Trauma

82. Which of the following is a common complication of lung transplantation?

- a) Rejection
- b) Infection
- c) Chronic rejection syndrome
- d) **All of the above**

83. What is the primary cause of pneumothorax?

- a) **Trauma**
- b) Lung disease
- c) Infection
- d) Unknown

84. Which of the following is a common symptom of lung cancer?

- ✓ - **Shortness of breath**
- ✓ - **Persistent cough**
- X - Abdominal pain
- X - Blurred vision

X - Fever

85. What is the most common cause of chronic obstructive pulmonary disease (COPD)?

✓ - **Exposure to air pollutants**

X - Genetic factors

X - Allergic reactions

✓ - **Smoking**

X - Physical inactivity

86. Which of the following is a characteristic feature of pneumonia?

X - Increased appetite

X - Muscle weakness

X - Numbness in the legs

✓ - **Chest pain**

✓ - **Inflammation of the air sacs in the lungs**

87. What is the main cause of tuberculosis (TB)?

X - Lack of physical exercise

X - Excessive alcohol consumption

✓ - **Weakened immune system**

X - High cholesterol levels

✓ - **Mycobacterium tuberculosis bacteria**

88. Which of the following is a common symptom of pleural effusion?

X - Joint pain

✓ - **Chest pain**

X - Dry cough

✓ - **Shortness of breath**

X - Blurred vision

89. What is the most common cause of lung abscess?

X - Genetic factors

X - Viral infection

X - Excessive alcohol consumption

✓ - **Aspiration of foreign material**

✓ - **Bacterial infection**

90. Which of the following is a common symptom of pulmonary embolism?

✓ - **Sudden shortness of breath**

X - Frequent urination

X - Abdominal bloating

✓ - **Chest pain**

X - Numbness in the arms

91. What is the main cause of lung nodules?

✓ - **Infections**

✓ - **Benign or malignant growths**

X - Excessive physical exercise

X - Poor diet

X - Allergic reactions

92. Which of the following is a common symptom of sarcoidosis?

✓ - **Persistent dry cough**

X - High fever

- X - Blurred vision
- X - Muscle pain
- ✓ - **Fatigue**

93. What is the main cause of mesothelioma?

- X - Physical inactivity
- ✓ - **Exposure to asbestos**
- X - Smoking
- ✓ - **Genetic factors**
- X - Allergic reactions

Vein disease of the lower extremities

1. A patient, 49 y.o., in 6 days after stomach resection concerning tumour, had pains in the left lower extremity. The patient's condition is satisfactory. At palpation stomach is soft, painless. The left lower extremity is not changed. Cutaneous covering of the right lower extremity is of a normal color, there is minor podedema in the periankle area. Arterial pulsation in the foot is distinct. Sharp pains appear at dorsal flexion of the foot. Moses symptom is positive. What complication had developed during the postoperational period?

1. Acute myositis
2. Osteoarthritis of ankle joint
- +3. Thrombosis of deep veins of the crus
4. Embolism of femoral artery
5. Lymphostasis

2. What can help to prevent from the development of acute deep vein thrombosis?

1. Antibiotic therapy
- +2. Strapping of the lower extremities
3. Vishnevsky ointment compress
- +4. Prescription of low doses of heparin
- +5. Early activation of the patient

3. What surgical prophylaxis of pulmonary embolism should be indicated for a patient with a floating thrombus in the infrarenal part of the inferior vena cava?

- +1 Cava filter placement
2. Inferior cava thrombectomy
3. Plication of the inferior vena cava under renal veins
4. Ligation of the inferior vena cava
5. Suturation of the inferior vena cava by machine stitch
6. Resection of the inferior cava

4. What are main clinical symptoms of acute stage of Paget-Schroetter disease?

1. Swelling of face, neck, upper body and the upper extremities
2. Cyanosis of face and neck
- +3. Arching pains in arms
- +4. Cyanosis of cutaneous covering of the arm, more distinct venous picture, swelling in the arm
5. Swelling in the legs

5. What symptoms are typical for acute thrombosis of deep veins of the crus? 1. Edema of the whole lower limb 2. Moderate pains in sural muscles 3. Minor edema of the foot and a lower third of the crus 4. Positive Homans' sign 5. Positive intermittent claudication

Choose the correct combination of answers:

- 1) 1, 2, 3

- +2)2, 3, 4
- 3)2, 4, 5
- 4)2 and 5
- 5)3, 5
- 6)All mentioned above

6.You have a patient's in-home visit. She is 20 y.o., 38 weeks pregnant. Having examined her, you diagnosed iliofemoral venous thrombosis. What should be indicated?

- +1.Hospitalize the patient in the maternity hospital, carry out conservative treatment indicated and controlled by vascular surgeon
- 2.To observe the patient at home, carry out conservative treatment
- 3.Indicate bed rest, dressing with Vishnevsky ointment

7.The patient, 67 y.o., suffers from varicose veins of the right lower limb. 3 days ago he had onset of acute thrombophlebitis of varicose veins of the crus. What should the conservative therapy for him?1. Heparin – up to 30000 IU per 24 hours2. Broad spectrum antibiotic3. Troxevasin ointment – locally4. Butadionum – 1 IU x 3 times per day5. Aspirin – ¼ IU x 3 times per dayChoose the correct combination of answers:

- 1)1, 3, 5
- 2)1, 2, 5
- 3)2, 3, 4
- +4)2, 3, 4, 5
- 5)1, 2, 4

8.The patient, 50 y.o., suffers from varicose veins of the lower limbs. He complains of pains, redness and indurations along superficial veins on the left crus, hyperthermia which appeared 5 days before. The condition is satisfactory. No edema and cyanosis of the lower limb. Hyperemia is detected on the inner surface of the crus, and painful taenia to middle thirds of the crus can be palpated. What would be your therapeutic approach?

- 1.Carry out angiographic research
- 2.Ligate the femoral vein
- 3.Perform operation of Troyanov-Trendelenburg
- 4.Place cava filter
- +5.Prescribe bed rest and conservative treatment; after the reduction of acute inflammation make the patient ready for the surgical

9.What symptoms are typical for varicose veins of lower extremities complicated by acute subcutaneous vein thrombophlebitis?

- +1.Sharp pains in the extremity, mostly in the area of localization of thrombophlebitis
- 2.Constant edema of the whole limb
- 3.Trophic skin disorders near medial ankle
- 4.Trophic skin disorders of a toe
- 5.Pododema and dull pains in the leg that appear in the afternoon
- 6.Dilatation of superficial veins with localized area of induration and hyperemia above it

10.What can be the place of primary formation of thrombus in the system of the inferior vena cava?1. Deep veins of the crus2. Iliofemoral venous segment3. Superficial veins of the lower extremities4. Internal iliac veins5. Veniplexes of small pelvisChoose the correct combination of answers:

- 1)1, 2, 4
- 2)1, 2, 3
- 3)2, 1, 4, 5
- +4)All answers are correct
- 5)There are no correct answers

11. The patient, 60 y.o., with coronary heart disease and cardiac fibrillation, had a sudden attack of pains in the right lower limb. Examination also revealed clearly marked edema of the right leg. Cutaneous covering of the limb are cyanotic with distinct venous picture. Palpation in the area of vascular fascicle on the thigh is painful. Homans' sign is positive. Pulsation on the foot arteries is distinct. What is the diagnosis?

1. Embolism of the right femoral artery
- +2. Acute iliofemoral venous thrombosis
3. Intermuscular hematoma
4. Acute lymphostasis
5. Leriche's syndrome

12. Acute iliofemoral venous thrombosis can be complicated by:

- +1. Pulmonary embolism
2. Muscle contracture
- +3. Post-thrombotic syndrome
4. Femoral phlegmon
5. Crush syndrome

13. Clinical symptoms of a female patient indicate acute thrombosis of deep veins of the crus. What specialized tests can specify the diagnosis?

1. Thermography
- +2. Doppler ultrasound
3. Retrograde ilio-cavography
- +4. Distal ascending phlebography
5. Transcutaneous oxygen tension

14. The patient, 70 y.o., had an emergency appendectomy for perforating appendicitis. Indicate treatment aimed at prevention of acute thrombosis of deep veins of the lower extremities in the post-operational period.

1. Exercise therapy for the lower limbs, respiratory gymnastics
2. Strapping of the lower limbs
3. Elevated position of the lower limbs
4. Early mobilization of the patient
5. Subcutaneous injection of clexane or fraxiparine

Choose the correct combination of answers:

- 1) 1,2,3
- 2) 1,3,5
- 3) 2,3,4
- 4) 2,3,5
- 5) 2,4,5
- +6) All answers are correct

15. The patient, female, 55 y.o., was admitted to the surgical department. She has been suffering from varicose veins of the right lower extremity for a long time. She complains of pains in the right thigh. The condition is satisfactory. Band of hyperemia can be seen on the medial surface from middle one-third of crus to knee joint; solid painful filamentary cord can be palpated. The limb is not edematous. Homans' sign is negative. What treatment should be indicated?

1. Strict bed rest, heparinotherapy
- +2. Bed rest, compress with heparin ointment, antibiotic therapy, disaggregants
3. Urgently perform Troyanov-Trendelenburg surgery
4. To place cava filter
5. Urgently perform Linton's operation

16.The patient, 60 y.o., had emergency appendectomy for perforating appendicitis. What would be the actions aimed at the prevention of acute thrombophlebitis of deep veins of the lower extremities during the post-operational period?

- 1.Leg strapping
- 2.Elevated position of the legs
- 3.Subcutaneous introduction of low molecular weight heparin
- 4.Early mobilization of the patient
- +5.All answers are correct

17.What methods can prevent from pulmonary embolism at floating thrombosis of the inferior vena cava?

- 1.Thrombectomy
- 2.Plication of the lower vena cava
- 3.Resection of the lower vena cava
- +4.Cava filter placement
- 5.Formation of aortocaval fistula

18.The patient, 55 y.o., is in gynaecological department. 2 days after the removal of hysteromyoma she was diagnosed iliofemoral venous thrombosis. What would be your approach?

- +1.Carry out conservative therapy in the gynaecological clinic following the consultation of angiosurgeon
- +2.If the conservative therapy is effective, to discharge the patient and prescribe ambulatory aftercare under the angiosurgeon's (surgeon's) supervision
- 3.To move the patient to the surgical hospital after the removal of the sutures
- 4.To question the transfer of the patient to vascular department for operative treatment
- 5.Urgently transfer the patient to the surgical department for operative treatment

19.A patient, 65 y.o., with gross obesity, complains of severe pains in the left crus that appeared 8 hours ago and increased steadily. The left crus is increased, it is edematous and cyanotic. What supposed diagnosis is the most probable ?

- 1.Arterial embolism
- 2.Arterial thrombosis
- +3.Venous thrombosis
- 4.Erysipelatous inflammation
- 5.Osteomyelitis

20.What symptom is not typical for acute thrombophlebitis of superficial veins?

- 1.Hyperemia of skin along the vein
- 2.Induration along the vein
- +3.Significant limb enlargement
- 4.Topical temperature rise
- 5.Pains along the vein
- 6.No pulsation of the dorsal foot artery

21.The patient, 50 y.o., with varicose veins of the lower extremities, was admitted to hospital with complaints of pains, redness and induration along superficial veins on the left thigh and crus. Examination revealed hyperemia on the inner surface of the left thigh and crus along varicose veins, and painful taenia can be palpated to the middle third of the thigh. What would be your approach?

- 1.Prescribe strict bedrest, conservative treatment
- 2.Carry out angiography

- 3.Ligate the femoral vein
- +4.Perform Troyanov-Trendelenburg's, Madelung's
- 5.To place cava filter

22.What factors participate in the development of thrombophlebitis of deep veins of limbs?

- +1.Slowing of blood flow in the venous system of lower extremities
- +2.Damaging the endothelium of the varices
- 3.Shunt from deep veins into superficial ones through perforants
- 4.Relative valvular insufficiency of deep veins
- 5.Systemic arterial hypertension
- 6.Inconsistency of ostial valve

23.Paget-Schroetter syndrome is:

- +1.Acute venous thrombosis of subclavian and axillary veins
- 2.Chronic venous insufficiency after acute venous thrombosis of subclavian and axillary veins
- 3.Acute thrombosis of the upper vena cava
- 4.Post-thrombotic syndrome of the upper limbs
- 5.This syndrome is not related with venous pathology

24.What should be performed for diagnosing Paget-Schroetter disease?

- 1.Roentgenography of cervical and thoracic part of the spine
- +2.Doppler ultrasound
- 3.Aorto-arteriography
- +4.Plebography
- 5.All mentioned above

25.Which of the following is not a main symptom of subclavian-axillary venous thrombosis?

- 1.Fatigue in the arm when working
- 2.Swelling in the arm
- 3.Cyanosis of cutaneous covering of forearm and shoulder
- +4.Elbow joint enlargement
- 5.Arching pains in the limb

26.Triad of thrombosis of Virchow includes:

- +1.Slowdown of the blood flow in the vascular bed
- 2.Pathologic arteriovenous fistulas
- 3.Electrolytic blood disturbances
- 4.Increase in arterial influx
- 5.Necrotic changes of soft tissues
- 6.Reduction of oxygen saturation

27.Venous gangrene is:

- 1.Takayasu's syndrome
- 2.Buerger's disease
- 3.Denerey's syndrom
- +4.Gregoir's disease
- 5.Klippel-Trenaunay's syndrome

6.Parks-Weber-Rubashov's disease

28.What factor(s) does(do) not promote the better venous blood flow in the lower limbs during the postoperational period

- 1.Early wake-up
- 2.Strapping of the crus
- 3.Elevated position of legs
- +4.Prolonged and strict bed rest
- 5.Sural muscle contraction
- 6.Massage of the lower limbs

29.Because of what can phlebothrombosis of the lower limbs be dangerous?

- 1.Renal infarct
- +2.Infarct pneumonia
- 3.Thromboembolism of mesenteric vessels
- 4.Pylephlebitis
- +5.Pulmonary embolism

30.The patient, 38 y.o., is suspected in having thrombosis of deep crural veins. What methods can confirm the diagnosis and will enable to define topical diagnosing of the lesion?

- 1.Sphygmography
- 2.Capillaroscopy
- 3.Reovasography
- 4.Phlebtonometry
- +5.Radiotracer methodology with marked fibrinogen
- +6.Ascending distal functional phlebography

31.Which of the following does not refer to complications of varicose veins?

- +1.Gangrene of foot and crus
- 2.Thrombophlebitis of superficial veins
- 3.Bleeding from superficial varicose veins
- 4.Trophic crus ulcers
- 5.Acute thrombophlebitis of varicose veins with abscess formation

32.Where does great subcutaneous vein interflow with common femoral vein?

- +1.From 2- 3 cm above inguinal ligament to 5 cm below it
- 2.6 cm below inguinal ligament
- 3.At the same level as inguinal ligament
- 4.From the level of inguinal ligament to 7 cm distal from it
- 5.From 1 cm above inguinal ligament to 3 cm below it

33.Which of the following can be tributary of the great subcutaneous vein near saphenous opening?

- +1.Superficial epigastric, superficial iliac circumflex, and superficial external pudendal veins
- 2.Posteromedial, superficial epigastric, superficial iliac circumflex veins
- 3.Anterolateral, superficial epigastric, superficial iliac circumflex veins

34.What veins form the short saphenous vein?

- 1.Lateral marginal vein, plantar vessels, posteromedial vein
- +2.Lateral marginal vein, plantar vessels and deep anastomosis of external plantar vein
- 3.Superficial iliac circumflex, anterolateral, superficial epigastric veins

35.What is phlebography of lower extremities performed for?

- 1.To detect arteriovenous fistulas
- +2.To assess the state of valvular apparatus of deep communicating veins, to assess the patency of deep veins
- 3.Only to assess patency of deep veins

36.What changes in venous hemodynamics can be observed at high venovenous blood discharge (reflux)?

- +1.Reflux from deep venous network through inconsistent ostial valve into the system of greatsubcutaneous vein
- 2.Reflux into superficial venous network through inconsistent communicating veins
- 3.Reflux into superficial venous network through arteriovenous anastomoses

37.The compensation stage of venous hemodynamics is characterized by:

- +1.Pain, heavy aching legs, annoying pains in the areas of varicose veins
- 2.Complaints mentioned above plus edemas of foot and malleolus which disappears after night's rest
- 3.Trophic disorders of crus skin appear against a background of varicose subcutaneous veins

38.Indicate the main symptoms of decompensation stage of venous hemodynamics:

- +1.Trophic disorders of crus skin appear against a background of varicose subcutaneous veins
- 2.Pain, heavy legs after physical trainings
- 3.Pain, heavy aching legs, annoying pains in legs, edemas of foot and malleolus

39.Give the fullest characteristics of ulcers at varicose veins.

- +1.They are situated on the inner side of crus above the ankle; more seldom they can be situate behind external crus in the site of previous dermatitis and eczema exposure. Ulcers are plane, solitary painful, with abundant purulent discharges, irregular-shaped
- 2.They are situated on the lateral side of the crus, above the ankle; have clear boundaries. Ulcers are deep, often numerous, not painful, with purulent discharges
- 3.They are circular, numerous, with abundant purulent discharges

40.What clinical symptoms are typical for Parks-Weber-Rubashov syndrome?

- 1.Diffuse varicose subcutaneous deep veins, lengthening of the extremity, hypertrichosis, ulcers, temperature drop on the affected side, low oxygen saturation of venous blood from subcutaneous veins
- 2.Local subcutaneous varices, limb reduction, temperature rise, no ulcers
- 3.Diffuse varicose subcutaneous veins, occlusion of main arteries of the lower limbs
- +4.Diffuse varicose subcutaneous veins, hypertrophy of the extremity affected, hypertrichosis, ulcers, temperature rise on the side of the affection, high oxygen saturation, systolic murmur over the arteriovenous anastomosis

41.What are the most typical symptoms of Klippel-Trenaunay syndrome?

- +1.Triad symptoms: vascular pigmentary spots on the skin of the lower extremities, varicose veins on the lateral surface of limbs, increased limb
- 2.Vascular pigmentary spots on the skin of the lower extremities, limb reduction

- 3.Varicose subcutaneous veins and occlusion of main arteries
- 4.Congenital arteriovenous fistulas

42.At what age do anatomical changes of lower limbs mostly occur in Park-Weber syndrome?

- 1.In adulthood
- 2.Before 20 years old
- +3.Before 10-12 years old
- 4.Before 14-16 years old
- 5.Before 6-8 years old

43.What is the essence of phlebosclectosing therapy of varicose veins?

- 1.Electrocoagulation of subcutaneous veins
- +2.Injection of substances causing aseptic inflammation through the venous vessel lumen followed by sclerosing and lumen obliteration
- 3.Injection of substances causing aseptic inflammation through the venous vessel lumen followed by lumen obliteration and electrocoagulation

44.Troyanov–Trendelenburg operation during phlebectomy implies:

- 1.Ligation of communicating veins on the crus
- 2.Removal of subcutaneous veins by probes (either from metal or from plastic)
- +3.Transection of great saphenous vein in the place it flows into femoral vein with ligation and transection of all subcutaneous veins draining into v. saphena magna

45.Babcock’s surgery implies:

- 1.Crossectomy
- 2.Ligation of communicating veins on the crus
- 3.Removal of varicose subcutaneous veins out from small incisions of 4–8 cm
- +4.Removal of subcutaneous veins by probes out from two incisions

46.What does method of ligation of communicating veins according to Linton imply?

- 1.Suprafascial ligation of communicating veins
- 2.Resection of communicating veins
- +3.Subfascial ligation of communicating veins
- 4.Sub- and suprafascial ligation of communicating veins

47.What type of ligation of communicating veins would be appropriate for marked trophic changes of skin and subcutaneous fat in crus?

- 1.Sokolov-Clapp’s technique
- 2.Troyanov-Trendelenburg surgery
- +3.Endoscopic transection of communicating veins or Felder’s method
- 4.Schede’s method

48.Operation of Sidorina in varicose surgery implies

- +1.«Tunnel» veins removal
- 2.Phlebectomy in solid incision in medial crus

3. Removal of varicose veins out from 4-6 cm incision of skin and subcutaneous fat

49. What medicines have phlebodynamic effect?

- +1. Troxevasin, venoruton, detralex, endotelon, aescine
- 2. Troxevasin, trental, venoruton, detralex
- 3. Venoruton, phenylin, trental, troxevasin
- 4. Detralex, endotelon, aescine, glivanol, aspirin, heparin

50. In diagnostics of what types of veins are computed tomography and magnetic resonance imaging informative?

- 1. Superficial and deep veins
- 2. Only superficial veins
- +3. First of all in diagnostics of major venous vessels (vena cava, subclavian, iliac veins)

51. What test can be used to estimate the state of deep veins?

- 1. Arteriography
- +2. Functional phlebotoonometry
- 3. Capillaroscopy
- 4. Test Pratt-2

52. Is it true that non-direct communicating veins connect subcutaneous veins with muscular, which directly or indirectly interconnect with deep veins?

- +1. Yes
- 2. No

53. Is it true that direct communicating veins connect subcutaneous veins with deep ones?

- +1. Yes
- 2. No

54. By how many per cents does the pressure increase in deep venous system of the lower extremities during the functional phlebotoonometry at Valsalva maneuver in patients with consistent valvular apparatus of deep and communicating veins?

- 1. By 20%
- 2. By 15-20%
- +3. By 10-12%

55. What functional tests enable to assess the patency of deep veins of lower extremities?

- 1. Pratt-2, Talman's
- 2. Hackenbruch- Sicard, Shwarz
- 3. Pratt-2, Barrow-Cooper-Sheinis
- +4. Mayo-Pratt's, Delbe-Perthes

56. What information is obtained by distal phlebography?

- 1. Informs on the state of valves of deep veins

- 2. Informs on the patency of deep veins and state of its valves
- +3. First of all it informs on the patency of deep veins and the state of valvular apparatus of communicating veins
- 4. It is not used for the assessment of the state of venous system of lower extremities

57. What are the main factors of varicose veins development?

- +1. Prolonged standing, rise in intra-abdominal pressure, heredity
- 2. Prolonged standing, non-functioning arteriovenular anastomoses
- 3. Physical load on legs, weakness of muscular elastic fibers of venous wall

58. What changes at high venovenous reflux are observed?

- 1. Reflux into superficial venous network through arteriovenous anastomoses
- +2. Reflux into superficial venous network through inconsistent communicating veins of crus and foot
- 3. Reflux from deep venous network through inconsistent ostial valve into the system of great subcutaneous vein

59. Indicate the main symptoms of subcompensation stage of venous hemodynamics

- 1. Pain, heavy aching legs, annoying pains in the areas of varicose veins
- +2. Complaints mentioned above plus edemas of foot and malleolus which disappears after night's rest
- 3. Trophic disorders of crus skin appear against a background of varicose subcutaneous veins

60. What are trophic tissue disorders at varicose disorders of lower extremities characterized by?

- 1. Drop in temperature, trophic disorders of lower limbs
- +2. Brown induration of skin, hair loss, dry and wet tetter, trophic ulcers
- 3. Hypertrophy and lengthening of the extremity affected, hypertrichosis, ulcers

61. Postthrombotic diseases of lower extremities is the result of:

- 1. Superficial veins thrombosis
- 2. Varicose superficial veins dilatation
- +3. Deep veins thrombosis
- 4. Great saphenous vein ligation
- 5. Main artery thrombosis

62. The complex of symptoms, developing 2 months later the recent acute deep veins thrombophlebitis of lower extremities is called:

- +1. Postthrombophlebitic disease
- 2. Gregoir's disease
- +3. Postthrombophlebitic syndrome
- 4. Postcholecystectomy syndrome
- 5. Parks-Weber syndrome
- 6. Postthrombotic occlusion of peripheral arteries
- 7. Burger's disease

63. Postthrombophlebitic disease is most evident after:

- 1. Thrombophlebitis of popliteal-tibial segment
- 2. Thrombophlebitis of femoral-tibial segment
- +3. Thrombophlebitis of iliofemoral segment

4. Thrombophlebitis of ilio caval segment
5. Thrombophlebitis of inferior vena cava

Gastrointestinal bleeding.

1. In terms of location, gastrointestinal (GI) bleeding is generally classified as which of the following?

- +1 upper and lower
- 2. internal and external
- 3. acute and chronic
- 4. hematemesis and hematochezia

2. Upper gastrointestinal bleeding may be caused by all of the following conditions EXCEPT:

1. Mallory-Weiss tear (tears where the esophagus joins the stomach)
2. Gastritis
- +3 Colitis
4. peptic ulcers

3. What is the most common cause of upper gastrointestinal bleed?

1. Cancers
- +2 peptic ulcers
3. Esophagitis
4. fistulas

4. Which of the following conditions is NOT a cause of lower gastrointestinal bleeding?

1. colorectal cancer
2. Hemorrhoids
3. esophageal varices
- +4 diverticular disease

5. Which of these listed is the medical term for vomiting of blood?

- +1. hematochezia
- 2. hematuria
- 3. hematemesis
- 4. hemoptysis

6. Apart from blood in the stool, which of the following may cause black, tarry stools?

1. Use of beets and red food dyes.
2. Diarrhoea.
- +3. Gall stones, resulting in obstruction to the flow of bile into the GI tract.
4. Use of iron pills, Pepto-Bismol or blueberries.

7. Which of these drugs can predispose to gastrointestinal bleeding?

1. milk of magnesia
- +2. colace/dioctil
3. ibuprofen
4. dulcolax

8. Which of the following microorganisms is a common cause of gastric ulcers?

- 1.clostridium
- +2.helicobacter pylori (H-Pylori)
- 3.escherichia coli
- 4.salmonella

9.Not every person with a gastrointestinal bleed will experience a change in stool color. For some individuals, blood in the stool can only be detected through laboratory assessment for occult blood. True or False?

- +1.True
- 2.False

10.Which of the following procedures can be done to determine the cause and sometimes stop upper gastrointestinal bleed?

- 1.bronchoscopy
- 2.esophagogastroduodenoscopy
- 3.colonoscopy
- +4.sigmoidoscopy

11.Which of these causes of lower gastrointestinal bleed can lead to colorectal cancer if not detected and treated early?

- +1.colon polyps
- 2.vascular malformation
- 3.diverticulitis
- 4.hemorrhoids

12.Treatment of massive gastrointestinal bleeding may include all of the following EXCEPT:

- 1.antihypertensive medication
- 2.medications to reduce stomach acid
- 3.transfusion of blood and blood products
- +4.emergency surgery

13.Prevention of gastrointestinal bleed may include all of the following EXCEPT:

- 1.Stress management
- 2.Use of non steroidal anti inflammatory drugs before meals.
- 3.Life style changes such as alcohol and smoking cessation.
- +4.Use of antibiotics to treat helicobacter pilori infection.

14.Which of the following therapies is proven to reduce mortality and morbidity in bleeding peptic ulcers?

- +1.Endoscopic procedures
- 2.H2 antagonists
- 3.Proton pump inhibitors
- 4.Octreotide
- 5.Antacids

15.Which is not true of bleeding oesophageal varices?

- 1.Mortality approaches 25-40%

- 2. Use of octreotide IV is as effective as sclerotherapy controlling bleeding in 74-92% of cases.
- 3. Sclerotherapy has a high rate of complications (40%) including perforation, aspiration, pyrexia, chest pain, ulcers and strictures.
- 4. Endoscopic variceal ligation is as effective as sclerotherapy with fewer side effects.
- +5. Use of the sengstaken-blackmore tube is effective in controlling severe bleeding, is easy to insert and has almost no complications.

16. Which is the most common cause of lower GI bleed under 50 years of age?

- 1. Anal fissures
- 2. Benign polyps
- +3. Haemorrhoids
- 4. Inflammatory bowel disease
- 5. Diverticulosis

17. Which is not a characteristic of diverticulosis?

- 1. Acquired defects in bowel wall
- 2. More common in distal colon
- +3. Bleeding usually intermittent
- 4. Significant bleeding usually arises from right side of colon
- 5. Occur at point of entry nutrient vessel

18. A 55 year old woman presents with intermittent bright red PR bleeding. On examination she is stable, and PR shows small external haemorrhoid. What is appropriate treatment for this lady?

- 1. Reassure, prescribe treatment for haemorrhoids
- 2. Refer to surgeons for elective haemorrhoidectomy
- +3. Prescribe treatment for haemorrhoids, and arrange outpatient colonoscopy with surgical follow-up.
- 4. No further treatment necessary.
- 5. Admit to hospital for colonoscopy or double contrast barium enema.

19. Which is not a predisposing factor for GORD?

- 1. High fatty food intake
- +2. Cholinergic drugs
- 3. Caffeine
- 4. Nicotine
- 5. Gastric outlet obstruction

20. Which is the most common cause of oesophageal perforation?

- +1. Iatrogenic causes
- 2. Trauma
- 3. Boerhaave's syndrome
- 4. Foreign body
- 5. Tumour

21. Which is incorrect of swallowed foreign bodies?

- 1. 80% occur in children
- 2. 97% of adults with distal meat impactions have pathological conditions so all need Barium swallow studies.
- 3. The most common area for FBs to be found in children is at the cricopharyngeal narrowing (C6).

4.Glucagon is used to relax smooth muscle but is contraindicated in phaeochromocytoma.
+5.Carbonated drinks can be used safely in upper oesophageal obstructions to try and dilate oesophagus to allow FB to pass.

22.Which of the following FBs™s needs to be removed as an emergency?

- 1.50 cent coin in the stomach
- 2.50 cent coin in the oesophagus
- 3.lithium button battery in stomach
- +4.lithium button battery in oesophagus
- 5.5 grams of cocaine in latex packaging sitting in small intestine

23.Which is the most common cause of peptic ulcer disease of the following?

- 1.Smoking
- +2.NSAIDs™s
- 3.Zollinger-Ellison syndrome
- 4.Ethanol excess
- 5.Family hx of PUD

24.Which is not true of H.pylori infection?

- +1.80% of patients with chronic infection will develop ulcers
- 2.the most common cause of peptic ulcer disease
- 3.it is a risk factor for adenocarcinoma of the stomach
- 4.IgG antibody test will remain positive for up to 2 years post eradication limiting its usefulness
- 5.The CLO test is approx 90% sensitive and 100% specific for H.pylori

25.Which is not correct regarding treatment of peptic ulcer disease?

- 1.Antacids are as effective as H2 antagonists in healing ulcers
- 2.Proton pump inhibitors show more rapid healing and pain relief over 2-4 weeks compared to H2 antagonists.
- 3.Colloidal bismuth subcitrate will suppress H.pylori and chelate with the base of the ulcer to aid healing.
- +4.H.pylori eradication with omeprazole, Amoxil and metronidazole requires only one week of treatment.
- 5.Misoprostal is indicated for prevention of NSAID induced ulcers, when treatment necessary with NSAIDs™s.

26.Which is the most common complication of Peptic ulcer disease?

- 1.Perforation
- 2.Gastric outlet obstruction
- 3.Penetration
- +4.Haemorrhage
- 5.All are uncommon occurring in less than 5% of patients.

27.Which is incorrect regarding acute appendicitis?

- 1.Between 50-75% of patients present with the classical symptoms and signs of acute appendicitis.
- 2.Presence of a good appetite makes appendicitis unlikely
- 3.Rovsings sign may be helpful in diagnosis especially in obese patients
- +4.PR tenderness is seen in 90% of patients with acute appendicitis
- 5.Vomiting prior to onset of pain makes appendicitis unlikely

28. Which is incorrect regarding investigation of acute appendicitis?

- 1. The WCC is increased in 70-90% of patients.
- 2. CRP will usually be normal in early appendicitis
- 3. USS is operator dependant but has sensitivity of around 80-90%.
- 4. USS sensitivity is lowered to around 30% in cases of gangrenous and perforated appendicitis.
- +5. CT is the investigation of choice in children due to lower sensitivity in this group with USS.

29. Which is the least common cause of large bowel obstruction?

- 1. Neoplasm
- 2. Diverticulitis
- 3. Volvulus
- +4. Adhesions
- 5. Faecal impaction

30. Which of the following features suggests a complete large bowel obstruction?

- 1. Presence of multiple loops of bowel with plicae circularis on AXR
- 2. Biliious vomiting
- 3. Distended abdomen, with high pitched bowel sounds with normal flatus.
- 4. Empty rectum on PR exam
- +5. Dilated loops of bowel with haustra visible

31. What is the upper limit of normal for large bowel?

- 1) 3cm
- 2) 4cm
- +3) 5cm
- 4) 6cm
- 5) 10cm

32. A 50 year old woman presents with small bowel obstruction, and on examination has a hard tender mass lateral and inferior to symphysis pubis. What is this most likely to be?

- 1. direct inguinal hernia
- 2. indirect inguinal hernia
- +3. femoral hernia
- 4. obturator hernia
- 5. spigelian hernia

33. Which of the following hernia is most likely to incarcerate and strangulate?

- 1. Congenital umbilical hernia
- 2. Spigelian hernia
- 3. Direct inguinal hernia
- 4. Sportsman hernia
- +5. Indirect inguinal hernia

34. Which blood test is commonly used to assess the severity of gastrointestinal bleeding?

- a) Complete blood count (CBC)**
- b) Liver function tests
- c) Coagulation profile

d) Serum electrolytes

35. What is the first-line treatment for acute upper gastrointestinal bleeding due to esophageal varices?

- a) Proton pump inhibitors (PPIs)
- b) Endoscopic band ligation**
- c) Transjugular intrahepatic portosystemic shunt (TIPS)
- d) Sclerotherapy

36. Which imaging test is commonly used to locate the source of lower gastrointestinal bleeding?

- a) MRI
- b) CT angiography
- c) Colonoscopy**
- d) Barium enema

37. Which of the following conditions is NOT a common cause of lower gastrointestinal bleeding?

- a) Diverticulosis
- b) Inflammatory bowel disease
- c) Gastric ulcers**
- d) Colorectal cancer

36. What is the primary goal of surgical treatment for severe gastrointestinal bleeding?

- a) Control bleeding and stabilize the patient**
- b) Remove the entire affected organ
- c) Repair damaged blood vessels
- d) Prevent future bleeding episodes

37. Which type of surgery involves removing a portion of the stomach to treat severe cases of gastrointestinal bleeding?

- a) Gastrectomy**
- b) Vagotomy
- c) Fundoplication
- d) Laparoscopy

38. What is the most common cause of lower gastrointestinal bleeding in adults?

- a) Hemorrhoids
- b) Angiodysplasia**
- c) Colonic polyps
- d) Anal fissures

39. What is the primary role of endoscopy in the management of gastrointestinal bleeding?

- a) Diagnose the cause and location of bleeding**
- b) Administer medications to stop bleeding
- c) Perform surgical interventions to control bleeding
- d) Assess the patient's overall condition

40. Which medication is commonly used to reduce blood clotting and prevent re-bleeding in patients with gastrointestinal bleeding?

- a) Heparin
- b) Warfarin
- c) Aspirin
- d) Tranexamic acid**

41. What is the primary cause of acute lower gastrointestinal bleeding in children?

- a) Meckel's diverticulum**
- b) Inflammatory bowel disease
- c) Intussusception
- d) Colonic polyps

42. Which surgical procedure involves creating a new connection between two segments of the intestine to bypass a

diseased or obstructed area in patients with lower gastrointestinal bleeding?

- a) Ileostomy
- b) Colostomy
- c) Bowel resection
- d) Anastomosis**

43. What is the primary goal of medical management for patients with acute gastrointestinal bleeding?

- a) Control bleeding and stabilize the patient's condition**
- b) Perform emergency surgery to remove the source of bleeding
- c) Administer antibiotics to prevent infection
- d) Provide supportive care until bleeding stops on its own

44. Which diagnostic test allows direct visualization of the entire colon to detect and treat sources of lower gastrointestinal bleeding?

- a) MRI
- b) CT scan
- c) Colonoscopy**
- d) Barium enema

45. What is the primary cause of chronic upper gastrointestinal bleeding in adults?

- a) Esophageal varices
- b) Gastric ulcers**
- c) Mallory-Weiss tear
- d) Hiatal hernia

46. Which medication is commonly used to reduce stomach acid production and promote healing in patients with upper gastrointestinal bleeding due to peptic ulcer disease?

- a) Proton pump inhibitors (PPIs)**
- b) H2 blockers
- c) Antacids
- d) Antibiotics

47. What is one potential complication of severe gastrointestinal bleeding that requires urgent surgical intervention?

- a) Pneumonia
- b) Sepsis**
- c) Osteoporosis
- d) Anemia

48. Which surgical procedure involves removing part or all of the colon to treat severe cases of lower gastrointestinal bleeding?

- a) Colectomy**
- b) Ileostomy
- c) Bowel resection
- d) Colostomy

49. What is one potential cause of upper gastrointestinal bleeding in patients with liver cirrhosis?

- a) Portal vein thrombosis
- b) Hepatic encephalopathy
- c) Esophageal varices**
- d) Cholecystitis

50. What is the overall mortality rate from acute upper gastrointestinal bleeding?

- X - 10%
- X - 50%
- ✓ - 20%**
- X - 30%
- ✓ - 5%**

51. Which blood product is commonly transfused to replace lost blood volume in patients with severe gastrointestinal bleeding?

- a) Platelets
- b) Fresh frozen plasma (FFP)
- c) Packed red blood cells (PRBCs)**
- d) Cryoprecipitate

52. What is one potential complication of untreated or severe upper gastrointestinal bleeding?

- a) Pancreatitis
- b) Peritonitis**
- c) Pneumothorax
- d) Kidney stones

53. What is one potential cause of upper gastrointestinal bleeding in patients with chronic kidney disease?

- a) Uremic gastritis**
- b) Renal artery stenosis
- c) Nephrotic syndrome
- d) Renal cell carcinoma

54. Which medication is commonly used to promote blood clotting and prevent re-bleeding in patients with gastrointestinal bleeding?

- a) Heparin
- b) Warfarin
- c) Aspirin
- d) Tranexamic acid**

55. What is one potential complication of untreated or severe lower gastrointestinal bleeding?

- a) Pancreatitis
- b) Peritonitis
- c) Pneumothorax**
- d) Kidney stones

56. What is one potential cause of upper gastrointestinal bleeding in patients with chronic liver disease?

- a) Portal vein thrombosis
- b) Hepatic encephalopathy
- c) Esophageal varices**
- d) Cholecystitis

57. What is one potential cause of lower gastrointestinal bleeding in infants and young children?

- a) Meckel's diverticulum**
- b) Ulcerative colitis
- c) Crohn's disease
- d) Intussusception

58. What are the three most common causes of acute upper gastrointestinal bleeding?

- ✓ - NSAID-induced bleeding**
- X - Gallstones
- ✓ - Chronic peptic ulceration**
- X - Gastric varices
- X - Colon polyps

59. What is the investigative procedure of choice for the diagnosis of obscure bleeding from the small intestine?

- X - MRI
- X - CT scan
- ✓ - Mesenteric angiography**
- ✓ - Small bowel capsule endoscopy**
- X - Colonoscopy

60. What is the main problem with bleeding peptic ulcers?

- X - Digestion of clots by pepsin

- X - Increased acid secretion
- ✓ - **Tendency to rebleed**
- ✓ - **Impaired platelet aggregation and blood coagulation**
- X - Inability to heal

61. Which group of people has the highest risk of gastrointestinal bleeding from NSAID usage?

- X - Pregnant women
- ✓ - **Patients with a previous history of gastrointestinal events**
- ✓ - **Elderly (> 65 years)**
- X - Children
- X - Young adults

62. What is the incidence of bleeding and perforation from NSAID usage according to the Nottingham study?

- X - 1:2000 and 1:20000 prescriptions
- X - 1:1000 and 1:10000 prescriptions
- X - 1:50000 and 1:1000 prescriptions
- ✓ - **1:6000 and 1:33000 prescriptions**
- ✓ - **1:133000 and 1:6000 prescriptions**

63. What is the condition called when an arteriole protrudes through a mucosal defect in the gastrointestinal tract?

- ✓ - **Dieulafoy's lesion**
- X - Gastric polyp
- X - Cirrroid aneurysm
- X - Gastrointestinal varices
- ✓ - **Exulceratio simplex**

64. What is the treatment of choice for Dieulafoy's lesion?

- ✓ - Therapeutic endoscopy
- X - Emergency laparotomy
- X - Radiation therapy
- X - Chemotherapy
- ✓ - Angiographic therapeutic embolization

65. What is the most common cause of portal hypertensive gastropathy?

- ✓ - **Cirrhosis**
- X - Colon polyps
- ✓ - **Portal hypertension**
- X - Gallstones
- X - Gastric ulcers

66. What is the first line of management for gastric antral vascular ectasia (GAVE) syndrome?

- X - Radiation therapy
- ✓ - **Surgery**
- X - Antibiotics
- ✓ - **Endoscopic therapy**
- X - Chemotherapy

67. Which factor may cause recurrent haemorrhage in bleeding peptic ulcers?

- a. Low platelet count
- b. Impaired blood coagulation
- c. **Excessive acid secretion**
- d. Pepsin digestion of clots

68. Which of the following medications has been shown to have the highest risk of gastrointestinal bleeding?

- a. Indometacin
- b. Naproxen
- c. Aspirin**
- d. Nabumetone

69. What is the characteristic feature of Dieulafoy's lesion?

- a. Protrusion of an arteriole through a mucosal defect**
- b. Presence of oesophagogastric varices
- c. Damage to the gastroduodenal mucosa
- d. Tortuous submucosal artery

70. What is the treatment of choice for extragastric Dieulafoy lesions?

- a. Electrocoagulation
- b. Sclerotherapy
- c. Heater probe
- d. Angiographic therapeutic embolization**

71. Which condition is associated with acute or chronic repeated gastrointestinal blood loss?

- a. Chronic peptic ulcers
- b. Portal hypertensive gastropathy**
- c. Gastric antral vascular ectasia
- d. Tumours

72. What is the pathogenesis of portal hypertensive gastropathy?

- a. Regulation of gastric nitric oxide
- b. Prostaglandin production
- c. Tumour necrosis factor production
- d. All of the above**

73. What are the endoscopic features of gastric antral vascular ectasia (GAVE) syndrome?

- a. Reddened and oedematous gastric mucosa
- b. Dilated, tortuous vessels with a watermelon appearance**
- c. Mosaic-like pattern and red point lesions
- d. Hyperaemic antral folds

74. What is the first-line management for GAVE syndrome?

- a. Endoscopic therapy**
- b. Surgical treatment
- c. Beta-blockers
- d. Blood transfusion

75. What are the common causes of acute haemorrhage from tumours in the gastrointestinal tract?

- a. Benign lesions
- b. Carcinoma and lymphomas**
- c. Neurofibromatosis and smooth muscle tumours
- d. Gastrointestinal stromal tumours

76. When does surgical intervention become necessary for chemotherapy-induced bleeding from a gastrointestinal tumour?

- a. When there is a risk of graft infection
- b. For resection of the tumour**
- c. When there is severe pain
- d. As a last resort after medical therapy fails

77. What is the treatment approach for stress ulceration causing acute bleeding?

- a. Conservative treatment with PPI and sucralfate**
- b. Surgical treatment
- c. Endoscopic therapy
- d. Intravenous antibiotics

78. What is the most common cause of aortoenteric fistula?

- a. Aortic replacement with prosthetic grafts**
- b. Spontaneous rupture of the aorta
- c. Thrombocytopenia induced by chemotherapy
- d. Gastric outlet obstruction

79. Which condition rarely causes acute dilatation of the stomach?

- a. Gastric outlet obstruction
- b. Aortoenteric fistula
- c. Gastrointestinal bleeding
- d. Anorexia nervosa**

80. What is the most appropriate treatment for acute dilatation of the stomach?

- a. Insertion of a nasogastric tube**
- b. Administration of oxygen by nasal catheter
- c. Crystalloid solutions for hypovolaemia correction
- d. Bronchoscopic suction and lavage

81. When is therapeutic nasogastric suction indicated?

- a. After elective surgery
- b. In cases of acute abdominal conditions**
- c. In patients with excessive ventilation
- d. As a prophylactic measure

82. What is the recommended type of nasogastric tube for therapeutic nasogastric suction?

- a. Single-lumen Ryle's tube
- b. Salem sump suction tube**
- c. Nasal catheter
- d. Flexible endoscopy tube

83. Which phase in the management of bleeding patients involves resuscitation?

- a. Resuscitation**
- b. Diagnosis
- c. Definitive treatment
- d. Conservative treatment

84. What is the recommended treatment approach for acute gastric dilatation?

- a. Antibiotics and steroids
- b. Endotracheal intubation and ventilation
- c. Prompt decompression of the stomach**
- d. Surgical intervention with ligation of the aorta

85. What is the rationale for routine nasogastric suction after abdominal surgery?

- a. Prevent acute gastric dilatation
- b. Reduce the risk of infective complications**
- c. Shorten the length of hospital stay
- d. Provide patient comfort

86. When is surgical treatment considered for acute bleeding due to stress ulceration?

- a. After failed conservative treatment**
- b. In cases of recurrent bleeding
- c. As a prophylactic measure
- d. For all cases of stress ulceration

**Pyloric stenosis. Penetration of ulcers.
Malignancy.
Perforated gastric ulcer and duodenum.**

1. Wedge excision of bleeding ulcer with pyloroplasty and stem vagotomy

- +1. Resection of the stomach with bleeding ulcer
- 2. Wedge-shaped excision of bleeding ulcer with selective proximal vagotomy
- 3. Suturing of bleeding ulcer with pyloroplasty and stem vagotomy
- 4. Excision of ulcer

2. What is the most informative method of perforated ulcers diagnosing?

- 1. Esophagogastroduodenoscopy
- 2. Ultrasound
- 3. Laparocentesis
- +4. Laparoscopy
- 5. Survey X-ray

3. The most common complication after the ulcer of duodenal anterior wall is:

- +1. Perforation
- 2. Bleedings
- 3. Penetration into the head of pancreas
- 4. Malignization
- 5. No correct answers

4. Very rare complication after duodenal ulcer is:

- 1. Perforation
- +2. Malignization

3. Bleedings
4. Penetration
5. Cicatricial deformity of the intestine

5. Significant radiological evidence of perforation of gastroduodenal ulcer is:

1. High position of the diaphragm
- +2. The presence of free gas in the abdomen
3. Pneumatization of the intestine
4. Klobier's cups
5. Enlarged bubble of gas in the stomach

6. Regurgitation with frothy bright red blood increasing with cough is typical for:

1. Bleeding gastric ulcer
2. Tumors of the cardia
3. Mallory-Weiss syndrome
- +4. Pulmonary hemorrhage
5. Osler-Weber-Rendu Syndrome

7. What is typical for perforated gastroduodenal ulcer?

- +1. Sudden onset with sharp pains in the epigastrium
2. The gradual increase of pain
3. Cramping sharp pain
4. Abundant recurrent vomiting
5. Rapidly increasing weakness, dizziness

8. What is not common for perforated gastric ulcer during the first 6 hours?

1. Sharp abdominal pains
2. Wooden belly
3. Disappearance of liver dullness
- +4. Abdominal distension
5. "Falx" of gases under the cupula of diaphragm

9. What should be the first examination with suspected perforated gastric ulcer?

1. Abdominal X-ray with barium mixture
- +2. Survey abdominal X-ray
3. Emergency gastroduodenoscopy
4. Angiography
5. Laparoscopy

10. What enables to determine the source of gastroduodenal bleeding?

1. Abdominal X-ray
2. Laparoscopy
3. Levin tube
- +4. Gastroscopy
5. Retesting of hemoglobin and haematocrit

11. Disappearance of pains and onset of melena in duodenal ulcer is typical for:

1. Pyloroduodenal stenosis
2. Ulcer perforation
3. Ulcer malignation
- +4. Bleedings
5. Penetrations into pancreas

12. Mallory–Weiss syndrome is:

1. Varicose esophageal and cardiac veins complicated by bleeding
2. Bleeding in of Meckel diverticulum ulcer
3. Bleeding from the mucous membrane on the basis of hemorrhagic angiomatosis (Osler-Rendu disease)
- +4. Cracks in the cardiac part of the stomach with bleeding
5. Hemorrhagic erosive gastroduodenitis

13. Theoretically Meulengracht's diet is based on the following:

1. Sparing of the mucous coat of stomach
2. Suppression of gastric acid secretion
3. High-calorie food
- +4. All answers are correct
5. There are no correct answers

14. What are the most common complication of penetrating gastric ulcer?

1. The development of pyloric stenosis
2. Malignization of ulcer
3. Development of interorgan fistula
- +4. Profuse bleeding
5. Perforation

15. What defines the character of operative surgery in perforated gastric ulcer?

1. Age of the patient
2. Localization of perforated foramen
3. The degree of peritonitis intensity
4. The period from perforation
- +5. All mentioned above

16. Which symptom of acute appendicitis can stimulate concealed perforation of duodenal ulcer during the first hours of the disease onset?

1. Blumberg's sign
2. Rovsing's symptom
- +3. Kocher-Volkovich's sign
4. Voskresensky's symptom
5. Promtov's sign

17. Conservative therapy of perforated ulcer is permissible only in the following case:

1. The patient has no ulcerative anamnesis
2. For senile patients

- +3. If there are no conditions for an emergency surgery
- 4. For extremely high degree of operational risk
- 5. For combination of gastric and duodenal ulcers

18. Forced position of the patient with legs bringing to his stomach and wooden belly is typical for:

- 1. Hemorrhagic pancreatic necrosis
- 2. Volvulus
- +3. Perforated ulcer
- 4. Renal colic
- 5. Mesenteric thrombosis

19. What is indicated in an hour after the perforation of callous gastric ulcer?

- 1. True antrectomy
- +2. Classical resection of 2/3 of the stomach
- 3. Suturing of perforated ulcer
- 4. Stem vagotomy with pyloroplasty
- 5. Any of these operations

20. What is not typical for bleeding duodenal ulcer?

- 1. Coffee ground vomiting
- +2. Abdominal pain intensification
- 3. Decline in hemoglobin
- 4. Melena
- 5. Blood volume reduction

21. What is indicated in the relapse of ulcerative gastroduodenal bleeding?

- +1. Emergency surgery
- 2. Urgent surgery
- 3. Repeated endoscopic hemostatic therapy
- 4. Intensive conservative hemostatic therapy

22. What is recommended under the threat of recurrence of ulcerative gastroduodenal bleeding?

- 1. Extremely conservative therapy
- 2. Emergency surgery
- +3. Urgent surgery
- 4. Systematic endoscopic control
- 5. Surgical treatment is routinely

23. Operation of choice for perforated gastric ulcer in purulent peritonitis is:

- 1. Resection of the stomach
- 2. Excision of ulcer with stem vagotomy and pyloroplasty
- +3. Closure of perforation
- 4. Selective proximal vagotomy with closure of perforation

24. What is the most common cause of peptic ulcers?

- a) Bacterial infection
- b) Excessive alcohol consumption

- c) Chronic stress
- d) Non-steroidal anti-inflammatory drugs (NSAIDs)**

25. Which bacterium is primarily responsible for causing peptic ulcers?

- a) Streptococcus
- b) Helicobacter pylori**
- c) Escherichia coli
- d) Staphylococcus aureus

26. Which layer of the stomach lining is primarily affected by peptic ulcers?

- a) Mucosa**
- b) Submucosa
- c) Muscularis externa
- d) Serosa

27. What is the most common symptom of peptic ulcers?

- a) Nausea and vomiting
- b) Abdominal pain**
- c) Chest pain
- d) Diarrhea

28. Which of the following is NOT a risk factor for developing peptic ulcers?

- a) Smoking
- b) Family history of ulcers
- c) Regular exercise**
- d) Chronic use of NSAIDs

29. What is the first-line treatment for peptic ulcers caused by H. pylori infection?

- a) Proton pump inhibitors (PPIs)
- b) Antibiotics**
- c) Antacids
- d) H2 blockers

30. Which surgical procedure may be performed to treat severe cases of peptic ulcers that do not respond to medications?

- a) Gastric bypass surgery
- b) Vagotomy
- c) Gastrectomy**
- d) Laparoscopy

31. What dietary modification is often recommended for individuals with peptic ulcers?

- a) High-fat diet
- b) Spicy foods
- c) Low-fiber diet
- d) Avoiding alcohol and caffeine**

32. Which complication can arise from untreated or severe peptic ulcers?

- a) Peritonitis**
- b) Pneumonia
- c) Osteoporosis
- d) Anemia

33. What is the primary goal of surgical treatment for peptic ulcers?

- a) Reduce stomach acidity
- b) Remove the entire stomach
- c) Repair the damaged mucosa**
- d) Remove the gallbladder

34. Which medication is commonly used to reduce stomach acid production in peptic ulcer treatment?
- a) Aspirin
 - b) Ibuprofen
 - c) Ranitidine**
 - d) Prednisone
35. How does smoking affect the development and healing of peptic ulcers?
- a) Smoking has no effect on peptic ulcers
 - b) Smoking slows down ulcer healing and increases the risk of recurrence**
 - c) Smoking accelerates ulcer healing
 - d) Smoking only affects H. pylori infection, not ulcers themselves
36. What is the role of H2 blockers in the treatment of peptic ulcers?
- a) Kill H. pylori bacteria
 - b) Promote healing of the ulcer lining
 - c) Reduce stomach acid production**
 - d) Prevent bleeding from the ulcer
37. Which non-invasive test can be used to detect H. pylori infection in patients with suspected peptic ulcers?
- a) Blood test for antibodies to H. pylori
 - b) Stool antigen test for H. pylori
 - c) Breath test for H. pylori
 - d) All of the above**
38. What is the most common location for peptic ulcers to develop in the digestive system?
- a) Esophagus
 - b) Stomach
 - c) Duodenum**
 - d) Colon
39. What is the main function of prostaglandins in relation to peptic ulcers?
- a) They protect the stomach lining from acid damage.**
 - b) They stimulate acid production in the stomach.
 - c) They promote inflammation in the stomach lining.
 - d) They have no role in peptic ulcer development.
40. Which of the following is NOT a common symptom of a bleeding peptic ulcer?
- a) Black, tarry stools (melena)
 - b) Vomiting blood (hematemesis)
 - c) Severe chest pain**
 - d) Weakness and fatigue
41. What type of surgery involves cutting the vagus nerve to reduce stomach acid production in patients with peptic ulcers?
- a) Vagotomy**
 - b) Gastric bypass surgery
 - c) Fundoplication
 - d) Laparoscopic surgery
42. Which of the following lifestyle modifications can help prevent peptic ulcers?
- a) Eating spicy foods regularly
 - b) Managing stress levels**
 - c) Avoiding regular exercise
 - d) Drinking excessive alcohol
43. Which medication is commonly used to eradicate H. pylori infection in patients with peptic ulcers?
- a) Amoxicillin
 - b) Metronidazole
 - c) Clarithromycin

d) **All of the above**

44. What is the primary function of mucus in the stomach lining in relation to peptic ulcers?

- a) It neutralizes stomach acid.
- b) It protects the stomach lining from acid damage.**
- c) It stimulates acid production.
- d) It promotes inflammation in the stomach lining.

45. Which test is used to determine if an individual has an allergy to certain foods that may exacerbate peptic ulcer symptoms?

- a) Skin prick test
- b) RAST (radioallergosorbent test)
- c) Elimination diet trial**
- d) Patch test

46. Which surgical procedure involves removing part of the stomach to treat severe cases of peptic ulcers?

- a) Gastrectomy**
- b) Vagotomy
- c) Laparoscopy
- d) Gastric bypass surgery

47. What is the primary cause of stress-related peptic ulcers?

- a) Increased production of stomach acid during stress
- b) Weakening of the protective mucosal barrier during stress**
- c) Stress-induced bacterial overgrowth in the stomach
- d) Stress-induced allergic reactions to food

48. What is the primary mechanism by which NSAIDs contribute to the development of peptic ulcers?

- a) They directly damage the stomach lining.
- b) They increase stomach acid production.
- c) They inhibit prostaglandin production, leading to decreased mucosal protection.**
- d) They have no effect on peptic ulcer development.

49. Which medication is commonly used to relieve pain and inflammation caused by peptic ulcers?

- a) Acetaminophen (Tylenol)**
- b) Ibuprofen (Advil)
- c) Aspirin
- d) Morphine

50. Which type of surgery involves wrapping part of the stomach around the lower esophagus to strengthen the sphincter and prevent acid reflux in patients with severe peptic ulcers?

- a) Gastric bypass surgery
- b) Vagotomy
- c) Fundoplication**
- d) Laparoscopic surgery

Acute cholecystitis

1. Acute cholecystitis can develop due to: 1. Infected bile in the gallbladder 2. Stagnation of bile in the gall bladder 3. Gallstones 4. Cystic artery thrombosis 5. Duodenogastric reflux Choose the right answer:

- 1) 1 and 3
- +2) 1, 2, 3, 4
- 3) 2, 4, 5
- 4) 3, 4, 5
- 5) 4 and 5

2. Everything mentioned below is characteristic of catarrhal cholecystitis, except:

1. Sickness and vomiting
2. Kehr's sign
3. Murphy's sign
- +4. Right hypochondrium abdominal wall muscle tension and Shchiotkin-Blumberg sign.
5. Myussi-Georgievsky symptom

3. In acute destructive cholecystitis cholecystostomy is indicated in:

1. Concomitant acute edematous pancreatitis
2. Concomitant obstructive jaundice
3. Grave general condition of a patient
4. Concomitant cholangitis
- +5. All variants are correct

4. A patient presented in clinic with phlegmonous cholecystitis. In following three days he had shivering, jaundice, temperature of 38.0°C; symptoms of peritonitis are absent. What complication of fundamental illness has developed in a patient?

1. Large duodenal papilla stenosis
2. Gallbladder empyema
3. Pylephlebitis
3. Subhepatic abscess
- +4. Purulent cholangitis

5. To solve the problem of urgent surgery in acute cholecystitis most important is:

1. Intensity of pains
2. Disease duration
3. Number of attacks in anamnesis
- +4. Peritonitis
5. Gallstones

6. Cholecystectomy from the bottom is performed in one of the following cases:

1. In elderly patients
2. In symptoms of cholangitis
3. In contracted gallbladder
4. Impacted stone in the gallbladder neck
- +5. Inflammatory infiltration in the area of gallbladder neck

7. An 81-year-old patient presented in surgery department. Acute phlegmonous cholecystitis was suspected during medical examination. What examination technique should be first used for the diagnosis specifying?

- +1. Ultrasonic scanning of abdominal cavity
2. Infusion cholecyst-cholangiography
3. Laparoscopy
4. Retrograde pancreatocholangiography
5. Percutaneous transhepatic cholecystcholangiography

8. What surgery should be performed in an 81-year-old patient with acute phlegmonous cholecystitis and poor general condition?

1. Cholecystectomy
- +2. Laparoscopic cholecystectomy under local anesthesia
3. Cholecystotomy
4. Laparoscopic drainage of subhepatic area 5. Cholecystolithomy

9. What procedure should be performed for noncomplicated cholelithiasis diagnosing?

1. Endoscopic retrograde cholangiopancreatography
2. Laparoscopy
- +3. Ultrasonography
4. Percutaneous transhepatic cholangiography
5. Fractional duodenal probing

10. The main methods of obstructive jaundice diagnosing character and reasons are: 1. Plain radiography of the liver and subhepatic area 2. Infusion cholecystcholangiography 3. Percutaneous transhepatic cholecystcholangiography 4. Endoscopic retrograde pancreatocholangiography 5. Ultrasonography Choose the correct combination of answers:

- 1) 1 and 5
- 2) 2 and 4
- 3) 1, 2, 4
- 4) 2, 3, 5
- +5) 3, 4, 5

11. What signs are characteristic of obturative purulent cholangitis? 1. Jaundice 2. Shivering 3. High level of alkaline phosphatase activity 4. High leukocytosis in blood analysis with shift to 5. Possible enlargement of liver size.

- 1) 1, 2, 3
- 2) 1, 2, 4, 5
- 3) 2, 3, 5
- +4) All variants are correct
- 5) All variants are incorrect

12. Revision of extrahepatic bile ducts during the surgery should be performed in: 1. Palpable stone in common bile duct 2. Suspected duodenal papilla stenosis 3. Jaundice at the moment of surgery 4. Chronic pancreatitis 5. Jaundice in anamnesis Choose the correct combination of answers:

- 1) 1, 2, 4
- 2) 1, 3, 4
- 3) 2, 3, 5
- 4) 3, 4, 5
- +5) 1, 2, 3, 5

13. Acute cholecystitis can be complicated by everything mentioned below except:

1. Obstructive jaundice
- +2. Portal hypertension
3. Purulent cholangitis
4. Subhepatic abscess
5. Stone impaction in the large duodenal papilla

14. The examination of 67-year-old patient acute gangrenous cholecystitis and local peritonitis were detected. What is your medical approach?

1. Conservative therapy due to elderly age of a patient
2. Surgery in case of absence of conservative therapy effect
3. Tactical decision depends on term of disease
4. Delayed operation
- +5. Emergency operative treatment

15. Destructive cholecystitis with peritonitis signs in right hypochondrium were detected in a 77-year-old patient with evident cardiac insufficiency. What treatment mode should be preferred?

1. Laparoscopic cholecystectomy
- +2. Cholecystectomy surgery
3. Cholecystostomy surgery
4. Percutaneous transhepatic cholangiostomy
5. Only conservative therapy

16. Advantages of cholecystectomy surgery from the neck are: 1. Special conditions for bloodless gallbladder removal 2. Interrupted root of purulent bile in choledoch 3. Avoidance of stone migration from the gallbladder in choledoch 4. Avoidance of choledochotomy 5. Avoidance of intraoperative cholangiography Give the correct answer:

- +1) 1, 2, 3
- 2) 1, 2, 4
- 3) 1, 2, 5
- 4) 2, 4, 5
- 5) 2, 3, 4

17. All the listed symptoms are characteristic of purulent cholangitis clinical picture:

1. Fever
2. Hectic temperature
- +3. Enteroparesis
4. Moderate pains in the right hypochondrium
5. Jaundice

18. Laboratory data in obstructive jaundice due to choledoch obstruction by a stone is characterized by: 1. Bilirubinemia 2. Bilirubinuria 3. Decrease of alkaline phosphatase in blood 4. Absence of stercobilin in faeces 5. Sharp increase of serum transaminase activity Choose the correct combination of answers:

- 1) 1, 2, 3
- 2) 2, 3, 4
- +3) 1, 2, 4
- 4) 3, 4, 5
- 5) 2, 3, 5

19. The best and the safest diagnosing technique of asymptomatic choledocholithiasis and cicatricial stenosis of large duodenal papilla is:

1. Oral cholecystography
2. Intravenous cholecystocholangiography
3. Laparoscopic cholecystocholangiography
- +4. Endoscopic retrograde pancreaticholangiography
5. Percutaneous transhepatic cholangiography

20. Intraoperative cholangiography is indicated in following cases: 1. Small stones in the gallbladder and wide cystic duct 2. Suspected cicatricial stenosis of the major duodenal papilla 3. Dilatation of hepaticocholedoch 4. Obstructive jaundice in anamnesis 5. Obstructive jaundice at the moment of operation Right variants:

- 1) 2, 3, 5
- 2) 1, 2, 3, 5
- 3) 3 and 5
- 4) 2, 3, 4, 5
- +5) All variants are correct

21. A patient is operated on for cholelithiasis, complicated with choledocholithiasis and purulent cholangitis. What surgery extent should be preferred?

- 1. Cholecystectomy from the neck and drainage of subhepatic area by Spasokukotsky
- 2. Cholecystostomy
- 3. Cholecystectomy, choledoch drainage through cystic duct stump
- +4. Cholecystectomy, choledochotomy, hepaticocholedoch drainage by Kehr
- 5. All variants are incorrect

22. What is indicated for a patient with acute phlegmonous cholecystitis if during 48 hours drug-infusion therapy is inefficient?

- 1. Laparoscopic examination for diagnosis specifying
- 2. Intensifying of conservative therapy
- +3. Emergency surgery
- 4. Inclusion of antibiotics in conservative therapy
- 5. Percutaneous transhepatic choledoch drainage

23. Which of the following drainage types is not choledoch drainage?

- 1. Kehr's drainage
- 2. Vishnevsky drainage
- +3. Spasokukotsky drainage
- 4. Halstead drainage
- 5. All variants are incorrect

24. The reason for dilation and hypertension in extrahepatic bile ducts in patients with calculous cholecystitis can be:

- 1. Cicatricial stenosis of the major duodenal stenosis
 - 2. Indurative pancreatitis, compressing distal choledoch
 - 3. Chronic duodenitis
 - 4. Sclerosing cholangitis
 - 5. Lithiasis of bile ducts
- Choose the correct combination of answers:

- 1) 1, 2, 4
- 2) 1, 3, 5
- +3) 1, 2, 5
- 4) 2, 3, 5
- 5) 2, 3, 4

25. Cholelithiasis can cause all the following complications except:

- 1. Acute pancreatitis
- 2. Obstructive jaundice
- +3. Duodenostasis
- 4. Obturation small intestinal obstruction
- 5. Purulent cholangitis

26. Everything mentioned below is characteristic of catarrhal cholecystitis, except:

- 1. Sickness and vomiting

2. Kehr's sign
3. Murphy's sign
- +4. Right hypochondrium abdominal wall muscle tension and Shchiotkin-Blumberg sign.
5. Myussi-Georgievsky symptom

27. In acute destructive cholecystitis cholecystostomy is indicated in:

1. Concomitant acute edematous pancreatitis
2. Concomitant obstructive jaundice
3. Grave general condition of a patient
4. Concomitant cholangitis
- +5. All variants are correct

28. A patient presented in clinic with phlegmonous cholecystitis. In following three days he had shivering, jaundice, temperature of 38°C; symptoms of peritonitis are absent. What complication of fundamental illness has developed in a patient?

1. Large duodenal papilla stenosis
2. Gallbladder empyema
3. Pylephlebitis
3. Subhepatic abscess
- +4. Purulent cholangitis

29. To solve the problem of urgent surgery in acute cholecystitis most important is:

1. Intensity of pains
2. Disease duration
3. Number of attacks in anamnesis
- +4. Peritonitis
5. Gallstones

30. Cholecystectomy from the bottom is performed in one of the following cases:

1. In elderly patients
2. In symptoms of cholangitis
3. In contracted gallbladder
4. Impacted stone in the gallbladder neck
- +5. Inflammatory infiltration in the area of gallbladder neck

31. An 81-year-old patient presented in surgery department. Acute phlegmonous cholecystitis was suspected during medical examination. What examination technique should be first used for the diagnosis specifying?

- +1. Ultrasonic scanning of abdominal cavity
2. Infusion cholecyst-cholangiography
3. Laparoscopy
4. Retrograde pancreatocholangiography
5. Percutaneous transhepatic cholecystcholangiography

32. What surgery should be performed in an 81-year-old patient with acute phlegmonous cholecystitis and poor general condition?

1. Cholecystectomy
- +2. Laparoscopic cholecystectomy under local anesthesia
3. Cholecystotomy

4. Laparoscopic drainage of subhepatic area
5. Cholecystolithomy

33. What procedure should be performed for noncomplicated cholelithiasis diagnosing?

1. Endoscopic retrograde cholangiopancreatography
2. Laparoscopy
- +3. Ultrasonography
4. Percutaneous transhepatic cholangiography
5. Fractional duodenal probing

34. The main methods of obstructive jaundice diagnosing character and reasons are: 1. Plain radiography of the liver and subhepatic area 2. Infusion cholecystcholangiography 3. Percutaneous transhepatic cholecystcholangiography 4. Endoscopic retrograde pancreatocholangiography 5. Ultrasonography Choose the correct combination of answers:

- 1) 1 and 5
- 2) 2 and 4
- 3) 1, 2, 4
- 4) 2, 3, 5
- +5) 3, 4, 5

35. What signs are characteristic of obturative purulent cholangitis? 1. Jaundice 2. Shivering 3. High level of alkaline phosphatase activity 4. High leukocytosis in blood analysis with shift to 5. Possible enlargement of liver size.

- 1) 1, 2, 3
- 2) 1, 2, 4, 5
- 3) 2, 3, 5
- +4) All variants are correct
- 5) All variants are incorrect

36. Revision of extrahepatic bile ducts during the surgery should be performed in: 1. Palpable stone in common bile duct 2. Suspected duodenal papilla stenosis 3. Jaundice at the moment of surgery 4. Chronic pancreatitis 5. Jaundice in anamnesis Choose the correct combination of answers:

- 1) 1, 2, 4
- 2) 1, 3, 4
- 3) 2, 3, 5
- 4) 3, 4, 5
- +5) 1, 2, 3, 5

37. Acute cholecystitis can be complicated by everything mentioned below except:

1. Obstructive jaundice
- +2. Portal hypertension
3. Purulent cholangitis
4. Subhepatic abscess
5. Stone impaction in the large duodenal papilla

38. The examination of 67-year-old patient acute gangrenous cholecystitis and local peritonitis were detected. What is your medical approach?

1. Conservative therapy due to elderly age of a patient
2. Surgery in case of absence of conservative therapy effect
3. Tactical decision depends on term of disease

- 4. Delayed operation
- +5. Emergency operative treatment

39. Destructive cholecystitis with peritonitis signs in right hypochondrium were detected in a 77-year-old patient with evident cardiac insufficiency. What treatment mode should be preferred?

- 1. Laparoscopic cholecystectomy
- +2. Cholecystectomy surgery
- 3. Cholecystostomy surgery
- 4. Percutaneous transhepatic cholangiostomy
- 5. Only conservative therapy

40. Advantages of cholecystectomy surgery from the neck are: 1. Special conditions for bloodless gallbladder removal 2. Interrupted root of purulent bile in choledoch 3. Avoidance of stone migration from the gallbladder in choledoch 4. Avoidance of choledochotomy 5. Avoidance of intraoperational cholangiography Give the correct answer:

- +1) 1, 2, 3
- 2) 1, 2, 4
- 3) 1, 2, 5
- 4) 2, 4, 5
- 5) 2, 3, 4

41. All the listed symptoms are characteristic of purulent cholangitis clinical picture:

- 1. Fever
- 2. Hectic temperature
- +3. Enteroparesis
- 4. Moderate pains in the right hypochondrium 5. Jaundice

42. Laboratory data in obstructive jaundice due to choledoch obstruction by a stone is characterized by: 1. Bilirubinemia 2. Bilirubinuria 3. Decrease of alkaline phosphatase in blood 4. Absence of stercobilin in faeces 5. Sharp increase of serum transaminase activity Choose the correct combination of answers:

- 1) 1, 2, 3
- 2) 2, 3, 4
- +3) 1, 2, 4
- 4) 3, 4, 5
- 5) 2, 3, 5

43. The best and the safest diagnosing technique of asymptomatic choledocholithiasis and cicatricial stenosis of large duodenal papilla is:

- 1. Oral cholecystography
- 2. Intravenous cholecystocholangiography
- 3. Laparoscopic cholecystocholangiography
- +4. Endoscopic retrograde pancreatocholangiography
- 5. Percutaneous transhepatic cholangiography

44. Intraoperational cholangiography is indicated in following cases: 1. Small stones in the gallbladder and wide cystic duct 2. Suspected cicatricial stenosis of the major duodenal papilla 3. Dilatation of hepaticocholedoch 4. Obstructive jaundice in anamnesis 5. Obstructive jaundice at the moment of operation Right variants:

- 1) 2, 3, 5

- 2) 1, 2, 3, 5
- 3) 3 and 5
- 4) 2, 3, 4, 5
- +5) All variants are correct

45. A patient is operated on for cholelithiasis, complicated with choledocholithiasis and purulent cholangitis. What surgery extent should be preferred?

- 1. Cholecystectomy from the neck and drainage of subhepatic area by Spasokukotsky
- 2. Cholecystostomy
- 3. Cholecystectomy, choledoch drainage through cystic duct stump
- +4. Cholecystectomy, choledochotomy, hepaticocholedoch drainage by Kehr
- 5. All variants are incorrect

46. What is indicated for a patient with acute phlegmonous cholecystitis if during 48 hours drug-infusion therapy is inefficient?

- 1. Laparoscopic examination for diagnosis specifying
- 2. Intensifying of conservative therapy
- +3. Emergency surgery
- 4. Inclusion of antibiotics in conservative therapy
- 5. Percutaneous transhepatic choledoch drainage

47. Which of the following drainage types is not choledoch drainage?

- 1. Kehr's drainage
- 2. Vishnevsky drainage
- +3. Spasokukotsky drainage
- 4. Halstead drainage
- 5. All variants are incorrect

48. The reason for dilation and hypertension in extrahepatic bile ducts in patients with calculous cholecystitis can be:

- 1. Cicatricial stenosis of the major duodenal stenosis
 - 2. Indurative pancreatitis, compressing distal choledoch
 - 3. Chronic duodenitis
 - 4. Sclerosing cholangitis
 - 5. Lithiasis of bile ducts
- Choose the correct combination of answers:

- 1) 1, 2, 4
- 2) 1, 3, 5
- +3) 1, 2, 5
- 4) 2, 3, 5
- 5) 2, 3, 4

49. Cholelithiasis can cause all the following complications except:

- 1. Acute pancreatitis
- 2. Obstructive jaundice
- +3. Duodenostasis
- 4. Obturation small intestinal obstruction
- 5. Purulent cholangitis

50. A day ago phlegmonous cholecystitis developed in a 69-year-old patient. Medical examination detected satisfactory condition, puls - 90 bpm, Abdomen is soft, painful gallbladder is palpable. Shchiotkin- Blumberg sign is negative. What is your medical approach?

- +1. Emergency surgery

2. Only conservative therapy including antibioticotherapy
3. Conservative therapy. If the effect is absent during 24 hours emergency surgery is indicated.
4. Cholecystostomy after preoperative preparation
5. Medical approach is determined by stones in the gallbladder and bile ducts

51. What therapy is indicated for a patient with biliary colic attack due to gallstones?

1. Urgent cholecystectomy
2. Conservative therapy
3. Antifermental therapy
- +4. Emergency surgery after pain attack reduction
5. Laparoscopic cholecystostomy

52. Everything mentioned below is applied for detecting the reason and diagnosing of obstructive jaundice, except:

1. Cytologic liver enzymes
- +2. Infusion cholangiography
3. Laparoscopy
4. Endoscopic retrograde cholangiopancreatography
5. Percutaneous transhepatic cholangiography

53. Acute cholecystitis begins with:

1. Increase of temperature
2. Vomiting
- +3. Pains in the right hypochondrium
4. Diarrhea
4. Heaviness in the epigastric area

54. Attack of biliary colic occurs:

- +1. Suddenly and sharply
2. After prodromal period
3. Gradually, little by little
4. After long starving
5. After supercooling

55. Normal bilirubin index:

1. 0,10 - 0,68 mmol / l
- +2. -8,55 - 20,52 mmol / l
3. 2,50 - 8.33 mmol / l
4. 3,64 - 6,76 mmol / l
5. 7,62 - 12,88 mmol / l

56. What is contraindicated in acute and chronic cholecystitis:

1. Papaveretum
- +2. Morphine hydrochloride
3. No-Spa
4. Atropini sulfas
5. Spasmalgon, baralgin, spazgan

57. Normally the width of choledoch equals:

1. Less than 0.5 cm
- +2. -0,6 - 1,0 cm
3. 1,1 - 1,5cm
4. 1,6 - 2,0 cm
5. More than 2,0cm

58. Everything mentioned below concerns to extrahepatic bile ducts examination technique, except:

1. Choledoch palpation
2. Cholangioscopy
3. Intraoperative cholangiography
4. Choledoch probing
- +5. More than 2, ocm

59. A patient with jaundice and accompanying choledocholithiasis needs:

1. Emergency surgery
2. Conservative therapy
- +3. Urgent surgery after preoperative preparation
4. Coeliac artery catheterization
5. Plasmapheresis

60. What can be applied in acute calculous cholecystitis?

1. Emergency surgery
2. Urgent surgery
3. Conservative therapy and following elective surgery
4. Only conservative surgery
- +5. Everything mentioned above

61. Courvoisier's symptom is not characteristic of:

- +1. Acute calculous cholecystitis
2. Head of pancreas cancer
3. Indurative pancreatitis
4. Major duodenal papilla tumor
5. Choledoch tumor

62. What is not characteristic of obstructive jaundice due to choledocholithiasis?

1. Hyperthermia
2. Increased conjugated bilirubin of blood
3. Increased alkaline phosphatase
- +4. Sharp increase of transaminase in plasma
5. Absence of stercobilin in feces

63. What is not used for specifying of jaundice character and the reasons of its appearance:

1. Computer tomography
- +2. Intravenous cholecystocholangiography
3. Percutaneous transhepatic cholangiography
4. Endoscopic retrograde pancreatocholangiography
5. Ultrasonic scanning

64.What is not characteristic of acute obturative cholangitis clinical picture?

1. Jaundice
2. Increase of temperature
- +3. Decrease of liver size
4. Leukocytosis with shift to the left
5. Liver enlargement

65.What is not characteristic of acute cholangitis clinical picture?

1. High temperature
2. Pains in the right hypochondrium
3. Jaundice
4. Leukocytosis
- +5. Unstable liquid stool

66.Intermittent jaundice is caused by:

1. Impacted stone of the choledoch terminal part
2. Choledoch tumor
3. Cystic duct stone
- +4. Valve choledoch stone
5. Choledoh stricture

67.In cholelithiasis emergency surgery is indicated in:

1. Cystic duct occlusion
2. Cholecystopancreatitis
- +3. Perforative cholecystitis
4. Obstructive jaundice
5. Hepatic colic

68.Choledocholithiasis complication is:

1. Gallbladder hydrops
2. Gallbladder empyema
- +3. Jaundice, cholangitis
4. Chronic active hepatitis
5. Perforative cholecystitis, peritonitis

69.Elective cholecystectomy in cholelithiasis is indicated in:

- +1. All cases
2. Latent form of disease
3. Clinical signs of disease and labor ability decrease
4. Patients older than 55 y.o.
5. Patients younger than 20 y.o.

Stomach ulcer

- 1.Wedge excision of bleeding ulcer with pyloroplasty and stem vagotomy

- +1. Resection of the stomach with bleeding ulcer
- 2. Wedge-shaped excision of bleeding ulcer with selective proximal vagotomy
- 3. Suturing of bleeding ulcer with pyloroplasty and stem vagotomy
- 4. Excision of ulcer

2.What is the most informative method of perforated ulcers diagnosing?

- 1. Esophagogastroduodenoscopy
- 2. Ultrasound
- 3. Laparocentesis
- +4. Laporoscopy
- 5. Survey X-ray

3.The most common complication after the ulcer of duodenal anterior wall is:

- +1. Perforation
- 2. Bleedings
- 3. Penetration into the head of pancreas
- 4. Malignization
- 5. No correct answers

4.Very rare complication after duodenal ulcer is:

- 1. Perforation
- +2. Malignization
- 3. Bleedings
- 4. Penetration
- 5. Cicatricial deformity of the intestine

5.Significant radiological evidence of perforation of gastroduodenal ulcer is:

- 1. High position of the diaphragm
- +2. The presence of free gas in the abdomen
- 3. Pneumatization of the intestine
- 4. Kloiber's cups
- 5. Enlarged bubble of gas in the stomach

6.Regurgitation with frothy bright red blood increasing with cough is typical for:

- 1. Bleeding gastric ulcer
- 2. Tumors of the cardia
- 3. Mallory-Weiss syndrome
- +4. Pulmonary hemorrhage
- 5. Osler-Weber-Rendu Syndrome

7.What is typical for perforated gastroduodenal ulcer?

- +1. Sudden onset with sharp pains in the epigastrium
- 2. The gradual increase of pain
- 3. Cramping sharp pain
- 4. Abundant recurrent vomiting
- 5. Rapidly increasing weakness, dizziness

8.What is not common for perforated gastric ulcer during the first 6 hours?

1. Sharp abdominal pains
2. Wooden belly
3. Disappearance of liver dullness
- +4. Abdominal distension
5. "Falx" of gases under the cupula of diaphragm

9.What should be the first examination with suspected perforated gastric ulcer?

1. Abdominal X-ray with barium mixture
- +2. Survey abdominal X-ray
3. Emergency gastroduodenoscopy
4. Angiography
5. Laparoscopy

10.What enables to determine the source of gastroduodenal bleeding?

1. Abdominal X-ray
2. Laparoscopy
3. Levin tube
- +4. Gastroscopy
5. Retesting of hemoglobin and haematocrit

11.Disappearance of pains and onset of melena in duodenal ulcer is typical for:

1. Pyloroduodenal stenosis
2. Ulcer perforation
3. Ulcer malignation
- +4. Bleedings
5. Penetrations into pancreas

12.Mallory–Weiss syndrome is:

1. Varicose esophageal and cardiac veins complicated by bleeding
2. Bleeding in of Meckel diverticulum ulcer
3. Bleeding from the mucous membrane on the basis of hemorrhagic angiomatosis (Osler-Rendu disease)
- +4. Cracks in the cardiac part of the stomach with bleeding
5. Hemorrhagic erosive gastroduodenitis

13.Theoretically Meulengracht's diet is based on the following:

1. Sparing of the mucous coat of stomach
2. Suppression of gastric acid secretion
3. High-calorie food
- +4. All answers are correct
5. There are no correct answers

14.What are the most common complication of penetrating gastric ulcer?

1. The development of pyloric stenosis

- 2. Malignization of ulcer
- 3. Development of interorgan fistula
- +4. Profuse bleeding
- 5. Perforation

15. What defines the character of operative surgery in perforated gastric ulcer?

- 1. Age of the patient
- 2. Localization of perforated foramen
- 3. The degree of peritonitis intensity
- 4. The period from perforation
- +5. All mentioned above

16. Which symptom of acute appendicitis can stimulate concealed perforation of duodenal ulcer during the first hours of the disease onset?

- 1. Blumberg's sign
- 2. Rovsing's symptom
- +3. Kocher-Volkovich's sign
- 4. Voskresensky's symptom
- 5. Promtov's sign

17. Conservative therapy of perforated ulcer is permissible only in the following case:

- 1. The patient has no ulcerative anamnesis
- 2. For senile patients
- +3. If there are no conditions for an emergency surgery
- 4. For extremely high degree of operational risk
- 5. For combination of gastric and duodenal ulcers

18. Forced position of the patient with legs bringing to his stomach and wooden belly is typical for:

- 1. Hemorrhagic pancreatic necrosis
- 2. Volvulus
- +3. Perforated ulcer
- 4. Renal colic
- 5. Mesenteric thrombosis

19. What is indicated in an hour after the perforation of callous gastric ulcer?

- 1. True antrectomy
- +2. Classical resection of 2/3 of the stomach
- 3. Suturing of perforated ulcer
- 4. Stem vagotomy with pyloroplasty
- 5. Any of these operations

20. What is not typical for bleeding duodenal ulcer?

- 1. Coffee ground vomiting
- +2. Abdominal pain intensification
- 3. Decline in hemoglobin
- 4. Melena
- 5. Blood volume reduction

21. What is indicated in the relapse of ulcerative gastroduodenal bleeding?

- +1. Emergency surgery
- 2. Urgent surgery
- 3. Repeated endoscopic hemostatic therapy
- 4. Intensive conservative hemostatic therapy

22. What is recommended under the threat of recurrence of ulcerative gastroduodenal bleeding?

- 1. Extremely conservative therapy
- 2. Emergency surgery
- +3. Urgent surgery
- 4. Systematic endoscopic control
- 5. Surgical treatment is routinely

23. Operation of choice for perforated gastric ulcer in purulent peritonitis is:

- 1. Resection of the stomach
- 2. Excision of ulcer with stem vagotomy and pyloroplasty
- +3. Closure of perforation
- 4. Selective proximal vagotomy with closure of perforation

Rectum and colon

1. What is most characteristic of chronic paraproctitis?

- 1. Hematuria
- +2. Mouth of a fistula on the perineum skin
- 3. Discharge of crimson blood after defecation
- 4. Pains under belly
- 5. Diarrhea

2. Following methods are used for rectal fistulas examination:

- 1. Visual examination and palpation
- 2. Digital rectal investigation
- 3. Staining of the fistula tract
- 4. Fistulography
- +5. Everything mentioned above

3. Epithelial coccygeal course:

- 1. Is connected with the sacrum
- 2. Is connected with the coccyx
- +3. Ends blindly in the subcutaneous tissue of the inter-buttock area
- 4. Is situated between the posterior rectal surface and the anterior sacral surface
- 5. Is communicated with the rectal lumen

4. Congenital megacolon (Hirschsprung's disease) is diagnosed with the help of:

- 1. Fecal microbiological test
- 2. X-ray examination
- +3. Large intestine biopsy

5. In Hirschsprung's disease there is no diagnostic meaning in:

1. Irrigoscopy
2. Examination of the barium passage along the large intestine
- +3. Change of internal rectal sphincter tone
4. Svenson's biopsy

5. Colonoscopy

6. What intestine is damaged most often in ulcerative colitis?

1. Ascending colon
- +2. Transverse colon
3. Descending colon
4. Blind gut
5. Rectum

7. Toxic megacolon is the complication of:

1. Crohn's disease
2. Hirschsprung's disease
3. Gardner's syndrome
4. Peutz–Jeghers syndrome
- +5. Nonspecific ulcerative colitis

8. Sudden stop of diarrhea in nonspecific ulcerative colitis accompanied by severe intoxication points to the:

1. Effectiveness of conservative therapy
- +2. Toxic dilatation
3. Wrong diagnosis
4. Perforation
5. Hypovolemia

9. In continuous therapy of ulcerative colitis following signs can be revealed except:

1. Shortening of the bowel
2. Reduction of mucous surface brightness
- +3. Enlargement of the retroperitoneal lymph nodes
4. Right variants are 1 and 2

10. In therapy of nonspecific ulcerative colitis all the following preparations are used except:

1. Antibiotics
- +2. Laxatives
3. Vitamins
4. Immunostimulants
5. Hormonal preparations

11. What is used in therapy of ulcerative colitis?

1. Total parenteral nutrition
2. Total colectomy with ileostomy
3. Subtotal colectomy with ileostomy
- +4. All the mentioned methods
5. None of the methods

12. Complication of nonspecific ulcerative colitis, not demanding any operative intervention is:

1. Bleeding
2. Toxic megacolon
- +3. Water-electrolyte imbalance
4. Malignization
5. Perforation

13. In bowel perforation due to ulcerative colitis following measures are indicated:

- +1. Perforation suturing and ileostomy
2. Proximal colostomy
3. Total colectomy and ileostomy
4. Resection of the bowel segment with perforation
5. Loop exteriorization with peritoneum perforation

14. Surgical therapy in nonspecific ulcerative colitis is indicated in:

1. Profuse bleeding
2. Bowel perforation
3. Toxic dilatation
4. Non-effective conservative therapy
- +5. All the mentioned disorders

15. What microorganism causes pseudomembranous colitis due to antibiotic therapy?

1. Staphylococcus
2. Streptococcus
3. Colon bacillus
4. Bacteroides
- +5. Clostridium difficile

16. The following methods are used in pseudomembranous colitis therapy:

1. Stop of antibiotics intake (clindamycin)
2. Metronidazole
3. Water-electrolyte imbalance correction
4. Vancomycin
- +5. Steroids

17. Agent of choice in pseudomembranous colitis therapy is:

1. Metronidazole
2. Tetracycline
3. Cefuroxime
4. Bisepitol
- +5. Vancomycin

19. The most frequent large intestine diverticulum localization is:

1. Blind gut
2. Ascending colon

- 3. Transverse colon
- 4. Descending colon
- +5. Sigmoid colon
- 6. Rectum

20. The most frequent colon diverticulum complications are:

- 1. Bleeding
- 2. Bowel perforation
- 3. Diverticulitis
- 4. Bowel obstruction
- 5. Internal intestinal fistula

Right variants:

- a) 1, 2, 3
- b) 1, 4, 5
- c) 2, 4, 5
- +d) 1, 3
- e) 4, 5

21. Biochemical disorders accompanying villous adenoma includes everything except:

- 1. Hypokalemia
- 2. Hyponatremia
- 3. Hypochloremia
- 4. Uraemia
- +5. Hypocalcemia

22. Lymph outflow from the sigma is performed through the following lymph nodes:

- 1. Superior mesenteric lymph nodes
- +2. Inferior mesenteric lymph nodes
- 3. Para-aortic lymph nodes
- 4. None of the mentioned lymph nodes
- 5. Through all the mentioned lymph nodes

23. The most effective therapy of rectal fistulas is:

- 1. Conservative
- 2. Sclerosing
- +3. Surgical
- 4. Fistula filling

24. Surgical therapy of intrasphincteric rectal fistulas includes all the following operations except:

- 1. Fistula dissection in the rectal lumen
- 2. Fistula excision in the rectal lumen (according to Gabriel)
- 3. Fistula excision with the purulent cavity opening
- +4. Fistula excision with purulent cavity opening, suturing and drainage

25. Surgical therapy of trans-sphincteric rectal fistulas includes all the following operations except:

- 1. Fistula excision in the rectal lumen with a wound bottom suturing
- 2. Fistula excision in the rectal lumen with partial wound bottom suturing. Opening and drainage of the purulent cavity
- 3. Fistula excision in the rectal lumen with opening and drainage of the purulent cavity
- +4. Fistula excision with ligation conduction

26. Operation of choice in therapy of extra-sphinteric fistulas of the 1st stage is:

1. Fistula excision with the sphincter suturing
2. Fistula excision with the rectal mucosa transfer
3. Fistula excision without the sphincter suturing
- +4. Dosed sphincterotomy at a depth of 0,6-0.8 cm with fistula excision

27. Operation of choice in therapy of extra-sphinteric fistulas of the 2nd stage is:

- +1. Fistula excision with the sphincter suturing
2. Fistula excision with the rectal mucosa transfer
3. Fistula excision with ligation conduction
4. Dosed sphincterotomy at a depth of 0,6-0.8 cm with fistula excision

28. Operation of choice in therapy of extra-sphinteric fistulas of the 3rd stage is:

1. Fistula excision with the sphincter suturing
- +2. Fistula excision with the rectal mucosa transfer or fistula excision with ligation conduction into the sinus tract
3. Fistula excision (without sphincter excision) with ligation conduction into the ligation tract
4. Dosed sphincterotomy at a depth of 0,6-0.8 cm with fistula excision

"North Ossetian State Medical Academy" of the Ministry of health of the Russian Federation

Department	Surgical diseases №2		
Faculty	General Medicine	Cours	4
Discipline	Faculty Surgery		

Exam ticket

1. Symptomatic ulcers. (Hormonal and
 2. Syndrome Zollinger-Ellison, etiology, pathogenesis, clinic, treatment).
-
2. Hernias of the white line of the abdomen. (Clinic, diagnostics, methods of operations).

Head of Department, MD, Professor

V.Z. Totikov