

**State budgetary educational institution of higher
professional education**

**"North Ossetian State Medical Academy" of the Ministry of
health of the Russian Federation**

Department of surgical diseases No. 2

Kalitsova M. V., Totikov Z.V.

DISEASES OF THE RECTUM AND COLON

Textbook for students of 4 courses medical faculty of faculty surgery

Vladikavkaz

2020

CONTENTS

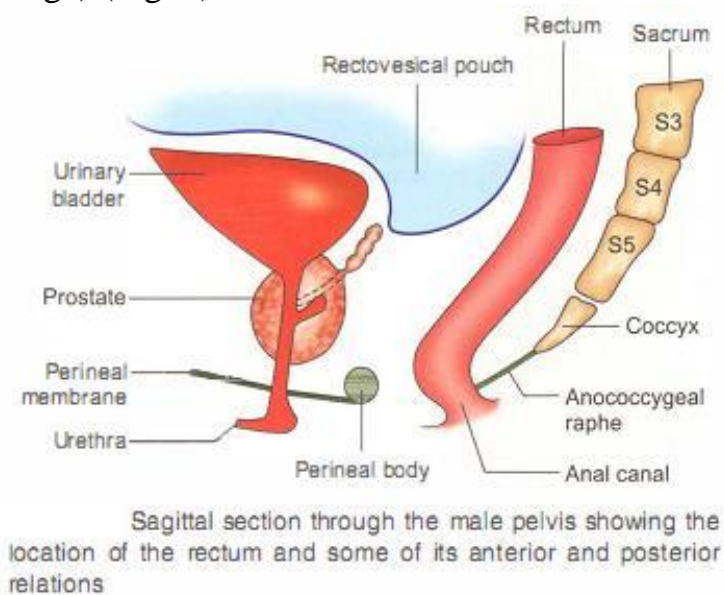
SURGICAL ANATOMY OF THE RECTUM.....	3
CARCINOMA RECTUM.....	6
PROLAPSE RECTUM.....	12
COMPLETE/TOTAL PROLAPSE.....	13
HAEMORRHOIDS.....	18

SURGICAL ANATOMY OF THE RECTUM

The rectum starts at the rectosigmoid junction, opposite the third piece of sacrum. It descends in the sacral hollow, passes through the pelvic floor, and ends in the anorectal junction, which is about 4 cm away from the anal verge. Anorectal junction is enclosed by puborectalis muscle posteriorly and in the lateral aspects. The rectum is 12-15 cm in length.

Peritoneal covering

- Upper one-third is completely covered by peritoneum (> 11 cm from anal verge) (Fig. 1)



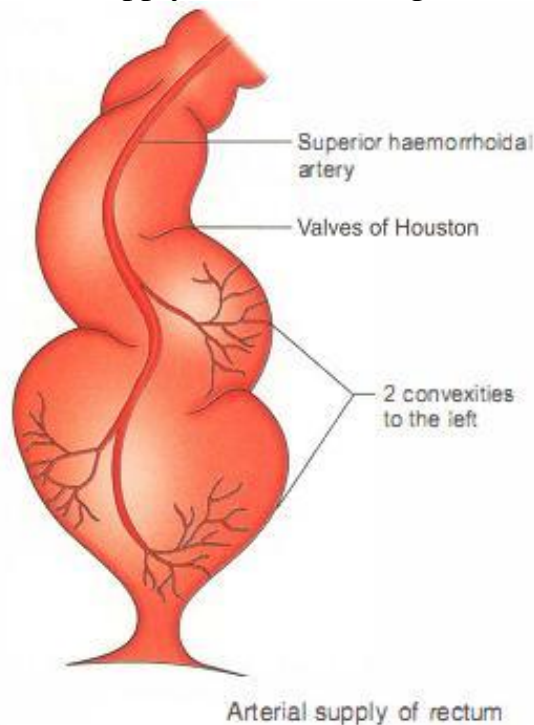
(Fig. 1)

- Middle one-third is covered in front and lateral aspects (6-11 cm).
- Lower one-third (0-6 cm) has no extraperitoneal covering but has two fascia! condensation layers. Posteriorly, the strong Waldeyer's layer separates the rectum from lower sacral pieces and coccyx. At surgery, stripping of this fascia results in uncontrollable bleeding from sacral plexus of veins, which is underneath the Waldeyer's fascia.
- Anteriorly, the weak Denonvillier's fascia separates the rectum from prostate and bladder. Stripping of this fascia results in troublesome bleeding from prostatic venous plexus.
- Rectum is attached to side wall of pelvis by lateral ligaments, which contain middle haemorrhoidal vessels. These need ligation or coagulation during mobilisation of lower rectum.
- Valves of Houston: Despite the name rectum means straight, it is never straight in adults. It has one convexity on the left and two convexities on the right side. There are 3 valves of Houston (prominent mucosal folds), two on the left and one on the right.

- That portion of the rectum resting on the pelvic floor is called ampulla-dilated portion of the mid rectum.

Arterial supply

1. Superior haemorrhoidal artery is a branch of the superior rectal artery which is the continuation of the inferior mesenteric artery. It divides into right and left branches. The right branch divides into anterior and posterior branches which supply the rectum (Fig. 2).



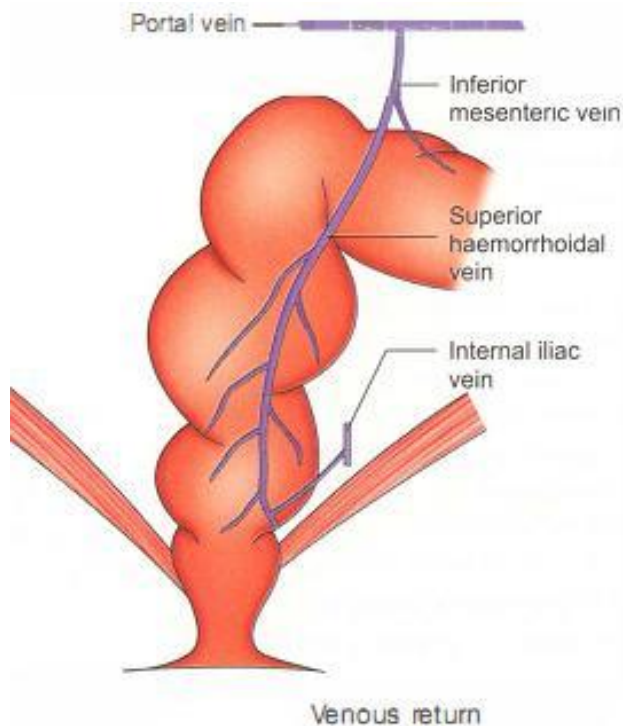
(Fig. 2)

2. Middle haemorrhoidal artery, a branch of internal iliac artery, runs in the lateral ligament of the rectum.
3. Inferior haemorrhoidal artery, a branch of internal pudendal artery supplies the lower rectum.

Venous return (Fig. 3)

The rich submucous plexus of veins surrounding the ampulla forms external rectal plexus. The venous drainage from here flows in two directions.

1. Upwards to drain into superior rectal veins. These join inferior mesenteric veins, which in turn drain into the portal system.
2. Across to drain into middle rectal veins, which run in the lateral ligament of the rectum along with middle rectal artery. Hence, the lateral ligaments have to be ligated and divided during resection of rectum. These veins drain into internal iliac veins (systemic circulation). Hence, rectum is a site of portosystemic anastomosis



(Fig. 3)

Lymphatic drainage of rectum

- Upper 1/3rd of rectum is completely enclosed by peritoneum and the middle 1/3rd of rectum is covered in front and on the sides by peritoneum. From these areas, lymphatic drainage always occurs in the upward direction, first to (A) pararectal nodes of Gerota followed by superior haemorrhoidal nodes, middle haemorrhoidal nodes and nodes at the origin of inferior mesenteric artery.
- From lower 1/3rd of rectum, lymphatics spread in the lateral direction and can involve (B) internal iliac nodes.
- Lymph nodes are also present in the hollow of sacrum along median sacral artery (C). Lymphatics are present in the muscularis mucosa.

Nerve supply

- Sympathetic: The fibres come from hypogastric plexus, which is located at the aortic bifurcation at the level of L5. Fibres also come along with inferior mesenteric artery and superior rectal artery.
- Parasympathetic: (S2, S3, S4) by means of nervi erigentes from the hypogastric plexus and supply motor fibres to detrusor. Pain and ability to distinguish latus and faeces is because of these fibres. Loss of mucosa of the rectum results in the loss of these sensations. During division of lateral ligaments or during anterior dissection of the bladder base, injury to nervi erigentes can occur.
- External anal sphincter and puborectalis are innervated by inferior rectal branches of internal pudendal nerve.

CARCINOMA RECTUM

Aetiopathogenesis

Similar to carcinoma colon. However, precancerous conditions and risk actors are given as follows.

Precancerous conditions

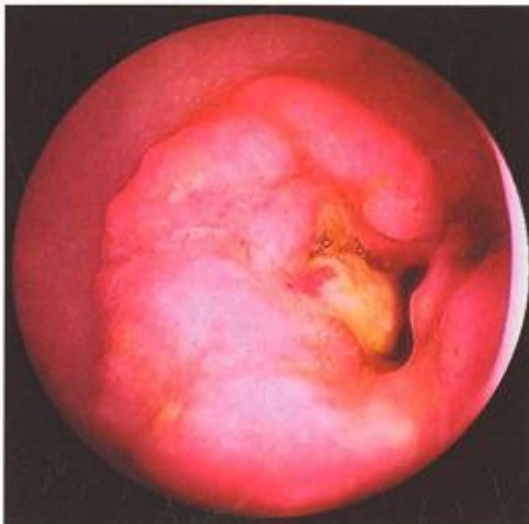- Polyps in FAP, villous adenoma
- Ulcerative colitis
- Crohn's disease

Risk factors

- Smoking, Alcohol, Diet
- Genetic
- Colorectal amily

Pathological types

1. Annular variety is common at the rectosigmoid junction. It presents with constipation and intestinal obstruction. It takes about a year for the growth to completely encircle the lumen of the gut (napkin ring deformity).
2. Polypoidal lesions are common in the ampulla of the rectum (Fig. 4).



Fibreoptic sigmoidoscopy showing growth in the upper rectum—biopsy proved signet ring carcinoma

(Fig. 4)

3. Ulcerative lesions can occur anywhere in the rectum with raised edges and the growth occurs in the transverse direction.
4. Diffuse variety is similar to linitis plastica. It develops from ulcerative colitis. It has a poor prognosis.

5. Colloid variety is rare. The tumour contents are gelatinous due to increased mucus production. This variety is seen in young patients. The cell is filled with mucus and nucleus is displaced. It is called 'Signet Ring' carcinoma. It is associated with poor prognosis.

Clinical features of carcinoma rectum

- Constipation requiring increasing doses of purgatives due to annular growth at rectosigmoid junction. Always a sense of incomplete evacuation and altered bowel habits.
- Bleeding per rectum, frank blood or mixed with stools is common. It is painless, never massive and is the earliest symptom of carcinoma rectum. Very often, it is confused or haemorrhoids.
- Early morning spurious diarrhoea is due to accumulation of mucus overnight in the ampulla of rectum (dilated middle portion of rectum), which causes an urgency to pass stools but results in passage of only mucus with minimal stools.

There is always a sense of incomplete defecation.

- Tenesmus
 - Painful, incomplete defecation associated with bleeding is called tenesmus.
 - This symptom is common with stricturous growths.
- Bloody slime : An attempt at defecation results in mucus mixed with blood.

SYMPTOM	PROBABLE SITE OF LESION/EXPLANATION
• Constipation	Rectosigmoid
• Bleeding	Cauliflower-like growth
• Tenesmus	Rectosigmoid stricture
• Early morning spurious diarrhoea	Growth in the ampulla of rectum
• Bloody slime	Blood and mucus
• Sciatic-like pain	Sacral plexus infiltration
• Abdominal distension	Large bowel obstruction
• Loss of weight/ abdominal distension	Liver metastasis, ascites, etc.
• Strangury	Infiltration of the bladder base anteriorly

- Loss of appetite, loss of weight due to liver secondaries, abdominal distension due to obstruction are late features.

Clinical examination

1. Rectal examination: In every patient with bleeding per rectum, rectal examination has to be done. More than 90% of cases of carcinoma rectum can be diagnosed by rectal examination. Always feel for the ulcer or growth, nodularity, induration, fixity to posterior sacrum, anterior bladder base and laterally to lateral ligaments. Look for the blood stains especially in ulcerative cases. It is also possible to feel the lymph nodes in the mesorectum in cases of lower third carcinomas.

2. Vaginal examination: When the growth is situated in the anterior wall of the rectum, accurate assessment of the growth can be done with one finger in the rectum and the other in the vagina. Large Krukenberg tumours if present can also be felt by vaginal and rectal examinations.
3. Evidence of metastasis: Palpable nodular liver, para-aortic lymph nodes, ascites and supraclavicular nodes (Troisiers sign).

Investigations (Table)

Importance of each investigation and how it alters the treatment plan in a case of biopsy-proven carcinoma rectum. APR—abdomino-perineal resection, HAR, LAR—high and low anterior resection			
	Plan	Investigation finding	Changed plan
1. Carcinoma lower rectum	APR	CT—metastasis in liver	Palliative colostomy/chemoradiation
2. Carcinoma upper rectum	HAR	Colonoscopy growth in transverse colon	Subtotal/total colectomy
3. Carcinoma lower rectum	APR	MRI/endosono-extensive T4 lesion	First chemoradiation followed by APR or LAR
4. Carcinoma rectum	LAR	CT scan—hydronephrosis	Cystoscopy—ureteric stenting—LAR
5. Carcinoma lower rectum	APR	PET scan—bone metastasis present	No APR

1. Proctoscopy: It should be done in all cases of bleeding per rectum. It is done as an outpatient procedure. The left lateral position with buttocks elevated on a small pillow is the ideal position for proctoscopy. However, knee-elbow position can also be used. The growth appears as an ulcer with everted edges. A biopsy is taken to prove the diagnosis.

The histological grading of the tumour is as follows:

- A. Well-differentiated carcinoma: Low-grade variety (10-15%).
- B. Moderately differentiated carcinoma: The most common variety (65%).
- C. Undifferentiated carcinoma: The most aggressive variety (20-25%).

2. Sigmoidoscopy: To take a biopsy from rectosigmoid growths, sigmoidoscopy is essential.

3. Barium enema: It is indicated when proctoscopy and sigmoidoscopy fail to give a diagnosis due to spasm of the colon. When carcinoma arises in multiple polyposis coli or ulcerative colitis, barium enema is done to rule out synchronous malignancies.

4. Colonoscopy: If synchronous carcinoma exists (8 to 10%) biopsy can be taken to prove the diagnosis.

5. CEA: Increased levels of carcinoembryonic antigen indicates metastasis.

6. Ultrasound: Some cases of carcinoma rectum present with metastasis such as secondaries in the liver, ascites with para-aortic nodes, etc (colloid carcinoma).

7. Endorectal ultrasonography (EUS)

Endoscopic ultrasound staging of rectal tumors

UT I Invasion confined to the mucosa and submucosa

UT2 Penetration of the muscularis propria but not through to the mesorectal fat

UT3 Invasion into the periapical fat

UT4 Invasion into the adjacent organ

UNO No enlargement of lymph nodes

UNI Perirectal lymph nodes enlarged

8. Computed tomography (CT) scan/MRI

- It helps to detect the lesion, detect metastasis in liver.
- To know the extension of the tumour
- To know the fixation to adjacent structures (ureter, uterus, bladder base, etc. hydronephrosis).
- Importantly, to know nodal status

TREATMENT PRINCIPLES

1. Aim is to have a curative resection

2. Palliative resection is worth doing even in the presence of metastasis, when there is obstruction.

3. Even though surgical treatment is the main modality, radiotherapy and chemotherapy are beneficial.

4. At surgery, ligation of vascular pedicle is done first to prevent tumour embolisation.

5. Ligation of bowel, proximal and distal to the tumour helps to prevent transluminal dissemination.

6. 40% ethanol is used as tumouricidal agent to prevent suture line recurrence. Solutions such as dilute povidone iodine have been used to irrigate rectal bed after APR to prevent recurrence but without much success.

7. Distal surgical margin should be about 2.5 cm to 3 cm. Proximal margin- minimum 5 cm.

8. An attempt should be made to perform a Total Mesorectal Excision (TME)- which improves quality of life (see Ten commandments).

TEN COMMANDMENTS OF TOTAL MESORECTAL EXCISION

1. Should do TME in all cases of mid and lower carcinoma rectum
2. Should excise the entire mesorectum (contains fat, lymph nodes and superior rectal blood vessels)
3. Should do the dissection with electrocautery or scissors
4. Should open the posterior plane between visceral and parietal layers of endopelvic fascia—**Holy plane of Heald or avascular plane**
5. Should exert good traction and counter traction to develop the planes
6. Should excise the entire mesorectum circumferentially- minimum of 5 cm of the CRM
7. Should be inside the pelvic plexus laterally
8. Should excise Denonvilliers fascia anteriorly
9. Should excise rectosacral ligament so as to reach the pelvic floor
10. Should do proximal diversion ileostomy

9. Colonic pouch: The splenic flexure is mobilised first. A 6cm limb of sigmoid or descending colon is folded and a pouch is created. A colotomy is made at the apex of the pouch. Linear cutter is used to staple the pouch on

itself to create a common lumen. A second fire of the stapler may be necessary. This pouch now acts like a neorectum.

- A double-stapled anastomosis as described or a hand-sewn anastomosis is then performed. A diverting loop ileostomy is used routinely for these ultra low anastomoses.

TREATMENT OF CARCINOMA RECTUM

Cancers arising in the distal 15 cm of the large bowel are included under this heading. These cancers behave almost like colonic cancers. The resection is the best treatment in early stages for cure. However, anatomy of the rectum, with its retroperitoneal location, narrow pelvis in males and proximity to the urogenital organs, autonomic nerves, and anal sphincters, makes surgical access and resection relatively difficult. In advanced cases neo-adjuvant therapy-chemo-radiotherapy is given to downstage the disease and then resections are done.

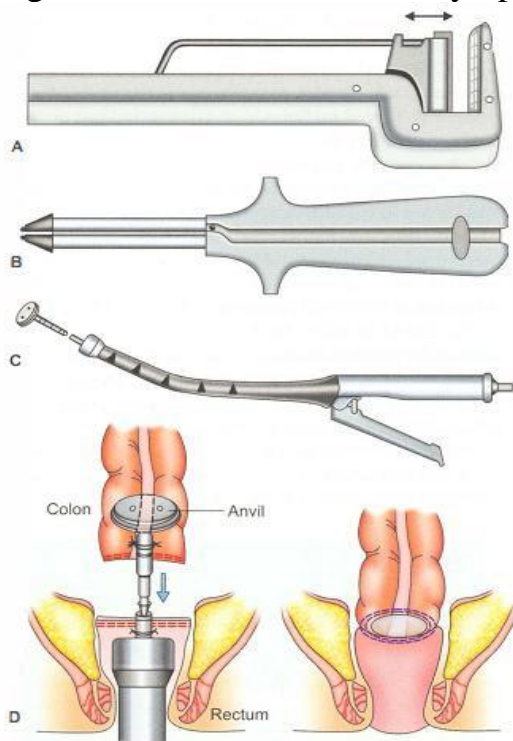
The treatment of rectal cancer has changed significantly over the past 20 years with the aim of cure with multimodality treatment and preserving the sphincter. Broadly the various surgery done for carcinoma rectum are as follows.

1. Anterior resection: Refers to removal of rectum and sigmoid colon. Indicated in cases of carcinoma rectum above peritoneal reflection: It can be low anterior resection when colorectal anastomosis is done below the peritoneal reflection or high anterior resection where the anastomosis is above peritoneal reflection. In this procedure rectum and sigmoid colon is removed along with mesorectum which contain lymphatic channels. Sphincter function is preserved. Sigmoid colon has to be removed because in cases of inferior mesenteric artery ligation, blood supply becomes inadequate and anastomosis may leak. Colorectal-colo anal anastomosis is done with or without pouch. Stapler anastomosis is the choice for low resections. Bowel is clamped and transected just proximal to this point. When the anastomosis is very low (just above anorectal ring), a protective diversion ileostomy is done which is closed after 10 weeks. Patient will have increased frequency of stools, incontinence or soilage. Diet restrictions may help these patients. Total mesorectal excision should be the aim. It improves the survival rates, decreases incidence of local recurrence.

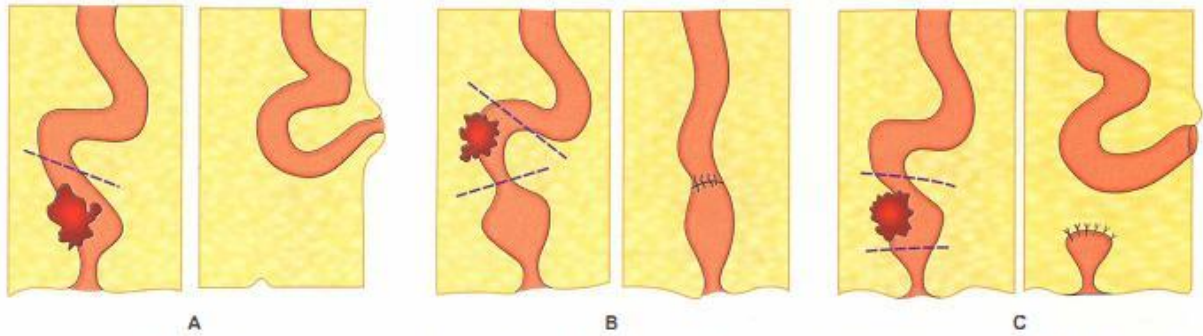
2. Abdominal Perineal Resection : It is also called as Miles-Walker's operation. It is indicated when the growth is too low involving the anal sphincters, poorly differentiated cancers which are very low. The patient is put in Lloyd Davis position (supine with lithotomy). Two surgeons operate simultaneously, one from the abdomen and one from the perineum. Abdomen is opened first

and the growth is mobilised from the sacrum and from the urinary bladder. Pelvic dissection is carried by abdominal surgeon till levator ani muscles. At this stage, anus is closed by a purse string by perineal surgeon. Rectum and anal canal is mobilized from below. The entire specimen of rectum with mesorectum and anal canal and the nodes are removed. It is followed by Permanent End- Colostomy by bringing the sigmoid colon outside in the left iliac fossa (sphincter sacrificing surgery). Thus complete excision of the rectum, anal canal, mesorectum, and lymph nodes are done through abdomino-perineal incision. Usually one drainage tube is inserted brought out through perineal wound.

3. Local excision: If the tumor is confined to the submucosa (uTI, NO), excision can be done by a transanal approach. The explanation being these cases will have less than 8% lymphatic metastasis. In our country majority of patients do not all in this category. It is indicated for mobile early tumors that are less than 4 cm in diameter, that involve less than 40% of the rectal wall circumference, with good histology like well or moderately differentiated histologically, and that are located within 6 cm of the anal verge. and with no vascular or lymphatic invasion.



(A to C) Parts of the stapler. (D) shows as the stapler is tightened, upper and lower rectum come together and the anvil fits in very well in the circular stapler



Schematic representations of resection of the rectum. (A) AP resection followed by colostomy, (B) High anterior resection followed by anastomosis, (C) Low anterior resection with colostomy and closure of rectal stump—Hartmann's procedure—in large bowel obstruction. The colostomy is closed and colorectal anastomosis is done after 4 weeks

PROLAPSE RECTUM

Protrusion of the mucous membrane or the entire rectum outside the anal verge. This condition is common in children and elderly patients.

Types

Prolapse can be of two types: Partial prolapse and complete prolapse.

Partial prolapse

- In this variety, the protrusion is between 1.25 and 3.75 cm outside the anal verge.
- It is usually a mucosal prolapse.

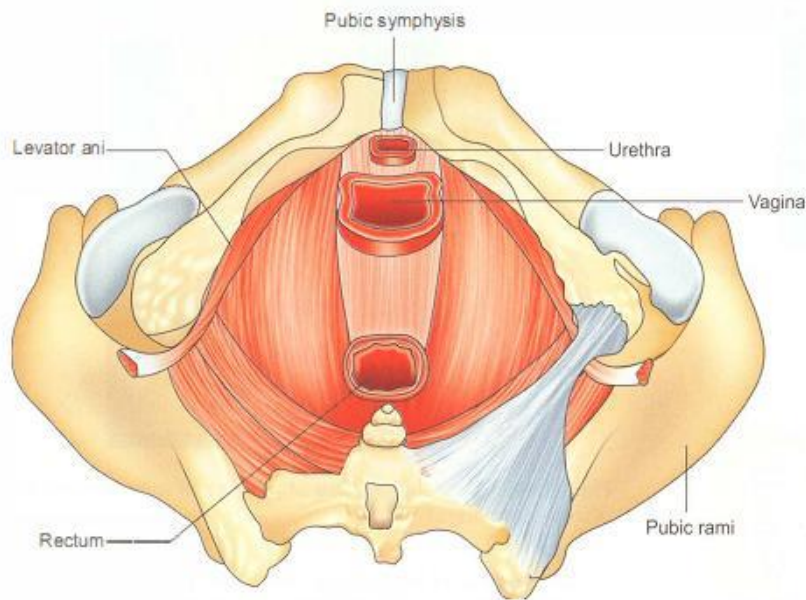
Causes

1. In infants, it is due to undeveloped sacral curve and in children it can be secondary to habitual constipation.
2. It can follow an attack of whooping cough or excessive straining.
3. It can follow an attack of dia-hoea resulting in loss of fat in the ischio-rectal fossae, which supports the rectum.
4. In adults it is common in females mostly due to Torn perineum caused by obstetric trauma.

COMPLETE/TOTAL PROLAPSE

- Full thickness prolapse is also called procidentia.
- It is defined as protrusion of the rectum for more than 3.7. cm outside the anal verge. Very often, it is the entire rectum which protrudes out on straining, sometimes along with the peritoneal sac.
- Often, it is associated with prolapse uterus.

The pelvic floor-surgical anatomy (Fig. 7)



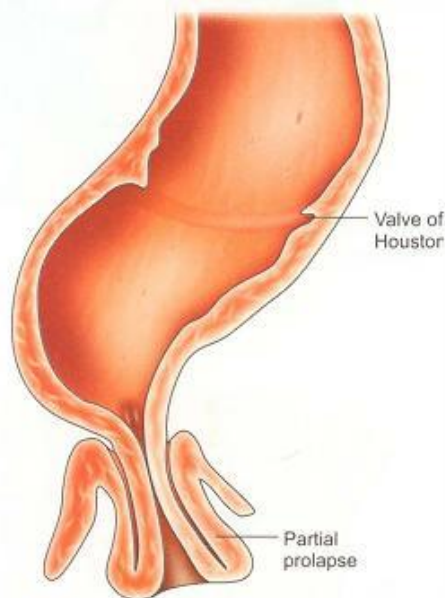
Pelvic floor anatomy—weakness of the pelvic floor is an important cause of prolapse rectum

(Fig. 7)

- It is composed of the two levator ani and a puborectalis muscle.
- Levator ani originate from pelvic side walls and sacrospinous ligament. It suspends the rectum in a muscular sling which ends when puborectalis angulates rectum.
- Puborectalis muscle takes origin from posterior aspect of pubis, forms a sling around rectum and return to posterior pubis.
- Contracted puborectalis is responsible for normal acute anorectal angle and it is critical for maintaining continence. Thus during coughing, sneezing, anorectal angle becomes more acute, increasing continence.

Supports of the rectum and surgical importance

Various supports of the rectum keeps the rectum in place. Failure of one or more of these factors may precipitate rectal prolapse (Fig. 8). They have been enumerated in the following lines.



Prolapsed rectum—diagrammatic representation, sometimes confused for prolapsed haemorrhoids

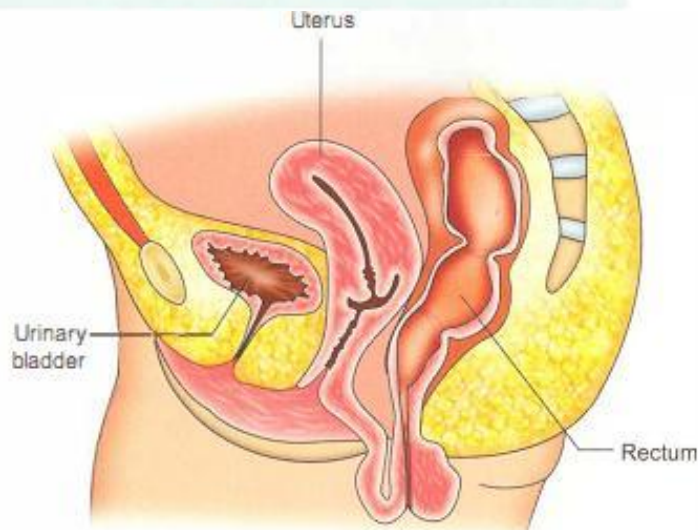
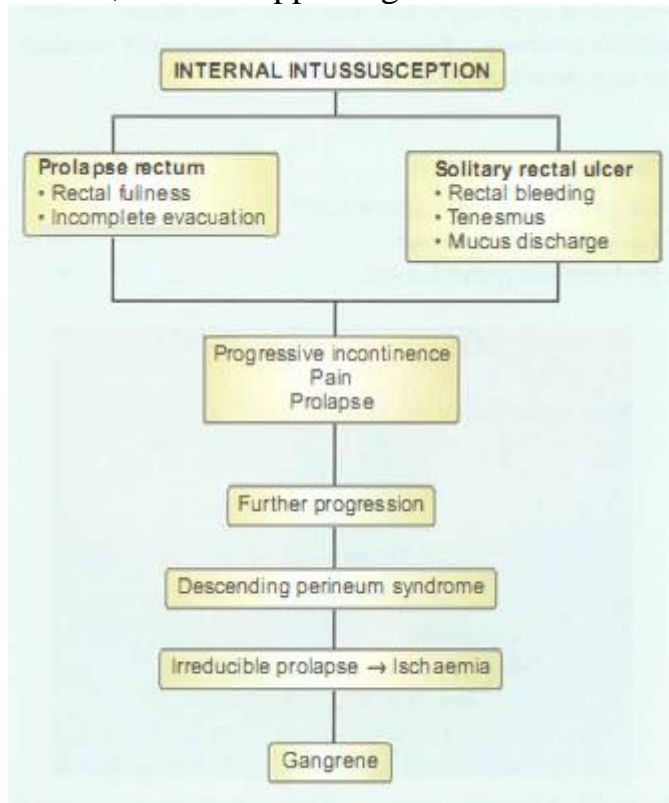
(Fig. 8)

1. Pelvic floor: Weakness of pelvic floor can be due to birth injuries or due to defective collagen maturation.
2. Lateral ligaments: These ligaments are due to condensation of pelvic fascia on each side of the rectum. Excessive mobility of these ligaments may be the contributing factor for prolapse rectum.
3. Fascia of Denonvilliers (rectovesical fascia): Deep rectovesical pouch is often found in prolapse rectum. In all cases of complete prolapse rectum, please look for the deep rectovesical pouch and if it is present it should be obliterated.
4. Fat supports the rectum. Hence, any chronic illness and loss of it may contribute for prolapse rectum.

Causes

1. Common in elderly women who are multipara. Probably, it is due to repeated birth injuries to the perineum causing damage to the nerve fibres. As age advances, muscles become weak. This, together with fatty degeneration of the muscle, results in prolapse rectum.
2. Excessive straining causes weakness of the supports of the rectum.
3. Defective collagen maturation results in failure of rectal support by levators and pelvic fascia.
4. Presence of deep rectovesical pouch and excessive mobility of the rectum (mesorectum) predisposes to prolapse of the rectum.
5. Many people believe that prolapse of the rectum starts as an intussusception in the first stage, initiated by certain factors such as diarrhoea, constipation and disorder of the pelvic floor. The process starts with anterior wall of

rectum, where supporting tissues are weakest.(Fig. 9)



Prolapse of the rectum with uterus: Procidentia— not an uncommon presentation specially in multipara women

(Fig. 9)

Clinical features

- Female-male ratio is 6 : 1.
- Constipation is an important feature of rectal prolapse.

- Excessive mucus discharge causing irritation to the perianal skin. Tenesmus is also common.
- On asking the patient to strain at stool, the rectum descends down, which clinches the diagnosis.
- Some degree of incontinence of faeces and flatus is always present. It gives rise to urgency and perianal soiling.
- Rectal examination-lax anal sphincter and wide gaping on straining.
- Procidentia

TREATMENT: Surgical procedures-aim

1. Safe procedure to correct with minimal morbidity and without mortality. They are classified as perineal procedures and abdominal procedures.
2. To cure or to improve incontinence.

I. PERINEAL PROCEDURES

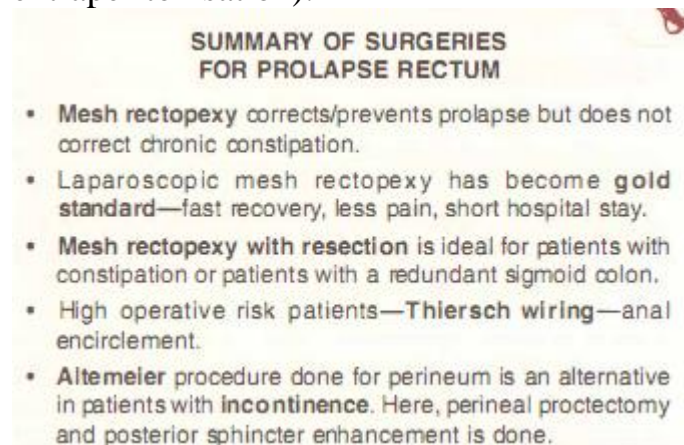
1. Delorme's procedure (reeing the rectal mucosa): In this, the prolapse is completely everted, mucosa is stripped and muscle coat is plicated. Mucosal continuity is maintained by suturing anal canal mucosa below to the rectal mucosa above. This is an easy operation to do in elderly patients. However, relapse rates are high and it does not correct the defect.
2. Altemeier's procedure: In this operation, full thickness of the prolapsed rectum with part of sigmoid is excised followed by anastomosis of part of the sigmoid to the anal canal from below. To improve continence, plication of levator ani and puborectalis muscle is done. Urgency and incontinence are the features because of removal of rectum.
3. Thiersch wiring: In this operation, a steel wire or a thick silk suture is applied all around the anus after reducing the prolapse. The knot is tightened around a finger. Patients with poor surgical compliance benefit from this operation. However, breakdown of the wire, perianal sepsis and anal stenosis are the complications.

II. ABDOMINAL PROCEDURES

1. Wells operation: A laparotomy is done, rectum is pulled upwards and is sutured to the sacrum posteriorly with the help of a polyvinyl alcohol sponge kept behind the rectum. The sponge is sutured posteriorly and laterally to the walls of the rectum. Dense fibrotic reaction occurs resulting in fixation of the rectum to the sponge.
2. Ripstein sling operation: After a laparotomy, the rectosigmoid junction is sutured to the sacrum by using Teflon sling, below the sacral promontory. One complication of this operation is constipation due to rectosigmoid angulation. Hence, sigmoidectomy has been suggested along with this operation.

3. Mesh rectopexy: Instead of polyvinyl sponge, a marlex mesh can be kept behind the rectum. This is sutured behind, to the sacrum and then to the posterior and lateral surfaces of rectum. Laparoscopic method of fixing the mesh has become popular. This is the procedure of choice today. Constipation is one of the complications of mesh rectopexy. Hence, some resect sigmoid with this procedure (Goldberg operation).

4. Lahaut's operation: Anchoring rectosigmoid to rectus sheath (extraperitonisation).



HAEMORRHOIDS

Definition

Dilated plexus of superior haemorrhoidal veins, in relation to anal canal.

Classification-aetiological

I. Primary/Idiopathic haemorrhoids

1. Standing posture: It has been told nicely that varicosity is the penalty for verticality against gravity. It is also true of haemorrhoids. It is true that animals do not develop haemorrhoids.

Thus man's upright posture and absence of valve in the portal system with other factors precipitate development of haemorrhoids

2. Haemorrhoidal veins and their branches are the thin veins which pass through submucosa of the rectum. They get compressed due to contractions caused by rectal musculature (the sphincters) during the act of defaecation.

3. Genetic/ familial factors: Absence of valves, or congenital weakness of the vessel wall are few other factors contributing for the haemorrhoids

4. Diet: A diet deficient in fibres which prolongs the gut transit results in constipation and small hard pellet like stools. The hard stools compress veins and result in haemorrhoids.

II. Secondary haemorrhoids

Causes

1. Carcinoma of rectum, by blocking the veins, can produce back pressure and can manifest as piles.
2. Portal hypertension-uncommon cause of rectal varices.
3. Pregnancy, due to compression on superior rectal veins or due to progesterone which relaxes smooth muscle in the wall of the veins, can cause haemorrhoids.

Current view: Latest theory is that haemorrhoids occur due to caudal displacement of anal cushions. It is due to recurrent trauma, shearing forces, loss of elasticity. Thus normally the cushions retract after defaecation.

Location

Classically situated in the 3, 7, 11 o'clock positions (left lateral, right posterior and right anterior respectively).

- Superior haemorrhoidal artery (vein) gives 2 branches on right side and 1 branch on left side. Hence, piles are two on right side and one on left side.

Clinical features

Grades of haemorrhoids		
Grades	features	Symptoms
I.	Never prolapse	Bleeding per rectum
II.	Prolapse on defaecation Spontaneous reduction	Something coming down and going back
III.	Prolapse on defaecation requires manual reduction	Something coming down, bleeding, mucus discharge, pruritus
IV.	Permanent prolapse	Acute pain, throbbing discomfort

- Painless bleeding-fresh bleeding occurs after defecation Splash in the pan. This causes chronic anaemia. Haemorrhoids which bleed are called Grade I haemorrhoids.
- The capillaries of the lamina propria are only protected by a single layer of epithelial cells. Hence, minor trauma precipitates bleeding.
- As the straining increases, the haemorrhoids partly prolapse outside. After defaecation, it returns back (Grade II) or can be digitally replaced (Grade III haemorrhoids).
- Permanently prolapsed pile outside (Grade IV haemorrhoids). The patient complains of pain or discomfort.
- Most of the patients complain of constipation.
- Discharge of mucus and soiling of perianal skin-pruritus by prolapse of haemorrhoidal cushions and mucosa

III. Depending upon the location of haemorrhoids

1. Internal haemorrhoids—above the dentate line, covered with mucous membrane.
2. External haemorrhoids—at anal verge, covered with skin.
3. Interno-external—both varieties together.

Investigations

- Per rectal examination is done mainly to rule out carcinoma rectum or other causes of bleeding per rectum. Haemorrhoids cannot be felt by rectal examination unless they are thrombosed or fibrosed.
- Proctoscopy: As the obturator is removed, piles prolapse into the lumen of proctoscope as cherry red masses.

TREATMENT OF HAEMORRHOIDS

A. Nonoperative treatment: It is indicated in Grade I and Grade II piles which are not causing significant bleeding or discomfort.

NONOPERATIVE TREATMENT

- Fibre supplementation
- Increased fluid intake
- Bulk purgative—laxatives—ispaggl husk, etc.
- Reading in toilet to be discouraged (respond to call and do not strain)
- Encourage to lose weight

*Remember as **FIBRE***

B. Injection of sclerosant: 5% phenol in almond oil is injected into submucosa above the dentate line. Hence, it is painless. It produces aseptic thrombosis of pile mass and is indicated in Grade I. The injection is perivascular.

C. Barron's band application: It is indicated for grade II and grade III haemorrhoids, wherein bands are applied at the neck of the haemorrhoids. It causes necrosis and thus piles get fibrosed. One or two can be banded at a time.

BAND LIGATION: WISDOM LINES

- Bands should be applied 1–2 cm above dentate line to avoid pain.
- Bands should not be applied in patients who are taking **anticoagulants**.
- Bands **should not be applied for immunocompromised** patients without broad spectrum antibiotics to avoid life-threatening sepsis.
- **Should not band all the three pile masses** at same time. Quadrant by quadrant with a gap of 2 weeks is ideal.
- If severe pain, fever and urinary retention develops after band (sepsis), examine under general anaesthesia and remove band.

D. Operative treatment: Hemorrhoidectomy. Open method, closed method, stapler haemorrhoidopexy.

HEMORRHOIDECTOMY

INTERESTING WISDOM IN HAEMORRHOIDS

- Haemorrhoids occur due to downward prolapse of vascular cushions into and beyond anal canal.
- Minimum ideal investigation for haemorrhoids should be **flexible sigmoidoscopy**.
- Preserve adequate **mucocutaneous bridges** in excisional procedures to **prevent anal stenosis**.
- **Urgency and tenesmus** following stapled haemorrhoidoscopy responds well to **oral nifedipine**.
- **Metronidazole** is the most important agent in **reducing pain** after haemorrhoid surgery.
- Grade I and II can be injected: **Injections** should be **perivascular, submucosal** and above the level of dentate line.
- Grade III require haemorrhoidectomy or haemorrhoidopexy
- Grade IV require initial conservative treatment followed by surgical procedure.

Excision of the pile masses up to base is indicated in Grade II and Grade III hemorrhoids. It can be done by 3 methods: Open, closed and with stapler (vie ira).

Types

I. Open method: Milligan-Morgan ligature and excision

- Stretch the sphincter
- Identify the positions of pile masses
- Dissection up to the base (pedicle)
- Transfixation ligature with nonabsorbable silk
- Excision of the piles with skin
- Trimming the wound
- Haemostasis obtained
- Wound packed with roller gauze
- A tube drainage is provided so that the blood (oozing) can escape outside.

II. Closed method (Hill-Ferguson)

- Basic steps are the same as above
- Cut mucosa and skin edges are sutured with absorbable catgut sutures.

Postoperative management

1. Strong analgesics, in the form of injection pethidine or morphine, are given to reduce the pain.
2. Antibiotics along with metronidazole are given to prevent secondary infection.
3. Bulk purgatives are given to avoid constipation.
4. Sitz bath twice a day is given by using warm saline or KMnO₄ solution.

Postoperative complications

They can be classified into early and late complications. Acute retention of urine and haemorrhage are early complications: Anal stricture, anal stenosis, anal fissure and incontinence are the late complications. Few complications are described below

1. Retention of urine is common in men due to severe pain. It can be managed by treating the pain and hot water fomentation in the suprapubic region. Catheterisation is done as a last resort.
2. Reactionary haemorrhage is more common. It is due to loose ligature or some opened up bleedings. Generally stop by pressure packing. Otherwise, under anaesthesia, ligate or cauterise bleeding point
3. Secondary haemorrhage can occur due to infection. It manifests 6 to 8 days later. If the bleeding is significant exploration in the operation theatre may be necessary. It should be done under anaesthesia. With good illumination it is possible to identify the bleeding points and ligate them
4. Anal stenosis can occur if too much skin is excised during haemorrhoidectomy. It needs regular dilatation.
5. Anal fissure, submucous abscess, and incontinence can occur after haemorrhoidectomy.
6. Wound infection: Minor degree of wound infection does occur and can be treated with sitz bath, antibiotics and regular dressings.

Literature:

1. K Rajgopal Shenoy, Anitha Shenoy. Manipal Manual of Surgery. CBS Publishers & Distributors. Fourth Edition. 772-885.
2. Harold Ellis, Sir Roy Calne, Christopher Watson. General Surgery Lecture Notes. Wiley BlackWell. 2016. 206-233
3. GOLIGHER JC, LEACOCK AG, BROSSY JJ. The surgical anatomy of the anal canal. *Br J Surg.* 1955 Jul;43(177):51-61
4. Parks AG, Gordon PH, Hardcastle JD. A classification of fistula-in-ano. *Br J Surg.* 1976 Jan;63(1):1-12
5. Abcarian H, Smith D, Sharon N. The immunotherapy of anal condyloma acuminatum. *Dis Colon Rectum.* 1976 Apr;19(3):237-244
6. egal I, Solomon A, Hunt JA. Emergence of diverticular disease in the urban South African black. *Gastroenterology.* 1977 Feb;72(2):215-219.

7. Nusbaum M, Baum S, Blakemore WS, Tumen H. Clinical experience with selective intra-arterial infusion of vasopressin in the control of gastrointestinal bleeding from arterial sources. *Am J Surg.* 1972 Feb;123(2):165–172.
8. Gallagher DM, Russell TR. Surgical management of diverticular disease. *Surg Clin North Am.* 1978 Jun;58(3):563–572.
9. Holzheimer RG, Mannick JA, editors. Munich: Zuckschwerdt; 2001. *Surgical Treatment: Evidence-Based and Problem-Oriented.*
10. Samuels AD, Weese JL, Berman PM, Kirsner JB. An epidemiologic and demographic study of inflammatory bowel disease in black patients. *Am J Dig Dis.* 1974 Feb;19(2):156–160.

All the illustrated materials are taken from «Manipal Manual of Surgery. CBS Publishers & Distributors. Fourth Edition. Edited by K Rajgopal Shenoy, Anitha Shenoy»