

**State budgetary educational institution of higher  
professional education**

**"North Ossetian State Medical Academy" of the Ministry of  
health of the Russian Federation**

**Department of surgical diseases No. 2**

**Kalitsova M. V., Totikov Z.V.**

# **PERFORATED ULCER OF THE STOMACH AND DUODENUM**

Textbook for students of the 4th year  
of the Faculty of Dentistry in the discipline "Surgical Diseases"

Vladikavkaz

2022

Kalitsova M. V., Totikov Z.V.

Perforated ulcer of the stomach and duodenum: teaching guide for students, studying at “Surgical Diseases” Dentistry faculty. - North Ossetian state medical academy. - Vladikavkaz, 2022. - 28 sh.

This teaching guide covers main issues about etiology, pathogenesis, clinical features, laboratory and instrumental diagnostics and complications of Perforated ulcer of the stomach and duodenum.

Teaching guide “Perforated ulcer of the stomach and duodenum” is made for “Surgical Diseases” discipline in accordance with requirements of FSES HE, and is intended for students from medical universities and faculties, studying for specialty 31.05.03 Dentistry.

Recensents:

Tomaev M.V., Chief Surgeon of the CHEC of the RNO-A, 10.03.2022.

Beslekov U.S., MD, Associate Professor, Head of the Department of Surgical Diseases No. 1 of the Federal State Budgetary Educational Institution of Higher Education NOSMA of the Ministry of Health of Russia, 10.03.2022.

Approved and recommended for printing by Central Coordinational educational and methodical board FSES HE NOSMA of Russian Ministry of health (№ 4 22.03.22)

© North Ossetian State Medical Academy, 2022

© Kalitsova M.V., Totikov Z.V., 2022

## CONTENTS

Surgical anatomy .....	4
Physiology.....	9
Ulcer disease.....	11
Clinical features.....	14
Treatment.....	15
Perforated ulcer.....	21

## SURGICAL ANATOMY

### Fundus

Part of the stomach which projects upwards and lies in contact with the left dome of diaphragm. It is usually full of gas.

#### Significance

- To identify the side (right or left) of the body in a plain X-ray abdomen.
- In achalasia cardia, fundic air bubble is absent.
- Fundic 'Wrap' is used in hiatus hernia.
- During mobilisation of the fundus as in splenectomy or other upper gastric surgery, short gastric arteries need to be divided. If ligatures are too close to the stomach near the fundus, gastric fistula may occur due to necrosis of the stomach.
- GISTs (gastrointestinal stromal tumours) are common in fundus.

### Body

Extends from fundus to incisura angularis. It has a lesser curvature and a greater curvature.

#### Significance

- Ability to have a large meal is due to receptive relaxation of the body of the stomach.
- Greater curvature is located at the level of umbilicus.
- Classical gastrojejunostomy (GJ), anterior or posterior, involves using body of the stomach.
- Posteriorly, it is related to the lesser sac and pancreas. Carcinoma of the body may infiltrate pancreas- necessitates careful dissection to separate from pancreas (sometimes not resectable).

### Pyloric antrum

It extends from incisura till pylorus. Pylorus is thicker than the rest of the stomach. It is a sphincter of circular muscle fibres. Its canal is usually closed.

#### Significance

- Pyloric antrum is a common site for gastritis, ulcer and carcinoma.
- Incompetence of pyloric sphincter results in severe duodenogastric reflux.
- It is in close contact with the head of pancreas. During gastrectomy, extreme care has to be taken to mobilise the antrum to avoid bleeding in the pancreatic head region.

Anatomy and surgical significance			
2 Orifices	Recognition	Pathology	Result
• Pyloric orifice	Recognised by prepyloric vein of Mayo	Incompetence causes duodeno-gastric reflux	Biliary gastritis
• Cardiac orifice	Lower end of oesophagus	Incompetence causes acid reflux into lower end of oesophagus	Barrett's oesophagus
2 Curvatures			
• Lesser curvature	Concave lesser omentum is attached to it	Site of benign gastric ulcer	Hour-glass contracture
• Greater curvature	Convex greater omentum is attached to it	Site of carcinomatous ulcer	Carcinoma stomach
Part	Common pathology	Commonly used for	Nature of the condition
• Fundus	GIST	Fundic wrap	Hiatus hernia
• Body	Carcinoma	Gastrojejunostomy	Pyloric stenosis
• Pylorus	Pyloric stenosis, carcinoma	Pyloric myotomy in idiopathic pyloric stenosis	

### Greater curvature

It lies in contact with transverse colon and gastrocolic omentum (Fig. 1). This has to be divided from transverse colon during gastrectomy which is done or carcinoma or ulcer.

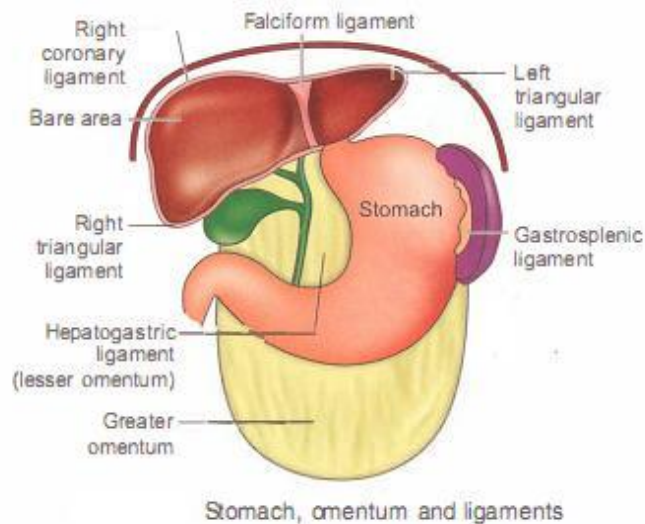


Fig. 1

**GREATER OMENTUM IS A FRIEND AND  
SOMETIMES ENEMY OF THE PATIENT  
AND THE SURGEON**

- The greater omentum is the **policeman** of the peritoneal cavity. It exhibits **protective action** in inflammatory processes and perforations.
- **Omentoplasty** (omental wrapping of anastomosis) may decrease the occurrence of anastomotic leakage when oesophagogastric anastomosis is performed for cancer of oesophagus or as in closure of duodenal perforation.
- It has many **important applications** and can be used in colorectal surgery, reconstruction of the irradiated pharyngeal wound and packing of bleeding liver wounds.
- It was used to **treat peripheral vascular disease** such as TAO wherein direct arterial surgery was not possible.
- It becomes an enemy when involved with metastasis or directly by malignant neoplastic process from ovary or colorectal cancer. Omentum is one of the common sites of involvement in tuberculosis also. Omentum itself can act like a **band** and can cause intestinal obstruction.

### Lesser omentum

- The lesser omentum is a double-layered structure.
- It is suspended between the lesser curvature of the stomach and the proximal 0.5 inch (2 cm) of the first part of the duodenum inferiorly and the porta hepatis and the fissure of the ligamentum venosum superiorly.

The lesser omentum is divided into two ligaments:

1. Hepatogastric
2. Hepatoduodenal: Located within the lesser omentum are the hepatic triad, branches of the anterior vagus nerve, some lymph nodes, and the right and left gastric arteries.

### Vagus nerves

- The left and right vagus nerves descend parallel to the oesophagus and form oesophageal vagal plexus between the level of the tracheal bifurcation and level of the diaphragm.
- From this plexus, two vagal trunks, anterior and posterior form and pass through the oesophageal hiatus of the diaphragm (mnemonic LARP: Left trunk-anterior gastric wall; right trunk-posterior gastric wall).

### Blood supply of the stomach (Fig. 2)

It is mainly supplied by coeliac trunk and its branches:

1. Left gastric artery is a direct branch of coeliac trunk. It ascends up to oesophageal hiatus and runs to the right along the lesser curvature of stomach. It branches and anastomoses with branches of right gastric artery and supplies anterior and posterior wall of the stomach. There is true anastomosis between branches of left gastric artery and branches from other arteries.

2. Right gastric artery is a branch of hepatic artery which comes from coeliac trunk. It also supplies lesser curvature and body of stomach, along with left gastric artery.
3. Left gastroepiploic artery arises from splenic artery and supplies greater curvature of stomach and anastomoses with right gastroepiploic artery.
4. Right gastroepiploic artery is a branch of gastroduodenal artery, which is a branch of hepatic artery.
5. Short gastric arteries are the branches of splenic artery. They supply the fundus of the stomach. They are also called vasa braevia.

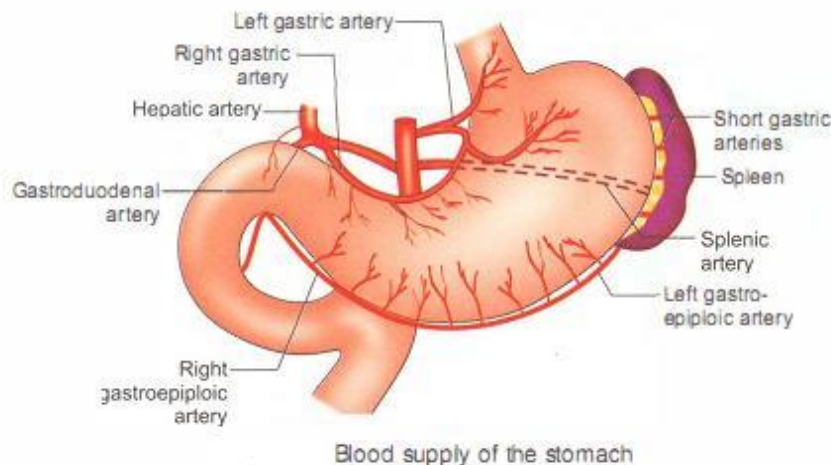


Fig. 2

#### Venous drainage

- Veins run with the corresponding arteries.
- Right and left gastric veins drain into the portal vein directly.
- Right gastroepiploic vein joins superior mesenteric vein.
- Left gastroepiploic vein and vasa braevia join splenic vein
- Prepyloric vein of Mayo is a useful guide to the junction between stomach and duodenum.

#### Surgical importance

- Because of extensive anastomoses of blood vessels, (extramural and intramural collateral vessels) stomach can survive with right gastric and right gastroepiploic arteries only. Thus stomach can be used to replace the entire oesophagus after oesophagectomy-gastric pull up.
- The order of ligation of blood vessels in gastrectomy is as follows: Left gastroepiploic, right gastroepiploic, right gastric (then stomach is divided) and lastly, left gastric artery.
- Gastroduodenal artery, a branch of hepatic artery runs behind first part of duodenum and divides into right gastroepiploic artery and superior pancreaticoduodenal artery.
- It is this artery which bleeds when a posterior duodenal ulcer erodes into it.



### Lymphatic drainage (Fig. 3)

It is an important pathway for spread of carcinoma of the stomach. The spread occurs both by emboli and permeation.

1. Right gastric nodes/suprapyloric nodes, mainly drain the pyloric antrum.
2. Subpyloric nodes/gastroepiploic nodes (right) drain the greater curvature of stomach and pyloric antrum.
3. Left gastroepiploic nodes (splenic nodes) drain the upper portion of stomach, mainly the fundus (carcinoma of fundus).
4. Left gastric (superior gastric) nodes drain the lesser curvature and body of the stomach (anterior and posterior wall).
5. Coeliac nodes receive lymph from the entire foregut (including stomach) and drain directly into the cisterna chyli and the thoracic duct. Later, mediastinal nodes and left supraclavicular nodes (Virchow nodes) are involved.

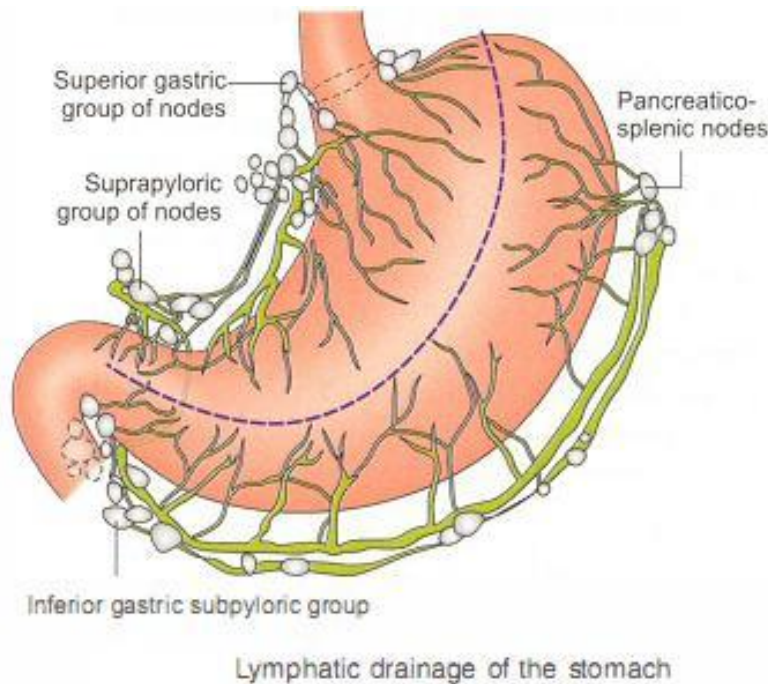


Fig. 3

### Lymphatics of the stomach

The lymphatics of the stomach are formed from two networks: Intrinsic and extrinsic.

**Intrinsic network:** The submucosal lymphatic plexus is perhaps the richest in anastomoses.

- Upward invasive spread of gastric cancer to the oesophagus is common but downward mucosal or submucosal invasion of the duodenum is not common.
- Hence, gastrectomy with distal oesophagectomy is done for carcinoma of the proximal stomach.

**Extrinsic network:** The extrinsic lymphatic vessels of the stomach follow the gastric veins.



- They drain to perigastric lymph nodes, which in turn drain to the lymph nodes located at the coeliac axis.
1. The superior gastric group drains lymph from the upper lesser curvature into the left gastric and paracardiac nodes.
  2. The suprapyloric group of nodes drains the antral segment on the lesser curvature of the stomach into the right suprapancreatic nodes.
  3. The pancreaticolienal group of nodes drains lymph high on the greater curvature into the left gastroepiploic and splenic nodes.
  4. The inferior gastric and subpyloric group of nodes drains lymph along the right gastroepiploic vascular pedicle.
- All four zones of lymph nodes drain into the coeliac group and then into the thoracic duct.

## GASTRIC PHYSIOLOGY

### Gastric acid secretion

Gastric secretion			
	Cells	Location	Function/mediators
1. Acid secretion 150–160 mEq/L	• Oxyntic glands, principal cell type is parietal	• Fundus and body	• Cephalic—vagus • Gastric—gastrin
2. Mucus	• Columnar epithelium	• Entire stomach	• Intestinal—not clear • Luminal cytoprotection from acid, pepsin and ingested substances
3. Pepsinogen I and II	• Chief cells—located in deeper areas of oxyntic gland	• Body and fundus	• Vagal stimulation
4. Mucus, gastrin	• Antrum	• Antrum	• Cytoprotection
5. Bicarbonate	• Mucus cells	• Stomach	• Vagal stimulation increases $\text{HCO}_3^-$ secretion • Prostaglandin $\text{E}_2$
6. Intrinsic factor	• Parietal cells	• Fundus	• Necessary for absorption of $\text{B}_{12}$
7. Peptides, histamine	• Enterochromaffin like (ECL) cells • D cells (delta)	• Fundus • Antrum	• Release of peptides • Somatostatin inhibits acid secretion

- Gastric acid secretion by the parietal cells is regulated by three local stimuli: 1. Acetylcholine, 2. Gastrin, 3. Histamine.
- These three stimuli account for basal and stimulated gastric acid secretion.
- Acetylcholine is the principal neurotransmitter modulating acid secretion and is released from the vagus and parasympathetic ganglion cells.
- Vagal fibres innervate not only parietal cells but also G cells and enterochromaffin-like (ECL) cells to modulate release of their peptides.
- Gastrin has hormonal effects on the parietal cell and stimulates histamine release. (Fig.4)

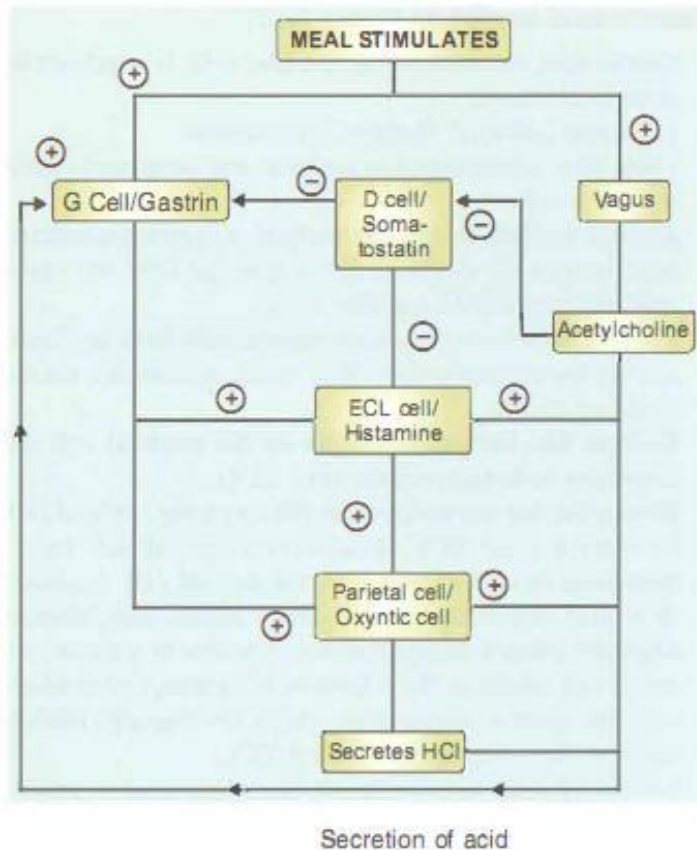


Fig.4

- Histamine has paracrine-like effects on the parietal cell. Its release from ECL cells plays a central role in the regulation of acid secretion by the parietal cell. Ingestion of a meal stimulates vagal fibres to release acetylcholine (cephalic phase). Binding of acetylcholine to parietal cell and G cell results in the release of histamine, hydrochloric acid and gastrin, respectively. Acetylcholine also inhibits somatostatin release by inhibiting ECL.
  - Following a meal, G cells are also stimulated to release gastrin, which interacts with receptors located on ECL cells and parietal cells to cause the release of histamine and hydrochloric acid (gastric phase). Release of somatostatin from D cells decreases histamine release and gastrin release from ECL cells and G cells, respectively. In addition, somatostatin inhibits parietal cell acid secretion.
- The principal stimulus or activation of D cells is antral luminal acidification .
- As depicted, somatostatin exerts inhibitory actions on gastric acid secretion.
  - Release of somatostatin from antral D cells is stimulated in the presence of intraluminal acid to a pH of 3 or less.
  - After its release, somatostatin inhibits gastrin release through paracrine effects and also modifies histamine release from ECL cells.
  - In some patients with peptic ulcer disease (PUD), this negative feedback response is defective.

- Consequently, the precise state of acid secretion by the parietal cell is dependent on the overall influence of the positive and negative stimuli.

## PEPTIC ULCER DISEASE

### Definition

Acid peptic digestion of the alimentary mucosa resulting in an ulcer is called peptic ulcer disease (PUD). The corrosive effects of acid with proteolytic effect of pepsin are responsible for PUD. Duodenum and stomach are the common sites of peptic ulcer disease. Rarely, they can occur in the jejunum and in Meckel's diverticulum when it contains ectopic gastric mucosa.

### Types of peptic ulcer

#### I. Depending on the site

- A. Chronic duodenal ulcer: Typically occurs in the first inch of the first part of the duodenum.
- B. Chronic gastric ulcer: Occurs in the lesser curvature adjacent to acid secretion parietal cell mass.
- C. Combined: Gastric ulcer type II
  - Zollinger-Ellison syndrome
- D. Anastomotic ulcer

#### II. Depending on the duration

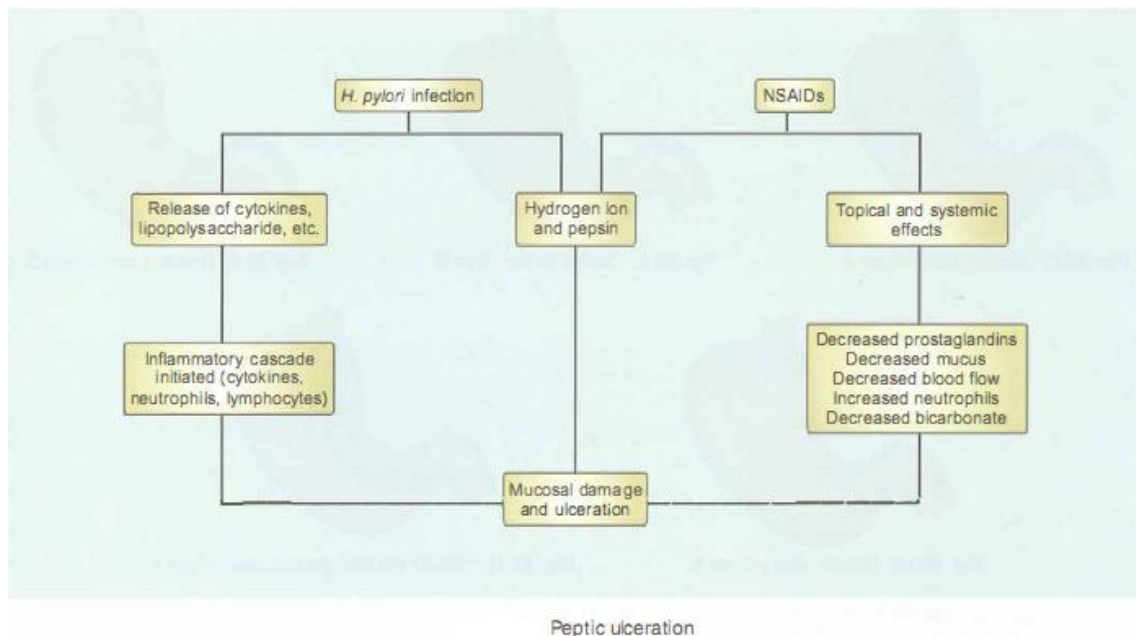
- A. Chronic peptic ulcer
- B. Acute peptic ulcer.

## CHRONIC PEPTIC ULCER-PEPTIC ULCER DISEASE (PUD)-AETIOLOGY

### CHRONIC DUODENAL ULCER (CDU)

Hyperacidity is the chief cause of duodenal ulcer. No acid, no ulcer still holds good for CDU.

1. Neurological causes: Stimulation of vagus increases secretion of acids. This is brought about by anxiety, worry, hurry and curry.
2. Nonsteroidal anti-inflammatory drugs: They are responsible for gastric ulcer rather than duodenal ulcer by altering mucosal defence.
3. Genetic causes: Family history of duodenal ulcer may be present in a few cases which suggests a genetic cause.
  - Patients with blood group 'O' are more prone, for the development of CDU because of increased parietal cell population.
4. Food habits: Spicy food, diet poor in vitamins, smoking and alcohol, alone or in combination precipitate the development of chronic duodenal ulcer.
5. Bacteriological causes (Fig. 1)



(Fig. 1)

- *Helicobacter pylori*, a spirochaetal bacteria has been demonstrated in the submucosa of the antrum and duodenum, from the biopsies of the ulcer. It increases pH levels by splitting urea and releasing ammonia. Rise in pH results in proliferation of bacteria.

#### 6. Endocrinal causes

- Zollinger-Ellison syndrome is a non- $\beta$  cell tumour of the pancreas with hypergastrinemia.
- Hyperparathyroidism causes increased levels of calcium which stimulates the parietal cell mass resulting in hyperacidity.

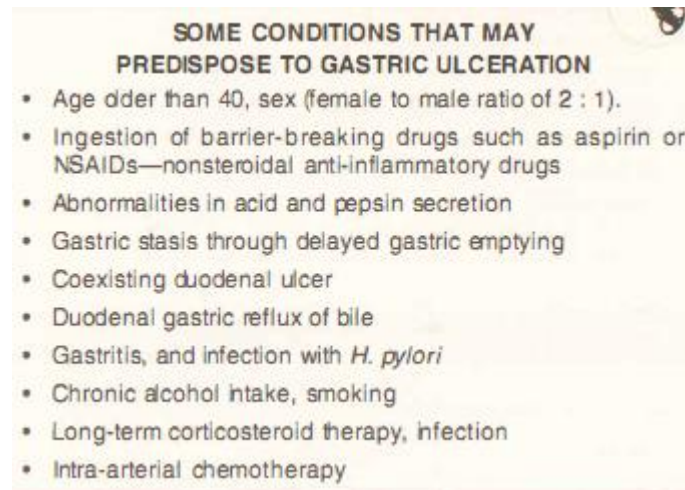
#### Pathophysiology of duodenal ulcer

- Duodenal ulcer is a disease of multiple aetiologies.
- The only absolute requirements are acid and pepsin secretion in combination with either infection with *H. pylori* or ingestion of NSAIDs.
- Although there is a strong correlation between parietal cell number and MAO, only patients with duodenal ulcers have an increase in mean parietal cell number, whereas gastric ulcer patients do not.

#### CHRONIC GASTRIC ULCER

- In majority of the patients there is no hyperacidity. Many patients have hypoacidity, or normoacidity.
- Ulcer occurs due to a defective gastric mucosal barrier. This barrier is a coat of thick mucus which is impermeable to pepsin.
- Prostaglandins normally present in the gastric mucosa do not allow back diffusion of hydrogen ions from the lumen.

- Nonsteroidal anti-inflammatory drugs inhibit the production of prostaglandins causing a loss of protective activity.
- This can also be damaged by smoking, spicy food, alcohol and reflux of bile into the stomach.



### Classification (Johnson) Types (Fig 2)

I. Acute superficial: Single or multiple (erosions)

II. Chronic

Type 1: Primary gastric ulcer on the lesser curvature in the antrum near the junction of oxyntic cells and central mucosa.

Type 2: Gastric ulcer with duodenal ulcer.

Type 3: Prepyloric or channel ulcer.

Type 4: High gastric ulcer (cardia, proximal stomach) < 2 cm from oesophageal junction.

Type 5: NSAID-induced gastric ulcers.

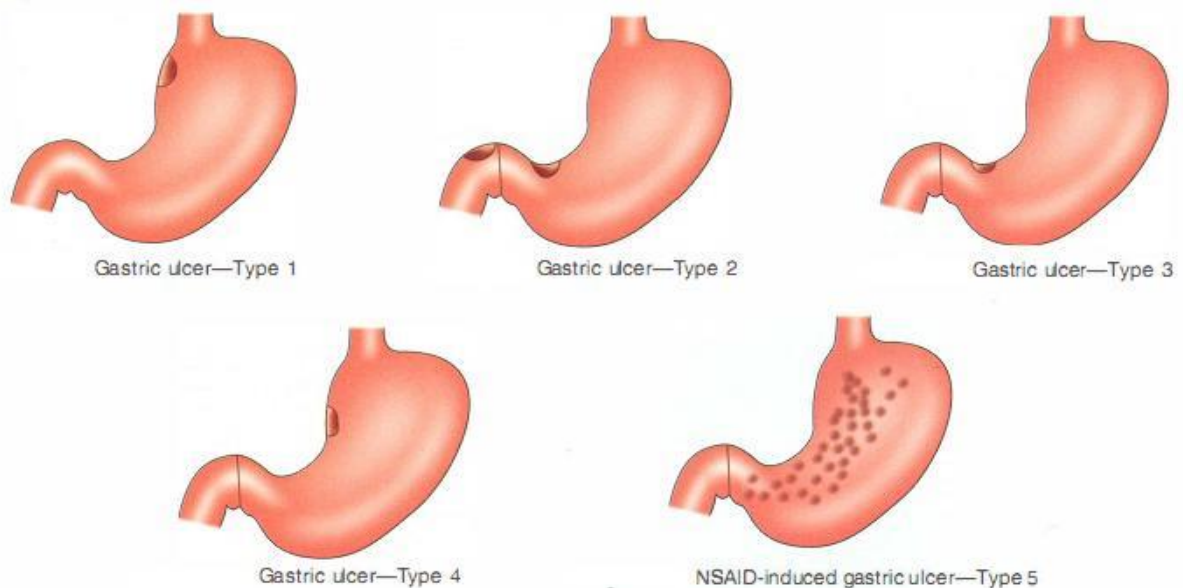


Fig 2.



### GIANT GASTRIC ULCER

- Diameter > 3 cm
- Typically lesser curvature
- Incidence of malignancy—10%
- High chances of perforation and bleeding.
- Medical treatment heals majority of cases (80%)
- Re-endoscopy biopsy is a must to look for healing and also to rule out malignancy
- Gastrectomy including ulcer bed. Add vagotomy for type 2 and type 3 gastric ulcer

## CLINICAL FEATURES

Comparison of clinical features		
	Chronic duodenal ulcer	Chronic gastric ulcer
1. Incidence	Common	Less common
2. Site	1st inch of 1st part of duodenum	The lesser curvature or prepyloric region
3. Pain	It is due to the acid irritating the ulcer (hunger pain). It is relieved on taking food. After 1–2 hours of food, the pain becomes severe. It is burning in nature with retrosternal radiation (heart burn) and increased salivation (water brash)	Pain occurs on taking food and it is relieved by induced vomiting. Pain is of burning nature as in duodenal ulcer
4. Vomiting	Never occurs in duodenal ulcer till the patient develops pyloric stenosis	Frequent and it occurs immediately after patient takes food
5. Weight	Weight gain	Weight loss
6. Periodicity	Common	Less
7. Haematemesis : melaena ratio	40 : 60	60 : 40
8. Incidence of malignancy	Never becomes malignant	0.5–5% (2%)
9. On examination	Tenderness in the right hypochondrium	Tenderness in the epigastrium

## Investigations

1. Oesophagogastroduodenoscopy (OGD): Ulcer appears as a crater with/without slough or bleeding in their typical locations. In gastric ulcers, routine biopsy is advised to rule out malignancy. In duodenal ulcers, biopsy is done in recurrent cases to rule out *Helicobacter pylori*.

- In long-standing duodenal ulcers, there may be narrowing of the pylorus, with stasis of food in the stomach suggestive of pyloric stenosis.

- Other uses of OGD.

2. Barium meal study (historical-obsolete now)

- Duodenal ulcer: Deformed duodenal cap. Trifoliate deformity is seen when secondary duodenal diverticulum occurs.

- Gastric ulcer appears as a niche in the lesser curvature due to ulcer crater and as a notch on the greater curvature due to the spasm of stomach.

- In general benign ulcers are smoother, more regular, with rounded edges and a flat, smooth ulcer base. In malignancy, the mass protrudes into the lumen or has folds surrounding ulcer crater.

- To detect hour glass stomach and gastric outlet obstruction. showing niche and notch

3. Test for *Helicobacter pylori*.

**OE SOPHAGOGASTRODUODENOSCOPY(OGD)**

**Diagnostic (Figs 23.14 to 23.20)**

- Peptic ulcers—acute and chronic
- Gastritis
- Carcinoma stomach
- Oesophageal varices, ulcers, oesophagitis
- Biopsy to rule out *H. pylori* infection
- Brush cytology and biology, yield is better

**Therapeutic**

- Injection of adrenaline into the bleeding vessel
- Variceal injection
- Snaring of polyps
- Electrocoagulation of bleeders
- Endoscopic cystogastrostomy
- Foreign body removal
- Percutaneous endoscopic gastrostomy (PEG)
- Endoscopic mucosal resection for early carcinoma stomach

Treatment of chronic duodenal ulcer (CDU)

Aim is to decrease the pain because of its severity (by reducing acidity) and to prevent relapses.

**AIMS OF THE TREATMENT**

- To relieve symptoms
- To heal the ulcer
- To prevent recurrence
- To prevent complications

I. Medical line of management

1. Histamine receptor blockers (H<sub>2</sub> receptor blockers)

- Ranitidine: 150 mg twice a day, or 6 weeks. 90-95% of the healing occurs within 6 weeks. At the end of 6 weeks, 150 mg at bed time is given or a period of 3 months as maintenance therapy. Re-endoscopy can be done in between to assess the healing of the ulcer.

- Famotidine: 20 mg twice a day is as effective as ranitidine.

- Roxatidine: Can be used along with food, bronchodilators and antacids, unlike the other H<sub>2</sub> blockers. The dosage is 75 mg twice a day.

- The problem with H<sub>2</sub> blockers is that relapse occurs if they are stopped. 80-90% healing rates occur after 6 weeks of therapy.

2. Hydrogen ion antagonists (proton pump inhibitor)

- Omeprazole: 20 mg once a day for 2 weeks.

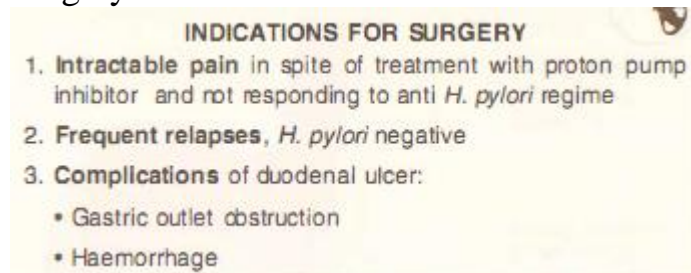
- 95-99% of healing within 2-4 weeks. More rapid healing than H<sub>2</sub> receptor blockers.



- Patients who receive omeprazole for one month are put on a maintenance dose of ranitidine for 3 months (150 mg HS for 3 months).
  - Other drugs such as esomeprazole: 40 mg/day, lansoprazole: 30 mg/day, pantoprazole: 40 mg/day are also used.
  - Pantoprazole in a dose of 40 mg/day for 4 weeks has become the first line of treatment for chronic duodenal ulcer.
3. Regular antacid calcium or magnesium based
    - Given in high doses (120 ml/day) they will neutralise the acid (not practical). Small dose of antacids can be added to H<sub>2</sub> blockers. This gives psychological benefit to the patient.
  4. Diet should be bland. Spicy food, coffee, alcohol, and smoking are discouraged. Discontinue aspirin or NSAIDs and other gastric irritants.
  5. Eradication therapy.

## II. Surgical line of management

### Surgery



1. Highly selective vagotomy (HSV): It is also called PCV (parietal cell vagotomy) or PGV (proximal gastric vagotomy). (Fig. 3)
  - In this operation, vagi are not divided at the trunks. Both anterior and posterior vagus are identified, isolated and preserved. Their branches which run along the lesser curvature are isolated. They are anterior and posterior greater gastric nerves of Latarjet. The branches of the nerves of Latarjet supplying parietal cell mass are divided. Hence, it is called parietal cell vagotomy. The terminal fibres of the nerve of Latarjet which supply pylorus are preserved (5-7 cm of 'Crow foot').

#### Advantages of HSV

1. More physiological, with minimal disturbances.
2. No drainage procedure is required because pyloric functions are preserved.
3. Nerve supply to gallbladder and liver is not disturbed.
4. No diarrhoea as that can occur in 5-8% of cases of truncal vagotomy which can be morbid.

#### Disadvantages of HSV

- This is not the procedure for prepyloric ulcer as there is a high recurrence rate.
- Complicated procedure-needs an experienced surgeon.
- Recurrence rate: 10-15%
- Rare chance of lesser curvature necrosis.

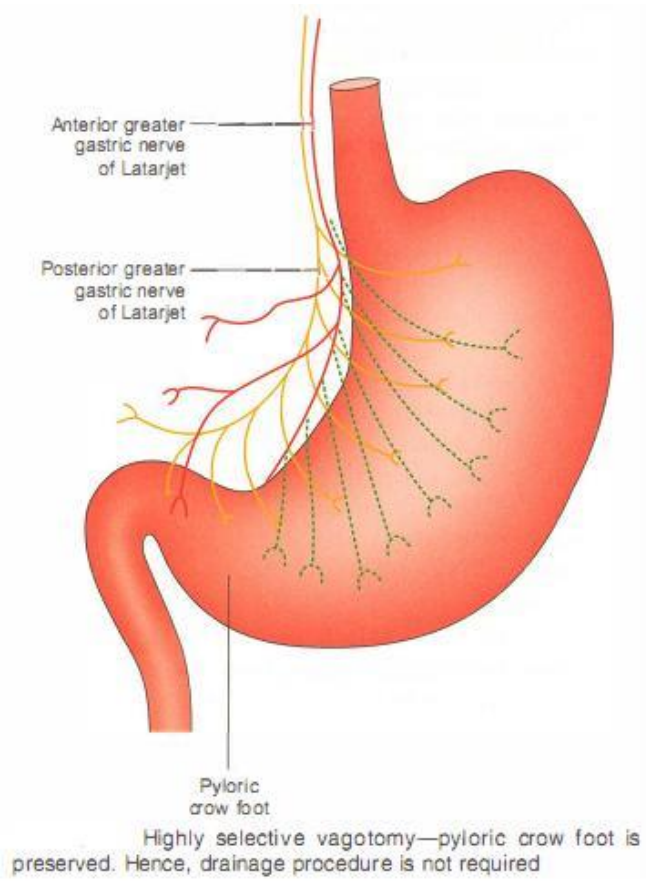
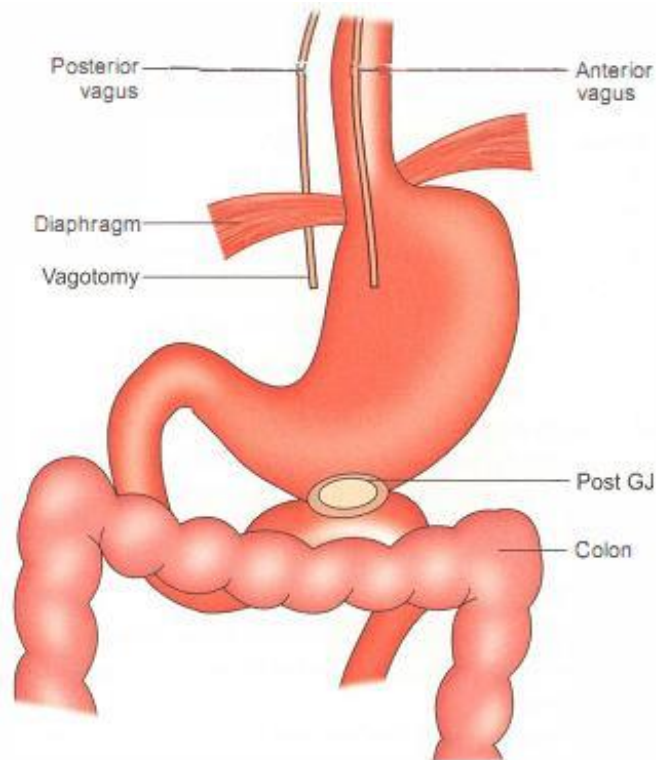


Fig. 3

2. Total truncal abdominal vagotomy with gastro-jejunostomy of Mayo (Fig. 4) or pyloroplasty



Posterior GJ (Mayo)<sup>1</sup> with vagotomy—motility of the stomach is lost after vagotomy. Hence, drainage procedure (GJ in this picture) is required (vagus is secretomotor of the stomach)

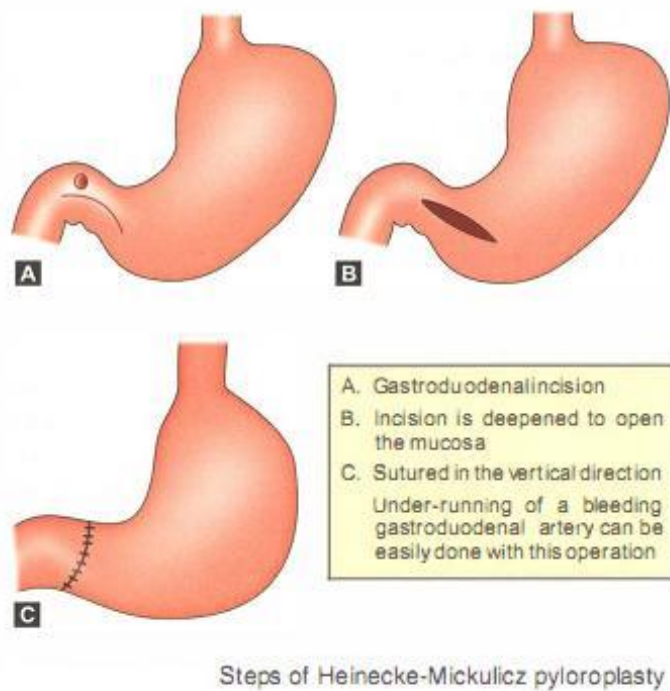
Fig. 4

- This is the most popular and most commonly done operation for peptic ulcer disease. However, it is important to realise that indications for vagotomy and GJ are becoming less and less today.
- Transection of both vagal trunks at oesophageal hiatus denervates acid producing fundus of stomach. It also denervates the remainder of the viscera supplied by vagus including liver, biliary tree, pancreas, intestines up to mid-transverse colon.

#### Procedure

- Anterior and posterior trunks of the vagus are divided just below the diaphragm followed by a drainage procedure such as gastrojejunostomy (GJ). Vagus is secretomotor to stomach and after vagotomy the motility of the stomach is lost and gastric stasis occurs. Hence, drainage procedure is done.
- Posterior GJ is preferred because it gives a dependent drainage of the food contents by gravity. Classically, it is described as "Posterior, Vertical, Retrocolic, Isoperistaltic, No loop (short loop), No tension, GJ of Mayo (PVRING)".
- Alternatively, pyloroplasty is preferred by a few surgeons instead of GJ.
- In Heinecke-Mickulicz pyloroplasty, pylorus is incised longitudinally and sutured vertically. Thus, the pyloric ring becomes incompetent and wide open. Bile reflux gastritis and diarrhoea are major problems after pyloroplasty

(Fig. 5).



(Fig. 5)

- Finney pyloroplasty is another procedure wherein inverted U-type of incision is given involving distal stomach and duodenum and a gastroduodenal stoma is created. This type of pyloroplasty is indicated when duodenum is dilated (Fig. 6).

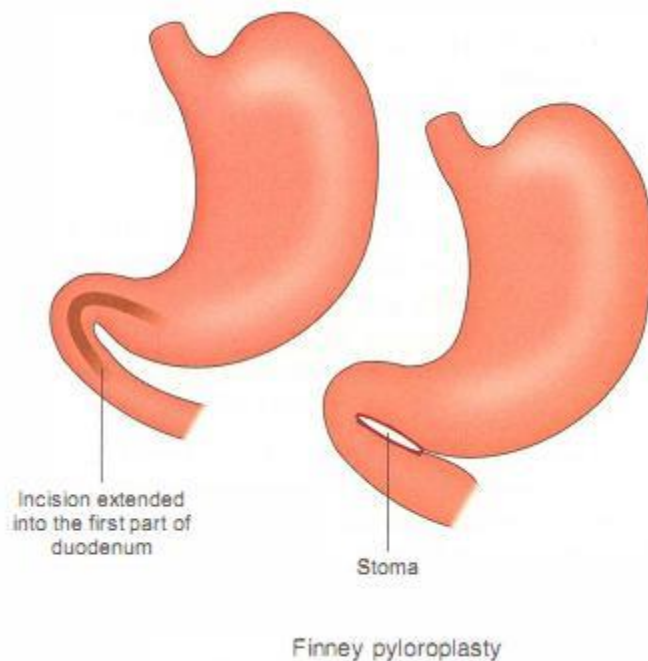


Fig. 6

### 3. Vagotomy and antrectomy (Fig. 7)

- By removing the vagal stimuli and the antral gastrin, the entire stimulus to acid secretion is lost. Hence, it carries the least recurrence rate (1 %) but carries 3-4% mortality rate. Not done routinely.

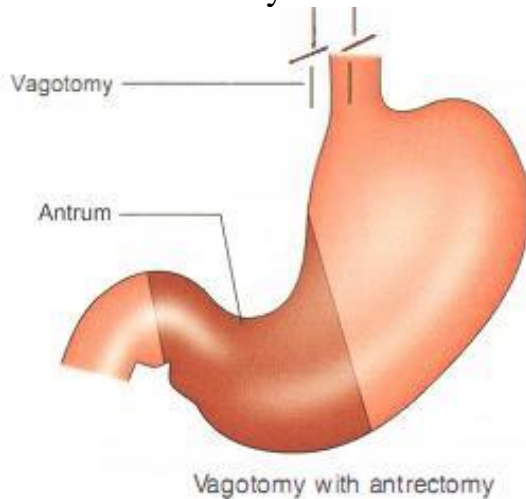


Fig. 7

### Treatment of gastric ulcer

- Aim: Healing of the ulcer and relief of symptoms.
- Frequent biopsy is done to rule out malignancy.

I. Medical line of treatment can be given or duodenal ulcer, in the form of ranitidine or omeprazole. Cigarette smoking should be stopped. Drugs such as NSAID and aspirin are to be avoided. If an ulcer persists after 6 weeks, the aim is to eradicate . pylori provided malignancy is ruled out.

II. Surgery is indicated in case of gastric ulcer persisting in spite of medical treatment.

#### 1. Billroth I partial gastrectomy (Fig. 8)

- Partial gastrectomy is done including removal of the ulcer followed by gastroduodenal anastomosis. It has the least recurrence rate of less than 1 % but mortality rate is around 1-2%.

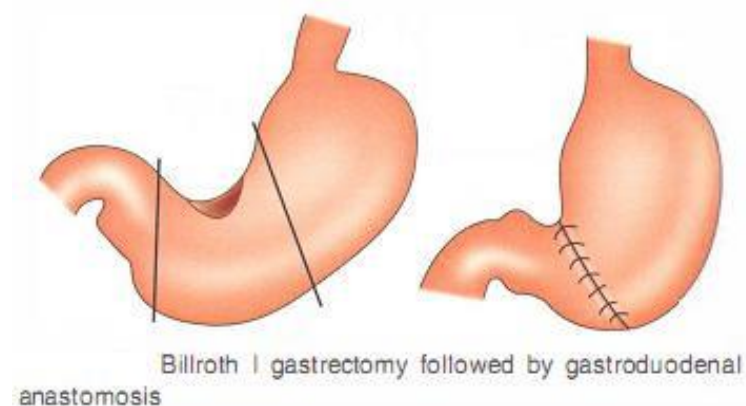


Fig. 8

#### 2. Billroth II gastrectomy (Fig. 9)



- It is indicated when the gastric ulcer is located on the lesser curvature. Here the gastrectomy is done below the ulcer and remnant of the stomach is anastomosed to a jejunal loop (gastrojejunal anastomosis). This is also described as Polya gastrectomy.

3. HSV with excision of the ulcer can be done if the experience of surgeon is good.

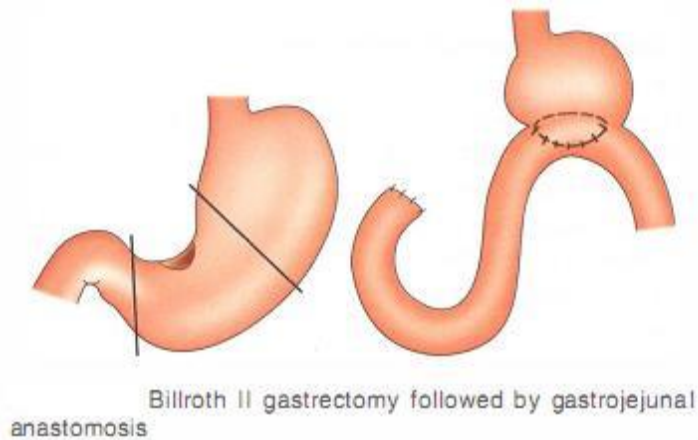
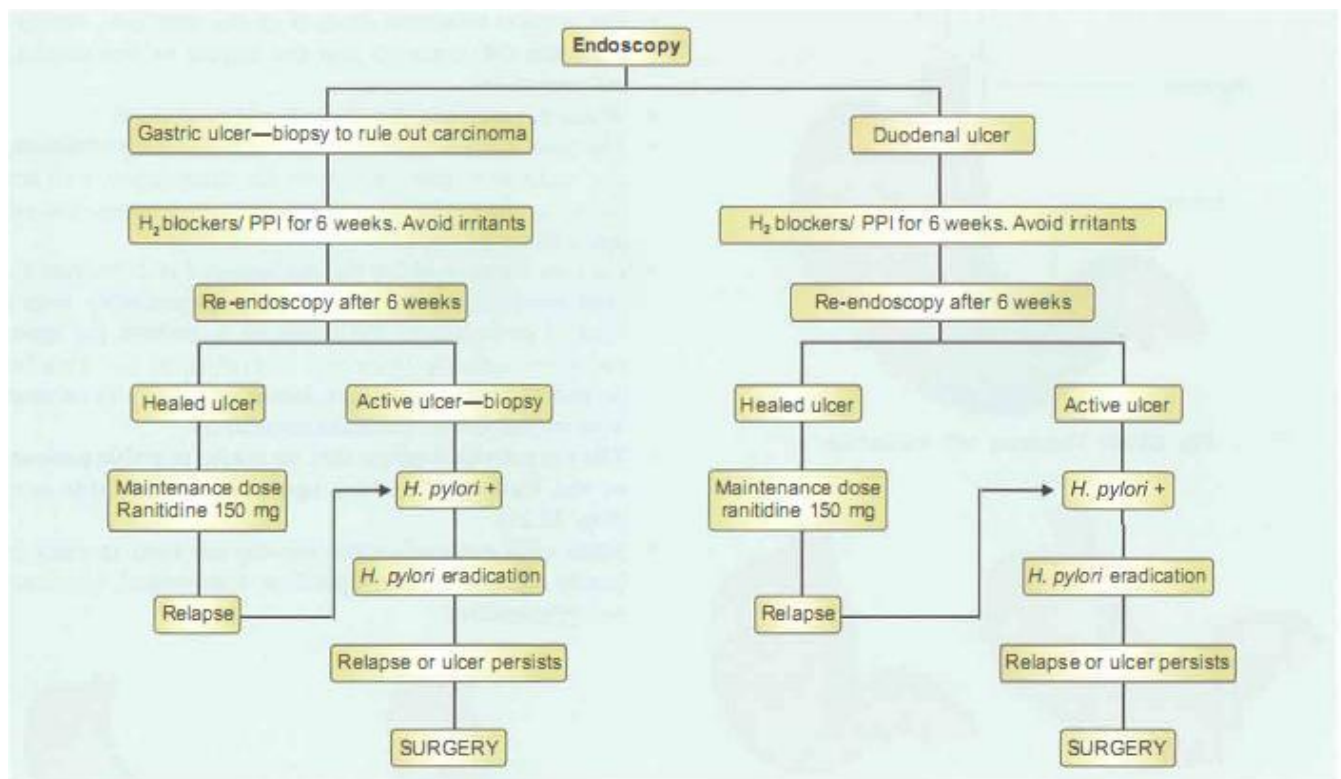


Fig. 9

## Summary of the management of peptic ulcer



Management of peptic ulcer

## Complications of peptic ulcer

#### A. Acute

- Perforation
- Haematemesis and/or melaena

#### B. Subacute-residual abscess

#### C. Chronic

- Gastric outlet obstruction (pyloric stenosis)
- Teapot deformity
- Hour glass contracture of the stomach
- Penetration into the pancreas
- Carcinoma of stomach

### ACUTE COMPLICATIONS OF PEPTIC ULCER-PERFORATED PEPTIC ULCER

#### Introduction

- More common in males.
- Anterior duodenal ulcer perforates and posterior duodenal ulcer bleeds. An ulcer on the posterior wall of the stomach can perforate into the lesser sac.
- Usually, patients with a long history of peptic ulcer, suddenly complain of feeling something that has given way in their abdomen. It may be precipitated by excessive smoking alcohol, drugs, etc. Rarely a 'silent' ulcer can also perforate (especially those patients treated with cortisone).
- Patients taking NSAIDs (often elderly) can present less dramatically.
- Two factors are associated with most perforated peptic ulcers: Chronic use of NSAIDs and Helicobacter pylori infection.
- Patients with H. pylori infection and perforated peptic ulcers tend to be younger, with a male preponderance and more prolonged period of dyspepsia. However, NSAIDs category of patients are elderly with equal proportion of both sexes being affected.
- Perforated peptic ulcers have a mortality rate of 5-10%.
- Perforated gastric ulcers in the elderly have 20-30% mortality rate.
- Golden time to operate is within 6 hours.

#### Stages of duodenal ulcer perforation

##### 1. Stage of chemical peritonitis

- Immediately after the perforation, gastric and duodenal contents leak into the peritoneal cavity and produce severe agonising pain in the right hypochondrium. It is mainly HCl which produces pain.
- There may be an episode of coffee-ground vomitus, followed by melaena later.
- The pulse rate increases. The patient is pale and anxious.
- Blood pressure may be normal in the initial few hours.
- Per abdomen, there is guarding and rigidity of the abdominal wall.



- Rebound tenderness is present all over the abdomen. This sign is called Blumberg's sign.
- On percussion, liver dullness is obliterated because of collection of free air (gas) under the right dome of diaphragm. This stage is seen for about 2-4 hours from the time of perforation.
- Bowel sounds are usually absent.

## 2. Stages of reaction

- The peritoneum reacts to the chemical irritants by secreting peritoneal fluid. As a result of this, HCl and bile are diluted by the peritoneal secretions (reaction of peritoneum to the insult) resulting in an improvement of symptoms.

Hence,

it is also called stage of delusion or stage of illusion. This stage lasts for 3-6 hours. However, the signs are worse.

- Pulse is feeble, more than 120/min.
- Hypotension persists
- Evidence of dehydration due to loss of fluid into peritoneal cavity.
- Shifting dullness is present
- Abdominal distension is due to fluid and paralytic ileus
- Bowel sounds are absent
- Guarding and rigidity are worsened.

## 3. Stage of bacterial peritonitis

- The peritoneal contents get contaminated with gram-negative organisms resulting in bacterial peritonitis (the organisms are from the intestine itself and not from the peritoneum).
- The patient becomes severely ill, dehydrated, toxic with drawn in cheeks. The tongue is dry and coated but with bright eyes (Hippocratic facies).
- Features of hypovolaemic and septic shock such as feeble thready pulse, cold peripheries, shallow respiration, high grade fever and persistent hypotension are present. Gross abdominal distension, guarding, rigidity, abdominal tenderness all over suggest generalised peritonitis.

## TREATMENT (ABCDEF)

- Aspiration of stomach contents with Ryle's tube to reduce further contamination and to decrease biliary and pancreatic JUICE.
- Blood grouping and cross-matching may be necessary for surgery.
- Charts: Temperature, pulse, BP, respiration, urinary output (urinary bladder is catheterised using a Foley's catheter).
- Drugs:
  - Injection ampicillin 500 mg IV, stat and 6th hourly against gram-positive organisms.

- Injection gentamicin 60-80 mg IV, 8th hourly against gram-negative organisms.
  - Injection metronidazole 500 mg IV, 8th hourly to treat anaerobic organisms.
  - Cephalosporins can also be used depending upon the severity of the shock.
- E. Exploratory laparotomy is done through a midline incision. The perforation is identified and closed with interrupted nonabsorbable silk sutures, which is strengthened by placement of omentum (Fig. 10). Peritoneal toilet/wash is given to avoid residual abscess. Abdomen is closed with a drain which is removed after 3-5 days. If it is a large gastric ulcer, it is better to do a gastrectomy, if condition of the patient permits.

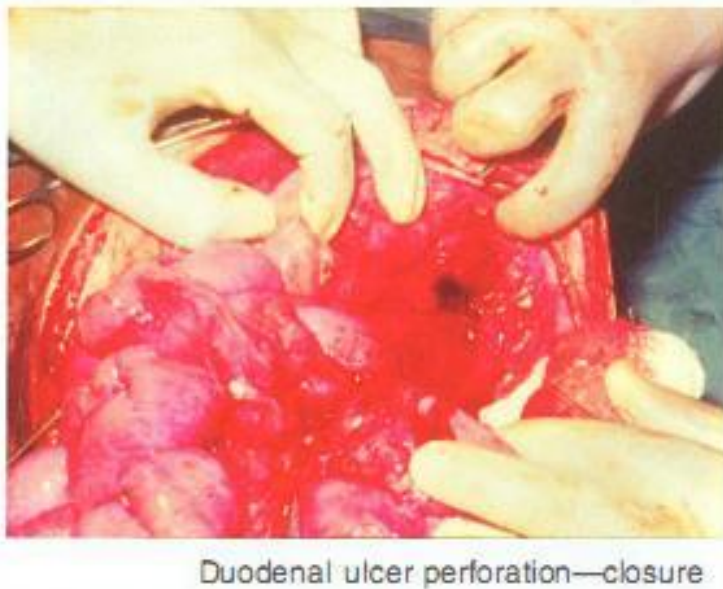


Fig. 10

- Vagotomy and GJ is not done at this stage as the general condition of the patient is very poor and there is peritoneal sepsis.
- Postoperatively, the patient is put on anti-ulcer drugs.
- An endoscopy is done after 2 months. If the ulcer persists, it is likely to be a chronic ulcer and an elective operation such as vagotomy and GJ is done.

Simple suturing cures majority of acute ulcers.

F. Fluids are given preoperatively to treat dehydration and postoperatively for 34 days till the paralytic ileus settles down (soft abdomen and bowel sounds present).

Early cases of perforation

It can also be managed by laparoscopic closure of perforation with peritoneal drainage. In fact, a thorough wash is really possible with a laparoscope.

Subacute

Perforation with abscess. Some patients present late to the hospital with features of sealed perforation.

1. Regarding duodenum following are true except:
  - A. Lined by mucus-secreting columnar epithelium

- B. Brunner's glands are present
  - C. Duodenum can produce cholecystokinin
  - D. Duodenum will not secrete secreting
2. Following are true regarding blood supply of the stomach except:
- A. The fundus is supplied by left gastric artery
  - B. Left gastric artery is a branch of coeliac axis
  - C. Right gastroepiploic artery runs along greater curvature of the stomach
  - D. Gastroduodenal artery is a branch of hepatic artery.
3. Duodenal ulcer commonly occurs in which part of duodenum?
- A. First part
  - B. Second part
  - C. Third part
  - D. Fourth part
4. Following are true for *Helicobacter pylori* bacteria except:
- A. It is spiral shaped
  - B. It hydrolyses urea
  - C. It can produce cytotoxins
  - D. Mostly, it is associated with type A gastritis
5. Following are true for duodenal ulcer except:
- A. It occurs in the first part of the duodenum
  - B. It may be associated with type B gastritis
  - C. Smoking may precipitate development of ulcer
  - D. It can erode branches of left gastric artery and result in massive bleeding
6. Following are true or malignancy in a gastric ulcer except:
- A. It occurs rarely
  - B. Occurs in the lesser curvature of the stomach
  - C. It produces a notch in barium studies
  - D. Converging rugosity is lost
7. About truncal vagotomy which one of the following is not correct?
- A. Decreases acid secretion
  - B. Decreases parasympathetic activity
  - C. Increases gall stones
  - D. Increases constipation
8. More accurate investigation for the diagnosis of the perforated duodenal ulcer is:
- A. Ultrasound of the abdomen
  - B. Plain X-ray abdomen erect position
  - C. Plain X-ray chest
  - D. CT imaging
9. Treatment of the perforated duodenal ulcer include following except:
- A. Suturing the ulcer in transverse direction
  - B. Truncal vagotomy
  - C. Peritoneal toilet
  - D. Omental patch
10. The most common site of bleeding from peptic ulcer is:
- A. Lesser curvature of the stomach
  - B. Greater curvature of the stomach
  - C. First part of the duodenum
  - D. Fundus of the stomach

ANSWERS: 1-D 2-A 3-A 4-D 5-D 6-C 7-D 8-D 9-B 10-C

Literature:

1. K Rajgopal Shenoy, Anitha Shenoy. Manipal Manual of Surgery. CBS Publishers & Distributors. Forth Edition. 460-478.
2. Harold Ellis, Sir Roy Calne, Christopher Watson. General Surgery Lecture Notes. Wiley BlackWell. 2016. 166-183

3. Bell G D, Powell K U. Eradication of *Helicobacter pylori* and its effect in peptic ulcer disease. *Scand J Gastroenterol.*(1993);28(suppl):7–11.
4. Donovan A J, Berne T V, Donovan J A. Perforated duodenal ulcer. An alternative therapeutic plan. *Arch Surg.*(1998);133:1166–1171
5. Forbes G M, Glaisher M E, Cullen D J E, Warren J R, Christiansen K J, Marshall B J, Collins B J. Duodenal ulcer treated with *Helicobacter* eradication: seven year follow-up. *Lancet.* (1994);334:258–260.
6. Lau W Y, Leung K L, Kwong K H, Davey I C, Robertson C, Dawson J J, Chung S C, Li A K. A randomized study comparing laparoscopic versus open repair of perforated peptic ulcer using suture or sutureless technique. *Ann Surg.*(1996);224:131–138.
7. Ng E K, Chung S C, Sung J J, Lam Y H, Lee D W, Lau J Y, Ling T K, Lau W Y, Li A K. High prevalence of *Helicobacter* infection in duodenal ulcer perforations not caused by non-steroidal anti-inflammatory drugs. *Br J Surg.*(1996);83:1779–1781.
8. Sebastian M, Chandran V P, Elashaal Y I, Sim A J. *Helicobacter pylori* infection in perforated duodenal ulcer disease.*Br J Surg.* (1995);82:360–362.
9. Holzheimer RG, Mannick JA, editors. Munich: Zuckschwerdt; 2001. *Surgical Treatment: Evidence-Based and Problem-Oriented.*
10. Walsh J H, Peterson W L. The treatment of *helicobacter* infection in the management of peptic ulcer disease. *N Engl J Med.* (1995);333:984–991.

All the illustrated materials are taken from « Manipal Manual of Surgery. CBS Publishers & Distributors. Forth Edition. Edited by K Rajgopal Shenoy, Anitha Shenoy»