

Federal State Budgetary Educational Institution of Higher Education "North Ossetian State Medical Academy" of the Ministry of Health of the Russian Federation

Department of Radiation Diagnostics with Radiation Therapy and Oncology

APPROVED
minutes of the meeting
Central coordination
educational and methodological council
"23" May 2023 No. 5

ASSESSMENT MATERIALS

on _____ **Radiation diagnostics** _____

(name of discipline (module)/educational/industrial practice, research work - select what is required)

main professional educational program of higher education - specialty program in specialty

05/31/01 General Medicine,

approved on May 24, 2023

for 3rd year students _____

(students/residents/postgraduates/listeners – select what is required) (course/year of study)

specialty 05/31/01 General Medicine

(code/name)

Reviewed and approved at a department meeting

From 21.05. 2023 (protocol No. 7)

Head of the Department Doctor of Medic

Khasigov A.V.



STRUCTURE OF ASSESSMENT MATERIALS

1. Title page
2. Structure of assessment materials
3. Reviews of evaluation materials
4. Passport of evaluation materials
5. Set of assessment materials:
 - questions for the module
 - questions for testing
 - questions for the exam
 - bank of situational tasks/practical tasks/business games
 - standards of test tasks (with title page and table of contents)
 - exam papers/test tickets

FEDERAL STATE BUDGETARY EDUCATIONAL INSTITUTION OF HIGHER
EDUCATION " NORTH OSSETIAN STATE MEDICAL ACADEMY" OF THE MINISTRY
OF HEALTH OF THE RUSSIAN FEDERATION

REVIEW
for assessment materials

in the discipline _ _____ Radiation diagnostics

for _____ 3rd year students

specialty 05/31/01 General Medicine

Evaluation materials were compiled at the Department of Radiation Diagnostics with Radiation Therapy and Oncology

based on the work program of the discipline Radiation diagnostics approved minutes of the meeting Central Coordination Educational and Methodological Council "23" May 2023 No. 5

and meet the requirements of the Federal State Educational Standard for Higher Education in the specialty 31.05.01 General Medicine, approved by the Ministry of Education and Science of the Russian Federation on 02/09/2016. No. 95

Evaluation materials include:

- questions for the module,
- questions for testing,
- questions for the exam,
- bank of situational tasks/practical tasks/business games,
- standards of test tasks (with title page and table of contents),
- exam tickets/test tickets

The bank of situational tasks/practical tasks/business games includes the tasks themselves and answer templates. All tasks correspond to the work program of the discipline "radiation diagnostics", the competencies formed during its study, and cover all its sections.

The bank contains answers to all situational tasks/practical tasks/business games .

Test task standards include the following elements: test tasks, answer templates.

All tasks correspond to the work program of the discipline "radiation diagnostics", the competencies formed during its study, and cover all its sections. The difficulty of the tasks varies. The number of tasks for each section of the discipline is sufficient for testing knowledge and eliminates repeated repetition of the same question in different versions. The standards contain answers to all test tasks.

The number of exam tickets is sufficient to conduct the exam and eliminates the repeated use of the same ticket during the exam within one day. Examination tickets/test tickets are made on uniform forms according to a standard form, on paper of the same color and quality. The examination ticket/test ticket includes _____ questions. The wording of the questions coincides with the wording of the list of questions submitted for the exam/test. The content of the questions on one ticket relates to various sections of the work program of the discipline, allowing you to more fully cover the material of the discipline.

In addition to theoretical questions, a bank of situational tasks (tests, recipes, radiographs, electrocardiograms, etc.) / practical tasks / business games is offered. Situational tasks/practical tasks/business games make it possible to objectively assess the level of student's mastery of theoretical material during ongoing monitoring of progress and intermediate certification. The complexity of questions in exam papers/test tickets is distributed evenly. comments on the peer-reviewed assessment materials.

In general, assessment materials for the discipline Radiation diagnostics

contribute to a qualitative assessment of students' level of proficiency in universal/general professional/professional competencies.

Peer-reviewed assessment materials for the discipline Radiodiagnosis

can be recommended for use for ongoing monitoring of progress and intermediate certification at the Faculty of Medicine for students of the 3rd year/year of study.

Reviewer:

Chairman of the TSUMK for natural sciences and mathematics with a subcommittee for the examination of assessment materials, Associate Professor of the Department of Chemistry and Physics

signature

Botsiev N.I.

M.P.

"23.05." 2023

**FEDERAL STATE BUDGETARY EDUCATIONAL INSTITUTION OF HIGHER
EDUCATION " NORTH OSSETIAN STATE MEDICAL ACADEMY" OF THE MINISTRY
OF HEALTH OF THE RUSSIAN FEDERATION**

**REVIEW
for assessment materials**

in the discipline _ _____ Radiation diagnostics

for _____ 3rd year students _____

)

specialty 05/31/01 General Medicine

(code/name)

Evaluation materials were compiled at the Department of Radiation Diagnostics with Radiation Therapy and Oncology

based on the work program of the discipline Radiation diagnostics approved minutes of the meeting Central coordination educational and methodological council May 23, 2023 No. 5

and meet the requirements of the Federal State Educational Standard for Higher Education in the specialty 31.05.01 General Medicine, approved by the Ministry of Education and Science of the Russian Federation on 02/09/2016. No. 95

Evaluation materials include:

- questions for the module,
- questions for testing,
- questions for the exam,
- bank of situational tasks/practical tasks/business games,
- standards of test tasks (with title page and table of contents),
- exam tickets/test tickets

The bank of situational tasks/practical tasks/business games includes the tasks themselves and answer templates. All tasks correspond to the work program of the discipline "radiation diagnostics", the competencies formed during its study, and cover all its sections.

The bank contains answers to all situational tasks/practical tasks/business games .

Test task standards include the following elements: test tasks, answer templates.

All tasks correspond to the work program of the discipline "radiation diagnostics", the competencies formed during its study, and cover all its sections. The difficulty of the tasks varies. The number of tasks for each section of the discipline is sufficient for testing knowledge and eliminates repeated repetition of the same question in different versions. The standards contain answers to all test tasks.

The number of exam tickets is sufficient to conduct the exam and eliminates the repeated use of the same ticket during the exam within one day. Examination tickets/test tickets are made on uniform forms according to a standard form, on paper of the same color and quality. The examination ticket/test ticket includes _____ questions. The wording of the questions coincides with the wording of the list of questions submitted for the exam/test. The content of the questions on one ticket relates to various sections of the work program of the discipline, allowing you to more fully cover the material of the discipline.

In addition to theoretical questions, a bank of situational tasks (tests, recipes, radiographs, electrocardiograms, etc.) / practical tasks / business games is offered. Situational tasks/practical tasks/business games make it possible to objectively assess the level of student's mastery of theoretical material during ongoing monitoring of progress and intermediate certification. The complexity of questions in exam papers/test tickets is distributed evenly.

comments on the peer-reviewed assessment materials.

In general, assessment materials for the discipline Radiation diagnostics

contribute to a qualitative assessment of students' level of proficiency in universal/general professional/professional competencies.

Peer-reviewed assessment materials for the discipline Radiodiagnosis

can be recommended for use for ongoing monitoring of progress and intermediate certification at the Faculty of Medicine for students of the 3rd year/year of study.

Reviewer:

Chief specialist - radiologist of the Ministry of Health of RSO-Alania, Head of the Department of Radiation Diagnostics, Federal State Budgetary Institution "SKMMC" of the Ministry of Health of the Russian Federation, Professor, Doctor of Medical Sciences.

signature

Georgiadi S.G.

M.P.

"23.05." 2023

Passport of assessment materials for the discipline
Radiation diagnostics

No.	Name of the supervised section	Code of the	Name of assessment
-----	--------------------------------	-------------	--------------------

	(topic) of the discipline/module	competence (stage) being formed	material
1	2	3	4
Type of control	Ongoing progress monitoring/interim assessment		
1	Introduction. General radiation issues diagnostics	OPK-9	test control, questions for the module, questions for the test, questions for the exam, bank of situational tasks/practical tasks/business games, test/exam tickets
2	Radiation diagnostics in neurology	PC-1	test control, questions for the module, questions for the test, questions for the exam, bank of situational tasks/practical tasks/business games, test/exam tickets
3	Lungs in X-ray image	PK-5	test control, questions for the module, questions for the test, questions for the exam, bank of situational tasks/practical tasks/business games, test/exam tickets
4	Radiation diagnostics of the heart and large vessels.	PC-5,6,7	test control, questions for the module, questions for the test, questions for the exam, bank of situational tasks/practical tasks/business games, test/exam tickets
5	The osteoarticular system in a radial image.	PC-5,6,7	test control, questions for the module, questions for the test, questions for the exam, bank of situational tasks/practical tasks/business games, test/exam tickets
6	Methods for radiological diagnosis of diseases of the esophagus, stomach, and intestines.	PC-5,6,7	test control, questions for the module, questions for the test, questions for the exam, bank of situational tasks/practical

			tasks/business games, test/exam tickets
7	Complex radiodiagnosis of diseases of the hepato-pancreato-biliary system.	PC-5,6,7	test control, questions for the module, questions for the test, questions for the exam, bank of situational tasks/practical tasks/business games, test/exam tickets
8	Complex radiation kidney urinary tract examination	PC-5,6,7	test control, questions for the module, questions for the test, questions for the exam, bank of situational tasks/practical tasks/business games, test/exam tickets
9	Mammography. Radiation diagnostics of genitalia organs.	PC-5,6,7,21	test control, questions for the module, questions for the test, questions for the exam, bank of situational tasks/practical tasks/business games, test/exam tickets
10	Radiation diagnostics in otorhinolaryngology, endocrine system	PC-5,6,7,21	test control, questions for the module, questions for the test, questions for the exam, bank of situational tasks/practical tasks/business games, test/exam tickets

*The name of the controlled section (topic) or topics (sections) of the discipline/module is taken from the work program of the discipline.

**Federal State Budgetary Educational Institution
higher education " North Ossetian State Medical Academy" of the Ministry of Health
of the Russian Federation**

Department of “ Radiation diagnostics and radiation therapy with oncology”
Faculty - Medical Course-3
Discipline - Radiation diagnostics.

Questions for module No. 1

1. 1. In what year were X-rays discovered, what they are, their properties.
2. Radioactivity, radioactive radiation and their characteristics.
3. The structure of the atom and the atomic nucleus.
4. Interaction of ionizing radiation with atoms of matter.
5. Atomic structure and periodic table of elements D.I. Mendeleev.
6. Natural radiation and its components.
7. Activity, units of activity.
8. Penetrating radiation dose units and dosimetry methods.
9. Artificial radioactivity, radioactive isotopes and their production. Who owns the discovery of artificial radioactivity?
10. Methods for recording radiation, design of gas-discharge and scintillation detectors.
11. Thermography or thermal imaging technique , the principle of obtaining images.
12. Ultrasound diagnostic technique, principle of image acquisition.
13. Classification of X-ray examination methods, principles of image acquisition.
14. Basic methods of x-ray examination, the principle of obtaining images.
15. Additional methods of x-ray examination, the principle of obtaining images.

16. Special methods of x-ray examination, the principle of obtaining images.
17. Computed tomography and its diagnostic capabilities, the principle of obtaining images.
18. Magnetic resonance imaging and its diagnostic capabilities, the principle of obtaining images.
19. Radionuclide diagnostics, fundamentals and capabilities, principle of image acquisition.
20. X-ray surgical methods of diagnosis and treatment.
21. Ultrasound diagnostics, its types, diagnostic capabilities, principles of image acquisition.

Questions for module No. 2

1. Indications for computed tomography examination of the brain.
2. Indications for magnetic resonance imaging of the brain.
3. Indications for computed tomographic examination of the spinal cord.
4. Indications for magnetic resonance imaging of the spinal cord.
5. X-ray manifestations of degenerative changes in the spine, causing radicular syndrome.–
6. X-ray signs of a spinal fracture.
7. Advantages of CT and MR diagnostics of acute cerebral stroke.
8. Differential MRI diagnosis of sub- and epidural hematomas.
9. Anomalies in the development of the skull.
10. Inflammatory diseases of the skull.
11. Benign and malignant tumors and tumor-like formations of the skull.

Questions for module No. 3

1. Radiation anatomy of the lungs.
2. Basic methods of x-ray examination of the lungs.
3. The main radiological syndromes of lung pathology in x-ray images.
4. Syndrome of extensive darkening of the pulmonary field.
5. Syndrome of extensive clearing of the pulmonary field.
6. Syndrome of limited darkening of the pulmonary field.
7. Syndrome of limited clearing of the pulmonary field.
8. Syndrome of a rounded shadow in the pulmonary field.
9. Ring-shaped shadow syndrome in the pulmonary field.
10. Syndrome of limited dissemination in the pulmonary fields.
11. Syndrome of widespread dissemination in the pulmonary fields.
12. Syndrome of focal shadows in the pulmonary field.
13. Radiation research techniques used to recognize bronchial pathology.
14. Bronchial obstruction syndrome.
15. X-ray diagnosis of pneumonia.
16. Classification of pneumonia.
17. X-ray diagnosis of lung abscess.
18. Classification of pleurisy. X-ray diagnosis of effusion pleurisy.
19. X-ray diagnosis of pneumothorax and atelectasis.
20. X-ray diagnosis of primary pulmonary tuberculosis complex.
21. X-ray diagnosis of tuberculous bronchoadenitis.
22. X-ray diagnosis of disseminated pulmonary tuberculosis.
23. X-ray diagnosis of focal pulmonary tuberculosis.
24. X-ray diagnostics of the infiltrative-pneumonic form of pulmonary tuberculosis.
25. X-ray diagnosis of pulmonary tuberculoma .
26. X-ray diagnosis of the cavernous form of pulmonary tuberculosis.

27. X-ray diagnostics of the fibrous-cavernous form of pulmonary tuberculosis.
28. The role of fluorography in the detection of pulmonary tuberculosis.
29. The role of tomography in identifying pulmonary tuberculosis.
30. Classification of lung tumors.
31. X-ray diagnosis of central lung cancer.
32. X-ray diagnosis of peripheral lung cancer.
33. X-ray diagnosis of pulmonary echinococcus.

Questions for module No. 4

1. Radiation anatomy of the heart. Arcs of the cardiac contour in direct and oblique projections.
2. What are the arcs of the cardiac circuit. Which parts of the heart and blood vessels form the arches in the anterior projection.
3. Which parts of the heart correspond to each arch in the first and second oblique positions.
4. What is the X-ray picture of mitral heart defects.
5. What is the X-ray picture of aortic heart defects.
6. X-ray diagnosis of myocardial lesions.
7. X-ray diagnosis of pericardial lesions.
8. Diagnostic capabilities of ultrasound in identifying pathology of the heart and great vessels.
9. What are the methods for studying the great vessels and indications for them.
10. What are the methods for studying peripheral vessels and indications for them.

Questions for module No. 5

1. Radiation anatomy of bones and joints.
2. X-ray features of the image of bones and joints in children.
3. Radiation methods for studying bones and joints.
4. Age-related features of bones and joints during radiation studies.
5. Possibilities of radionuclide diagnostics in studies of bones and joints.
6. Osteoporosis syndrome.
7. Osteosclerosis syndrome.
8. Types of fractures, x-ray diagnosis of fractures.
9. X-ray diagnosis of dislocations and subluxations.
10. Features of fractures in childhood.
11. Healing of fractures in x-ray image.
11. Radiation diagnosis of acute and subacute (chronic) hematogenous osteomyelitis.
12. Radiation diagnosis of traumatic osteomyelitis.
13. X-ray diagnosis of tuberculous spondylitis .
14. Radiation diagnostics of benign bone tumors.
15. Radiation diagnostics of malignant bone tumors.

Questions for module No. 6

1. Radiation anatomy of the esophagus.
2. Radiation techniques for studying the digestive canal, artificial contrasting of the gastrointestinal tract.
3. Radiation diagnostics of foreign bodies of the esophagus.
4. Diverticula of the esophagus, their classification and x-ray picture.
5. X-ray diagnosis of esophageal achalasia .
6. X-ray diagnosis of esophageal burns.

7. Macromorphological forms of esophageal cancer, their X-ray diagnosis.
8. X-ray semiotic signs of tumors of the gastrointestinal tract.
9. Radiation anatomy of the stomach.
10. Radiation techniques for studying the stomach.
11. What data on the morphology of the stomach can be obtained by x-ray examination.
12. X-ray diagnosis of gastritis.
13. What are the direct radiological signs of gastric and duodenal ulcers?
14. What are the indirect radiological signs of gastric ulcer.
15. X-ray diagnosis of complications of gastric and duodenal ulcers.
16. X-ray diagnosis of stomach cancer.
17. Methodology for studying the large intestine.
18. X-ray diagnosis of colon tumors.
19. X-ray diagnosis of acute intestinal obstruction.

Questions for module No. 7

1. Radiation anatomy of the liver and bile ducts.
2. Radiation methods for studying the morphology and function of the liver and biliary tract.
3. Diagnostic capabilities in the study of the liver and biliary tract.
4. Methods of artificial contrast for X-ray examination of the gallbladder (cholecystography, cholegraphy, cholangiography).
5. Diseases of the liver and biliary tract.
6. Benign tumors and malignant tumors of the liver and biliary tract.

Questions for module No. 8

1. Radiation anatomy of the kidneys and urinary tract.
2. Diagnostic capabilities of ultrasound in identifying pathology of the urinary system.
3. Methods of X-ray examination of the urinary tract.
4. Method of intravenous excretory urography.
5. Method of ascending (retrograde) pyelography.
6. Diagnostic capabilities of computed tomography in the study of excretory organs.
7. Diagnostic capabilities of magnetic resonance imaging in the study of excretory organs.
8. Benign tumors and malignant tumors of the kidneys and urinary tract.
9. Diseases of the kidneys and urinary tract.

Questions for module No. 9

1. Radiation anatomy of the uterus and ovaries.
2. Radiation research methods in obstetrics and gynecology.
3. Radiation anatomy of the mammary gland.
4. Radiation picture for breast cancer.
5. Radiation picture for mastopathy, mastitis.
6. Tuberculosis of the internal female genital organs.
7. Malformations of the uterus and vagina.
8. Benign tumors and malignant tumors of the female genital organs.

Questions for module No. 10

1. X-ray anatomy of the ear.
2. X-ray anatomy of the nose, nasopharynx and paranasal sinuses.
3. Age-related patterns of the nose, nasopharynx and paranasal sinuses.
4. Ear diseases.
5. Diseases of the nose, nasopharynx and paranasal sinuses.
6. Diseases of the eye and orbit.

7. Benign and malignant tumors of ENT organs.
8. Diseases of the thyroid and parathyroid glands .

Questions for module No. 11

1. X-ray anatomy , methods of studying the maxillofacial region.
2. Radiation diagnostics, diseases of the maxillofacial region.
3. Radiation diagnostics of benign tumors of the maxillofacial region.
4. Radiation diagnostics of malignant tumors of the maxillofacial region.

Questions for testing

1. In what year were X-rays discovered, what they are, their properties.
2. Radioactivity, radioactive radiation and their characteristics.
3. Structure of the atom and atomic nucleus.
4. Interaction of ionizing radiation with atoms of matter.
5. The structure of the atom and the periodic system of elements D.I. Mendeleev.
6. Natural radiation and its components.
7. Activity, units of activity.
8. Units of dose of penetrating radiation and dosimetry methods.
9. Artificial radioactivity, radioactive isotopes and their production. Who owns the discovery of artificial radioactivity?
10. Methods for recording radiation, design of gas-discharge and scintillation detectors.
11. Thermography or thermal imaging techniques, the principle of obtaining images.
12. Ultrasound diagnostic technique, principle of image acquisition.
13. Classification of X-ray examination methods, principle of obtaining images.
14. Basic methods of x-ray examination, the principle of obtaining images.
15. Additional methods of x-ray examination, the principle of obtaining images.
16. Special methods of x-ray examination, the principle of obtaining images.
17. Computer tomography and its diagnostic capabilities, the principle of obtaining images.
18. Magnetic resonance imaging and its diagnostic capabilities, the principle of obtaining images.
19. Radionuclide diagnostics, fundamentals and capabilities, principle of image acquisition.
20. X-ray surgical methods of diagnosis and treatment.
21. Ultrasound diagnostics, its types, diagnostic capabilities, principles of image acquisition.
22. Radiation anatomy of the lungs.
23. Basic methods of x-ray examination of the lungs.
24. Basic radiological syndromes of lung pathology in X-ray images.
25. Extensive darkening of the pulmonary field syndrome.
26. Syndrome of extensive clearing of the pulmonary field.
27. Syndrome of limited darkening of the pulmonary field.
28. Syndrome of limited clearing of the pulmonary field.
29. Syndrome of a rounded shadow in the pulmonary field.
20. Ring-shaped shadow syndrome in the pulmonary field.
21. Syndrome of limited dissemination in the pulmonary fields.
22. Syndrome of widespread dissemination in the pulmonary fields.
23. Syndrome of focal shadows in the pulmonary field.
24. Radiation research techniques used to recognize bronchial pathology.
25. Bronchial obstruction syndrome.
26. X-ray diagnosis of pneumonia.
27. Classification of pneumonia.
28. X-ray diagnosis of lung abscess.
29. Classification of pleurisy. X-ray diagnosis of effusion pleurisy.

30. X-ray diagnosis of pneumothorax and atelectasis.
31. X-ray diagnosis of primary pulmonary tuberculosis complex.
32. X-ray diagnosis of tuberculous bronchoadenitis.
33. X-ray diagnosis of disseminated pulmonary tuberculosis.
34. X-ray diagnosis of focal pulmonary tuberculosis.
35. X-ray diagnostics of the infiltrative-pneumonic form of pulmonary tuberculosis.
36. X-ray diagnosis of pulmonary tuberculoma .
37. X-ray diagnosis of the cavernous form of pulmonary tuberculosis.
38. X-ray diagnostics of the fibrous-cavernous form of pulmonary tuberculosis.
39. The role of fluorography in the detection of pulmonary tuberculosis.
40. The role of tomography in identifying pulmonary tuberculosis.
41. Classification of lung tumors.
42. X-ray diagnosis of central lung cancer.
43. X-ray diagnosis of peripheral lung cancer.
44. X-ray diagnosis of pulmonary echinococcus.
45. Radiation anatomy of the heart. Arcs of the cardiac contour in direct and oblique projections.
46. What are the arcs of the cardiac circuit. Which parts of the heart and blood vessels form the arches in the anterior projection.
47. Which parts of the heart correspond to each arch in the first and second oblique positions.
48. What is the X-ray picture of mitral heart defects.
49. What is the X-ray picture of aortic heart defects?
50. X-ray diagnosis of myocardial lesions.
51. X-ray diagnosis of pericardial lesions.
52. Diagnostic capabilities of ultrasound in identifying pathology of the heart and great vessels.
53. What are the methods for studying the great vessels and indications for them.
54. What are the methods for studying peripheral vessels and indications for them.
55. Radiation anatomy of the esophagus.
56. Radiation techniques for studying the digestive canal, artificial contrast of the gastrointestinal tract.
57. Radiation diagnostics of foreign bodies of the esophagus.
58. Diverticula of the esophagus, their classification and x-ray picture.
59. X-ray diagnosis of esophageal achalasia .
60. X-ray diagnosis of esophageal burns.
61. Macromorphological forms of esophageal cancer, their X-ray diagnosis.
62. X-ray semiotic signs of tumors of the gastrointestinal tract.
63. Radiation anatomy of the stomach.
64. Radiation techniques for studying the stomach.
65. What data on the morphology of the stomach can be obtained by x-ray examination.
66. X-ray diagnosis of gastritis.
67. What are the direct radiological signs of gastric and duodenal ulcers?
68. What are the indirect radiological signs of gastric ulcer.
69. X-ray diagnosis of complications of gastric and duodenal ulcers.
70. X-ray diagnosis of stomach cancer.
71. Methodology for studying the large intestine.
72. X-ray diagnosis of colon tumors.
73. X-ray diagnosis of acute intestinal obstruction.
74. Radiation anatomy of the kidneys and urinary tract.
75. Diagnostic capabilities of ultrasound in identifying pathology of the urinary system.

76. Methods of X-ray examination of the urinary tract.
77. Method of intravenous excretory urography.
78. Method of ascending (retrograde) pyelography.
79. Diagnostic capabilities of computed tomography in the study of excretory organs.
80. Diagnostic capabilities of a magnetic resonance imaging scanner in the study of excretory organs.
81. Radiation anatomy of the uterus and ovaries.
82. Radiation research methods in obstetrics and gynecology.
83. Radiation anatomy of the mammary gland.
84. Radiation picture for breast cancer.
85. Radiation picture for mastopathy, mastitis.
86. Radiation anatomy of the liver and bile ducts.
87. Radiation methods for studying the morphology and function of the liver and biliary tract.
88. Diagnostic capabilities in the study of the liver and biliary tract.
89. Methods of artificial contrast for X-ray examination of the gallbladder (cholecystography, cholegraphy, cholangiography).
90. Radiation anatomy of bones and joints.
91. X-ray features of the image of bones and joints in children.
92. Radiation methods for studying bones and joints.
93. Age-related features of bones and joints during radiation studies.
94. Possibilities of radionuclide diagnostics in studies of bones and joints.
95. Osteoporosis syndrome.
96. Osteosclerosis syndrome.
97. Types of fractures, x-ray diagnosis of fractures.
98. X-ray diagnosis of dislocations and subluxations.
99. Features of fractures in childhood.
100. Healing of fractures in x-ray image.
101. Radiation diagnostics of acute and subacute (chronic) hematogenous osteomyelitis.
102. Radiation diagnostics of traumatic osteomyelitis.
103. X-ray diagnosis of tuberculous spondylitis.
- 104.0 Radiation diagnostics of benign bone tumors.
105. Radiation diagnostics of malignant bone tumors.

**Federal State Budgetary Educational Institution
higher education "North Ossetian State Medical Academy" of the Ministry of Health
of the Russian Federation**

Department of Radiation Diagnostics with Radiation Therapy and Oncology
Faculty/ Specialty General Medicine Course **/Year of Study** 3
Discipline Radiation diagnostics

Situational task No. 1

Woman, 35 years old.

Complaints of aching back pain, weakness, low-grade fever. History: the described complaints will subside within three months.

He has been observed at the tuberculosis dispensary for five years for intestinal tuberculosis. Objectively. On examination, there is a "button-like" protrusion of the spinous process of one of the lower thoracic vertebrae, pain on palpation of the lower thoracic vertebrae.

On radiographs of the spine in a direct projection - paravertebral shadows along Th 9-12, the intervertebral space Th 10-11 is narrowed, in a lateral projection - anterior wedge-shaped

deformity Th 10-11, narrowed intervertebral space Th 10-11, on the median lateral tomogram Th 8-12 – subchondral central lytic destruction of adjacent surfaces Th 10-11 is additionally revealed. Examination of the lungs and blood tests showed no pathology.

Your conclusion:

Metastases to the vertebrae.

Osteochondrosis of the spine.

Neurogenic tumor.

Tuberculous spondylitis.

**Federal State Budgetary Educational Institution
higher education "North Ossetian State Medical Academy" of the Ministry of Health
of the Russian Federation**

Department of Radiation Diagnostics with Radiation Therapy and Oncology

Faculty/ Specialty General Medicine Course

/Year of Study 3

Discipline Radiation diagnostics

Situational task No. 2

Male, 46 years old.

Complaints of severe pain and swelling in the right leg. Anamnesis. 2 weeks after suffering from a sore throat, the temperature increased again to 39 degrees, pain appeared in the right knee joint, and then swelling of the right leg. He took painkillers and antipyretics for three weeks. During the treatment there are short-term improvements. Objectively. The right leg is swollen, the skin is shiny, reddened, hot to the touch, painful on palpation. The right inguinal lymph nodes are enlarged to 1.5 cm. Blood tests show leukocytosis, band shift, accelerated ESR.

On radiographs of the right leg in frontal and lateral projections, along the middle third of the diaphysis of the right tibia there is lacy periostitis along the anterior semi-cylinder, the cortical layer is of reduced density, the medullary canal is slightly expanded. The volume of the soft tissues of the lower leg is increased, the contours of the muscles are not visible.

Your conclusion.

Osteoid - osteoma of the right tibia.

Tuberculosis.

Acute hematogenous osteomyelitis.

Ewing's sarcoma .

**Federal State Budgetary Educational Institution
higher education "North Ossetian State Medical Academy" of the Ministry of Health
of the Russian Federation**

Department of Radiation Diagnostics with Radiation Therapy and Oncology

Faculty/ Specialty General Medicine Course

/Year of Study 3

Discipline Radiation diagnostics

Situational task No. 3

Boy, 3 years old.

Complaints of a “bump” in the left parietal region of the head, a fistula with scanty discharge. Anamnesis. The mother noticed a swelling on the head while bathing the child two months ago. I contacted a surgeon who diagnosed a bruise, but the child was not treated. After 2 months, a fistula opened in the area of swelling. The child's mother and his older brother have been observed at the tuberculosis clinic for five years for pulmonary tuberculosis.

Objectively. After removing the bandage, there was a swelling in the left parietal region, of elastic consistency, with a fistula in the center.

On radiographs of the skull in two projections - in the left parietal bone there is a lytic destruction of irregular shape 3x5 cm with unclear uneven contours, with a sequester in the center in the form of “melting sugar”.

Your conclusion.

Histiocytosis -X in the left parietal bone

Tuberculosis

Epidermoid cyst.

Ewing's sarcoma .

**Federal State Budgetary Educational Institution
higher education "North Ossetian State Medical Academy" of the Ministry of Health
of the Russian Federation**

Department of Radiation Diagnostics with Radiation Therapy and Oncology

Faculty/ Specialty General Medicine Course

/Year of Study 3

Discipline Radiation diagnostics

Situational task No. 4

Woman, 41 years old.

Complaints of intermittent aching pain in the left shoulder joint. Anamnesis. The pain continues for two months and does not increase.

Objectively. Movement in the shoulder joints is not limited. There are no deformations.

Soft tissues are not changed.

On radiographs of the left shoulder joint in two projections in the proximal epimetaphysis of the humerus, there is a rounded lytic destruction with clear contours up to 3 cm in diameter with small calcifications .

Your conclusion:

Brodie's abscess (chronic osteomyelitis).

Codman's tumor (chondroblastoma).

Arthrosis of the shoulder joint. Tuberculosis.

**Federal State Budgetary Educational Institution
higher education "North Ossetian State Medical Academy" of the Ministry of Health
of the Russian Federation**

Department of Radiation Diagnostics with Radiation Therapy and Oncology

Faculty/ Specialty General Medicine Course

/Year of Study 3

Discipline Radiation diagnostics

Situational task No. 5

Boy, 11 years old.

Complaints of pain in the right half of the chest, swelling above the right collarbone, periodic increases in temperature up to 38 degrees. Anamnesis. After suffering from a sore throat, pain appeared in the chest, and 2 weeks later a swelling appeared above the

collarbone. The blood test shows inflammatory changes.

Objectively. Swelling without clear boundaries above the right collarbone, painful on palpation.

X-rays of the chest in two projections show a large homogeneous rounded node occupying the upper third of the right hemithorax, the pulmonary pattern is enhanced under the node. On a "hard" radiograph of the chest in a direct projection, there is fine-focal mixed destruction in the first right rib along its entire length with a linear periosteal reaction along the upper contour of the rib.

Your conclusion:

Ewing's sarcoma of the first right rib.

Acute hematogenous osteomyelitis.

Tumor of the mediastinum.

Tuberculoma.

**Federal State Budgetary Educational Institution
higher education "North Ossetian State Medical Academy" of the Ministry of Health
of the Russian Federation**

Department of Radiation Diagnostics with Radiation Therapy and Oncology

Faculty/ Specialty General Medicine Course

/Year of Study 3

Discipline Radiation diagnostics

Situational task No. 6

Woman, 37 years old.

Complaints of a tumor in the right leg. Anamnesis. For three years, I felt a tumor in my right shin, which was slowly growing. Objectively. In the upper third of the right tibia, a tumor is palpable along the inner surface; it is motionless, dense, painless, measuring 3x5 cm.

X-rays of the right leg in two projections: in the upper third of the diaphysis of the tibia, near the inner surface, there is an irregularly shaped node 2x4 cm with uneven, clear, partially calcified contours, containing a mass of calcifications and ossifications and connecting to the cortical layer with a bone pedicle.

Your conclusion:

Chondrosarcoma of the right tibia.

Osteochondral exstosis (osteochondroma).

ossificans .

Parosteal osteosarcoma.

**Federal State Budgetary Educational Institution
higher education "North Ossetian State Medical Academy" of the Ministry of Health
of the Russian Federation**

Department of Radiation Diagnostics with Radiation Therapy and Oncology

Faculty/ Specialty General Medicine Course

/Year of Study 3

Discipline Radiation diagnostics

Situational task No. 7

Male, 70 years old.

Complaints of increasing bone pain. Anamnesis. Two months ago, pain appeared in the lumbar spine, followed by pain in the hip joints, back, ribs, and shoulder joints. Weakness appeared. Objectively. Right-sided scoliosis in the thoracic spine. Pain on palpation in the spinous processes of the vertebrae. Blood tests show anemia.

X-rays of the spine, pelvis, and humerus show multiple round, dense lesions up to 1 cm in diameter with clear contours. Dystrophic changes in the joints and spine. Systemic osteoporosis. Right-sided scoliosis in the thoracic spine.

Your conclusion:

Prostate cancer metastases.

Multiple myeloma.

Paget's disease (osteodystrophy).

Multiple osteomas.

**Federal State Budgetary Educational Institution
higher education "North Ossetian State Medical Academy" of the Ministry of Health
of the Russian Federation**

Department of Radiation Diagnostics with Radiation Therapy and Oncology

Faculty/ Specialty General Medicine Course

/Year of Study 3

Discipline Radiation diagnostics

Situational task No. 8

Woman, 52 years old.

Complaints of intermittent bone pain, increasing weakness, loss of appetite, weight loss. Anamnesis. The pain has been bothering me for the last three months, weakness has been increasing in the last month, my appetite has worsened, I have lost weight... Objectively . Full range of joint movements. There is no pain on palpation. The configuration of the bones is not disturbed. The blood test shows anemia, high ESR - up to 65 mm/hour.

X-rays of the ribs, pelvis, skull, spine, long tubular bones show multiple round lytic destructions with clear contours in all bones, anterior wedge-shaped deformities of the lower thoracic vertebrae.

Your conclusion:

Metastases from an undetected primary site.

Multiple myeloma.

Fibrous dysplasia.

Recklinghausen's disease (hyperparathyroid osteodystrophy).

**Federal State Budgetary Educational Institution
higher education "North Ossetian State Medical Academy" of the Ministry of Health
of the Russian Federation**

Department of Radiation Diagnostics with Radiation Therapy and Oncology

Faculty/ Specialty General Medicine Course

/Year of Study 3

Discipline Radiation diagnostics

Situational task No. 9

Boy, 11 years old.

Complaints of severe pain and swelling in the right knee joint. Anamnesis. After an injury three weeks ago, pain appeared in the right knee joint. He went to a surgeon and was treated for the injury with alcohol compresses. The pain increased, he wakes up at night from pain and takes analgesics. A week ago, a swelling of the knee joint appeared and is increasing.

Objectively. The right leg is bent at the knee joint, movements are limited and painful. The tumor on the inner surface of the knee joint is 5x6 cm dense, immobile, moderately painful.

On radiographs of the right knee joint in two projections - in the distal metaphysis of the right femur in the internal semi-cylinder there is lytic destruction with fuzzy uneven contours, spreading to half of the metaphysis and limited to the growth zone with a cloud-like ossification up to 1 cm in diameter against its background. The cortical layer is disintegrated along the inner surface throughout the metaphysis, the periosteal reaction is in the form of short frequent thin "spicules", exfoliated periostosis. There are a few small ossifications in the area of the altered cortex. Osteoporosis of the bones that form the joint.

Your conclusion:

Chronic osteomyelitis of the right femur.

Osteogenic sarcoma.

Ewing's sarcoma.

Syphilis.

**Federal State Budgetary Educational Institution
higher education "North Ossetian State Medical Academy" of the Ministry of Health
of the Russian Federation**

Department of Radiation Diagnostics with Radiation Therapy and Oncology

Faculty/ Specialty General Medicine Course

/Year of Study 3

Discipline Radiation diagnostics

Situational task No. 10

The patient is 19 years old. Returning home late at night, he was attacked by unknown persons and received numerous head injuries. There is no loss of consciousness, nausea, or vomiting. The next day, in the morning, I turned for help to a medical institution (clinic), where multiple hematomas and swelling of the soft tissues of the left half of the face were detected. When examined by a neurologist, no nystagmus or disturbances in ocular pupillary symptoms were detected. The position in the Romberg position is stable.

An X-ray examination of the skull in two projections revealed a divergence of the sagittal suture of up to 5-6 mm and the presence of a linear strip-like shadow extending posteriorly and downward from the point of convergence of the sagittal and coronal sutures of the left half of the skull. The length of this linear shadow is about 35 mm. The bones of the facial skull and the nasal septum are unchanged.

Finally, the conclusion:

Fracture of the bones of the cranial vault.

Osteochodropathy of the calvarial bones

Metastatic lesion of the bones of the cranial vault.

Multiple myeloma.

**Federal State Budgetary Educational Institution
higher education "North Ossetian State Medical Academy" of the Ministry of Health
of the Russian Federation**

Department of Radiation Diagnostics with Radiation Therapy and Oncology

Faculty/ Specialty General Medicine Course

/Year of Study 3

Discipline Radiation diagnostics

Situational task No. 11

The patient is 17 years old. Complains of heaviness in the epigastric region, a feeling of fullness in the upper abdomen after eating. The above complaints appeared three months ago. An endoscopic examination of the upper digestive tract revealed the presence of a flat exophytic formation on a broad base with a small superficial ulceration in the center. A computed tomographic examination of the abdominal organs did not reveal any pathological changes.

During an X-ray examination of the upper digestive tract, it was possible to visualize a

pathological formation located in the prepyloric region along the greater curvature immediately in front of the pylorus. The shape of the formation is oval. Dimensions 7x4 mm, The contours are quite clear and even. In the center of the formation there is a contrast agent depot measuring 3x2 mm. The walls of the stomach are elastic throughout. The motor-evacuation function of the stomach is preserved. The bulb and loop of the duodenum are not changed.

Your conclusion:

Stomach cancer

Stomach ulcer

Ménétrier's disease

Heterotopy of pancreatic tissue into the stomach wall.

**Federal State Budgetary Educational Institution
higher education "North Ossetian State Medical Academy" of the Ministry of Health
of the Russian Federation**

Department of Radiation Diagnostics with Radiation Therapy and Oncology

Faculty/ Specialty General Medicine Course

/Year of Study 3

Discipline Radiation diagnostics

Situational task No. 12

A 37-year-old patient was admitted with complaints of a mass in the right hypochondrium and a feeling of heaviness there. It is known that she tested the formation on her own three months ago. Upon examination, a slight deformity of the abdomen was revealed due to bulging of the right parts. Immediately below the edge of the liver, a round-shaped formation of soft-elastic consistency with fuzzy contours, painless, is palpated. Its mobility is limited, dimensions 10x12 cm. Irrigoscopy revealed compression and pushing of the ascending colon anteriorly and medially. There were no signs of infiltration of the intestinal walls in the area of displacement.

Ultrasound in the abdominal cavity reveals an anechoic , mobile, round formation with clear, even contours and a thin capsule. The formation is located with its upper pole under the right lobe of the liver, and its lower pole at the level of the aortic bifurcation. Within the formation, color Doppler mapping does not detect vessels.

A computed tomographic examination reveals an encapsulated liquid formation of a homogeneous structure with a density of 3 units of N in the right half of the abdominal cavity . The formation is located so that it occupies almost the entire anterior -posterior size of the right half of the abdominal cavity. The upper contour of the formation borders the lower surface of the right lobe of the liver. The right bend of the colon is located along the anterior surface of the formation. The lower border of the formation is located 4 cm above the pectineal line. Loops of the colon are adjacent to the lower pole of the formation.

Your conclusion:

Colon cancer

Kidney cancer

Inorganic retroperitoneal cyst.

Metastatic lesions of the abdominal lymph nodes

**Federal State Budgetary Educational Institution
higher education "North Ossetian State Medical Academy" of the Ministry of Health
of the Russian Federation**

Department of Radiation Diagnostics with Radiation Therapy and Oncology

Faculty/ Specialty General Medicine Course

/Year of Study 3

Discipline Radiation diagnostics

Situational task No. 13

A 49-year-old patient complained of girdle pain in the upper abdominal cavity, unrelated to food intake and time of day. The pain was relieved by taking 4 tablets of baralgin. I first noticed pain 2 months before treatment. An ultrasound examination of the abdominal cavity, performed 9 months before treatment, revealed a pancreatic cyst and the patient was warned about the safe course of the disease. However, girdle pain soon arose and the patient went to the outpatient department of the Institute of Surgery, where he was asked to conduct a CT examination of the abdominal cavity.

A CT study revealed the presence of a significant amount of fluid in the abdominal cavity, expansion of the body of the pancreas up to 27 mm, inhomogeneity of the image of the

body of the pancreas and polycyclicality of its contours. The density of the parenchyma in the tail area is 12-19 units N. In the body of the pancreas, a cyst measuring 19x18 mm with a content density of 2 units of N was visualized . In the remaining parts of the body of the pancreas, areas with a density of up to 30

unit N. interspersed with less dense ones: up to 21 units N. A group of enlarged and hardened lymph nodes was identified in the hepatoduodenal ligament. In addition, infiltrative changes were detected around the aorta throughout the origin of the celiac trunk to the level of the left renal pedicle, including the beginning of the mesenteric artery. Due to infiltrative changes in this area, the contour of the aorta in the anterior section could not be separately identified. The left adrenal gland is enlarged.

Your conclusion:

Pancreatic body cyst

Pancreatic body cancer in combination with a body cyst, complicated by lymphatic metastasis to the nodes of the lesser omentum, ascites, damage to the left adrenal gland and infiltration of the para-aortic region.

Chr. pancreatitis

Lymphadenopathy of the retroperitoneum.

**Federal State Budgetary Educational Institution
higher education "North Ossetian State Medical Academy" of the Ministry of Health
of the Russian Federation**

Department of Radiation Diagnostics with Radiation Therapy and Oncology

Faculty/ Specialty General Medicine Course

/Year of Study 3

Discipline Radiation diagnostics

Situational task No. 14

A 55-year-old patient was admitted with complaints of headache. A month before admission, during an examination in one of the medical institutions, an ultrasound and CT scan of the abdominal cavity revealed a tumor of the left kidney. It is known that the patient has been suffering from urolithiasis for 3 years. Upon admission, palpation on the left in the meso- and hypogastrium reveals a tumor-like formation measuring 14x15 cm, densely elastic consistency, limited mobility, painless, with clear contours. During SCT with bolus intravenous administration of a non-ionic contrast agent, a volumetric formation of a round shape with dimensions of 13x14x20 cm is determined in the retroperitoneal space on the left. The density of the formation is uneven: along the entire length of the image, areas of low density (11-13 units N) alternate with areas with a density of about 33 units N . Areas of low density do not accumulate contrast material, unlike areas of high density. The upper pole of the mass is located between the lower pole of the spleen, the tail of the pancreas and the upper pole of the left kidney. In the distal direction, the formation is located along the lateral edge of the left kidney, displacing it

medially and deforming it.

The kidney is partially spread out on the formation. There is a small calculus in the lower calyx . The kidney parenchyma accumulates the contrast agent to a sufficient extent. In the distal direction, the pathological formation deforms the psoas muscle and displaces the intestinal loops forward and to the right.

Your conclusion:

Colon cancer Kidney cancer

Urolithiasis disease

Non-organ retroperitoneal tumor, left kidney calculus.

**Federal State Budgetary Educational Institution
higher education "North Ossetian State Medical Academy" of the Ministry of Health
of the Russian Federation**

Department of Radiation Diagnostics with Radiation Therapy and Oncology

Faculty/ Specialty General Medicine Course

/Year of Study 3

Discipline Radiation diagnostics

Situational task No. 15

A 47-year-old patient was admitted with complaints of paroxysmal girdling pain. Ill for 5 years. An X-ray examination of the upper digestive tract in the stomach on an empty stomach revealed a significant amount

liquids. The volume of the stomach is increased. The folds of the mucous membrane are punctate . Notes

periodically occurring spasm of the pylorus. Duodenal bulb

deformed: along its postero -medial wall there is a “niche” measuring about 2 cm in diameter with signs of three layers . The passage of the contrast agent through the duodenum is slowed down, and duodeno-gastric reflux periodically occurs.

Your conclusion:

Duodenal diverticulum

Penetrating ulcer of the duodenal bulb, accompanied by deformation of the bulb, penetration into the pancreas and possibly the hepatoduodenal ligament.

Functional changes in the form of impaired motor- evacuation function of the stomach, hypersecretion.
Duplication of the duodenum. Megaduodenum .

**Federal State Budgetary Educational Institution
higher education "North Ossetian State Medical Academy" of the Ministry of Health
of the Russian Federation**

Department of Radiation Diagnostics with Radiation Therapy and Oncology
Faculty/ Specialty General Medicine Course /**Year of Study** 3
Discipline Radiation diagnostics

Situational task No. 16

Male 48 years old.

Complaints: pain in the right shoulder joint, weakness, cough.

History: pain in the right shoulder joint first appeared 3 months ago after physical activity, I was self-medicating, the pain became more intense, a cough appeared, and weakness began to increase. He was examined at the clinic at his place of residence, and pathology was detected in the lung.

Objectively: the condition is satisfactory, the range of movements in the right shoulder joint is sharply limited, pain is expressed on palpation. Horner's sign (ptosis , miosis , enophthalmos).

Auscultation : weakened breathing in the upper part of the right lung.

X-ray picture: in the apical segment of the upper lobe of the right lung there is a nodular formation 4 cm in diameter, of heterogeneous structure, closely adjacent to the chest wall, with destruction of the posterior segment of the second rib over 3 cm, the apical pleura is unevenly thickened, the angles formed with it are sharp, the lower border is convexly directed downwards, the surface is finely lumpy with radiant contours. Enlarged lymph nodes in the root zone and mediastinum are not detected.

Your conclusion:

Tuberculoma . Pencoast cancer . Tumor of the pleura.

Apical encysted pleurisy.

**Federal State Budgetary Educational Institution
higher education "North Ossetian State Medical Academy" of the Ministry of Health
of the Russian Federation**

Department of Radiation Diagnostics with Radiation Therapy and Oncology

Faculty/ Specialty General Medicine Course

/Year of Study 3

Discipline Radiation diagnostics

Situational task No. 17

Male 53 years old.

Complaints: cough, hemoptysis, pain in the right side of the chest, weakness. History: he considers himself sick for three months, when a cough, temperature up to 38, and weakness appeared. Anti-inflammatory therapy was administered at the clinic for pneumonia. The condition improved, the temperature returned to normal, but fluorography revealed pathology in the lung.

Objectively: the general condition is satisfactory, percussion - on the right back at the level of the angle of the scapula there is a percussion sound with a boxy tint, auscultation - hard breathing.

On X-ray examination, in the apical segment of the lower lobe (S6) of the right lung there was a cavity formation 4.0 x 5.0 cm with unevenly thickened walls. The internal contours of the cavity are bay-shaped, undermined. The outer contours are indistinct, radiant, the surface is coarsely lumpy. A tomographic examination reveals the draining bronchus (B6), its walls are uneven, the lumen is unevenly narrowed. In the root zone there are enlarged lymph nodes up to 1.5-2.0 cm. The barium -contrasted esophagus at the level of the tracheal bifurcation is pushed to the left and posteriorly.

Your conclusion:

Acute lung abscess.

Cavity form of peripheral cancer. Tuberculoma with decay.

Echinococcosis of the lung.

**Federal State Budgetary Educational Institution
higher education "North Ossetian State Medical Academy" of the Ministry of Health
of the Russian Federation**

Department of Radiation Diagnostics with Radiation Therapy and Oncology

Faculty/ Specialty General Medicine Course

/Year of Study 3

Discipline Radiation diagnostics

Situational task No. 18

Woman 54 years old.

Complaints: cough with copious sputum, malaise, shortness of breath, chest pain, weakness.

History: she fell ill 6 months ago, after suffering an acute respiratory infection, she began to notice a cough with sputum, which gradually worsened and the amount of sputum discharge increased. Later, weakness and chest pain began, and she gradually lost weight. Objectively: condition of moderate severity, low nutrition. The skin is pale, mild acrocyanosis. Shortness of breath up to 36 bpm, pulse 116 beats/min, blood pressure 150/90. During percussion: in the lower parts of the lungs there is an uneven shortening of the percussion sound. Auscultation: moist rales of various sizes.

The ECG shows the load on the right side of the heart.

On X-ray examination, in the lower lobes of the lungs on both sides and in the middle lobe on the right, there are areas of heterogeneous infiltrative compaction of the lung tissue of irregular shape in places with unclear contours, infiltration from the middle lobe on the right through the interlobar fissure spreads to the anterior segment of the upper lobe, and on the left - to the lingular segments. Against the background of compaction, the lumens of the lobar and segmental bronchi can be traced. No enlarged lymph nodes are detected in

the root zones and mediastinum.

Your conclusion: 1. Bilateral pneumonia
Bronchiolo -alveolar cancer.
Pulmonary edema.
Infiltrative pulmonary tuberculosis.

**Federal State Budgetary Educational Institution
higher education "North Ossetian State Medical Academy" of the Ministry of Health
of the Russian Federation**

Department of Radiation Diagnostics with Radiation Therapy and Oncology
Faculty/ Specialty General Medicine Course /**Year of Study** 3
Discipline Radiation diagnostics

Situational task No. 19

Male 56 years old.

Complaints of cough, periodic hemoptysis, weakness, weight loss, pain in the left half of the chest.

History: for 1.5 months I have been bothered by a persistent, gradually increasing cough; in recent days, hemoptysis has occurred. I lost 5 kg. Shortness of breath appeared during physical activity.

Objectively: satisfactory condition, blood pressure 130/85 mm Hg Art ., pulse 86 beats/min, respiratory rate 24. Auscultation on the left in the upper part of the weakened vesicular breathing.

On X-ray examination, the upper lobe of the left lung is reduced in volume, heterogeneously compacted, the pulmonary pattern is condensed. The upper lobe bronchus is conically narrowed, its walls are uneven. The interlobar pleura is displaced upward. There are enlarged lymph nodes in the root zone and under the aortic arch.

Your conclusion:
Infiltrative tuberculosis. Acute pneumonia.
Central cancer. TELA.

Federal State Budgetary Educational Institution of Higher Education
"North Ossetian State Medical Academy" of the Ministry of Health of the Russian Federation

Department of "Radiation diagnostics and radiation therapy with oncology"
Speciality: 05/31/01 General medicine

Practical skills plan

Descriptions of chest radiographs.

1. What kind of study is this and in what projection was the radiograph taken?
2. Indicate whether a contrast agent was used for the study, if (yes) –

That

which. How is it distributed in the anatomical structure being studied?

(evenly,

are there any pathological accumulations, leaks, etc.).

3. Compare the size and shape of the left and right halves of the chest, as well as the degree of transparency of the lung fields (is there hypoventilation, hyperventilation).
4. Compare the state of the symmetrical sections of the lungs and decide whether there are darkening, clearing, or a combination of them.
5. Determine the location of the observed changes in the pulmonary fields, if any (in the medial or lateral, upper, middle or lower pulmonary field, at the apex of the lung, at the level of which ribs), as well as the magnitude. Shape, state contours, uniformity, shadows, its intensity.
6. Determine the state of the pulmonary pattern (unchanged or changed). If there are changes, then what (strengthening, depletion, deformation) and where - (totally, locally – specify localization).
7. Describe the condition of the roots of the lungs - is the structure preserved?

or

no expansion, are there additional shadows against the background of their projection (if yes, then give a description of these shadows).

8. Give a description of the position of the mediastinal organs: is there a displacement of them, if so, in which direction (towards healthy, towards pathological changes) and to what extent.
9. Determine which group of pathology the changes belong to: diseases of the lungs, bronchial tree, pleura.
10. Give your conclusion.

Descriptions of radiographs of bones and joints.

1. What and in what projection is shown on the x-ray?
 2. Define:
 - is there a violation of the position, size, shape of the bone?
 - are there changes in the intensity of the shadow of the bone and a violation of its structure (osteoporosis , osteosclerosis, destruction, osteonecrosis , sequestration).
 - where the pathological process is localized (epiphysis, metaphysis , diaphysis), its magnitude,
- form.
- state of the contours of the pathological shadow (in the presence of periosteal changes - clarify their character) .
 - the state of the x-ray joint space (is there a change in shape, width) .
 - condition of soft tissues in the area of pathological changes
3. Indicate whether the study was performed using a contrast agent (If yes, then with which one) .
 4. Determine which group of pathologies the changes shown on the x-ray belong to.
 5. Date your conclusion.

Descriptions of radiographs of the digestive organs .

1. What is shown and in what projection was the radiograph taken?
 2. What contrast agent was used in the study, and how was it administered?
 3. after the administration of the contrast agent was the radiograph taken? (immediately, after 30 minutes, after 1 hour, after 12 hours).
 4. Determine if there are changes in the position, shape or size of the completed section of the digestive tract.
 5. Determine whether there is a change in the size of the lumen of the area under study (expansion, narrowing).
 6. Indicate whether there are niches, local protrusions, or filling defects in the section of the digestive tract being examined. Describe the localization in detail,
- form
- these changes, the state of their contours (clear - fuzzy, smooth - uneven).
7. Describe the state of the folds of the mucous membrane (thinning, thickening, incorrect location, breakage, convergence).
 8. To what group of pathology do the detected changes belong?
 9. Give your conclusion.

Descriptions of radiographs of the spine.

1. Area of research.
2. Projection of the image (direct, lateral, oblique, others).
3. Image quality assessment (physical and technical characteristics: optical

density,

contrast, image sharpness, absence of artifacts and veils).

4. Condition of soft tissues, especially para- prevertebral tissues (shape , volume, intensity and structure of the shadow).
5. The severity of physiological (lordosis , kyphosis) and the presence of pathological (scoliosis, kyphosis) bends.
6. Vertebral condition:
 - body (position , shape, size , contours, structure, ossification nuclei in young people).
 - arches (position , shape, size , contours, structure).
 - processes ((position, shape, size , contours, structure of the ossification nucleus in young people).
7. Condition of the intervertebral joints (facet joints , uncovertebral joints; in the thoracic region – costovertebral and costotransverse).
8. Condition of intervertebral discs (X-ray intervertebral spaces) - shape, height, shadow structure.
9. Condition of the spinal canal (shape and width).
10. Condition of other visible parts of the skeleton.
11. X-ray morphometry (for functional studies, scoliosis, etc.).
12. X-ray (clinical -radiological) conclusion.
13. Recommendations.

Descriptions of radiographs of the skull.

1. Projection (overview and special).
2. Assessment of the correctness of installation (according to criteria for each projection).
3. Assessment of image quality (physical and technical characteristics: optical density, contrast , image sharpness, absence of artifacts and veils).
4. Overall shape and size of the skull.
5. Correlation between the brain and facial regions.
6. Condition of the soft tissues of the skull (shape, volume, intensity and structure of the shadow) .
7. Condition of the cranial vault (shape and size, thickness and structure of bones, condition of the outer and inner plates and spongy layer, position and condition sutures, condition of vascular grooves, venous outlets, pachyonic fossae, severity of “finger impressions,” pneumatization frontal sinuses) .
8. Condition of the skull base (configuration and dimensions, boundaries and contours of the anterior, middle and posterior cranial fossae, dimensions of the angles of the skull base, condition sella turcica, pneumatization of bones, condition of natural openings in the area base of the skull and pyramids of the temporal bones) .
9. Presence of calcifications in the skull area and analysis of their shadows (physiological or pathogenic) .
10. General overview of the facial part of the skull (shape, size) .
11. Condition of soft tissues in the area of the facial skull (shape, volume, intensity and structure of the shadow) .
12. Condition of the eye sockets (shape, size, contours).

13. The nasal cavity and pyriform opening (position, shape, size , pneumatization , condition of the nasal turbinates) .
14. State of the cells of the ethmoid labyrinth (position, shape, size , contours, pneumatization) .
15. Condition of the maxillary sinuses (position, shape, size , contours, pneumatization) .
16. The condition of the visible parts of the jaws and teeth.
17. X-ray morphometry .
18. X-ray (clinical- radiological) conclusion.
19. Recommendations.

Descriptions of radiographs of the urinary system.

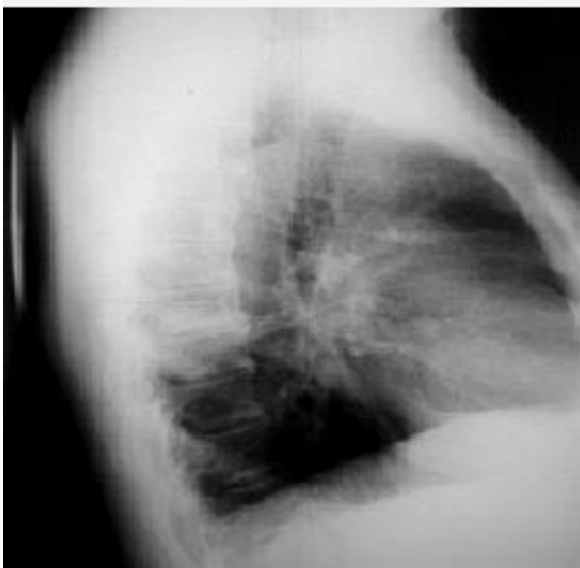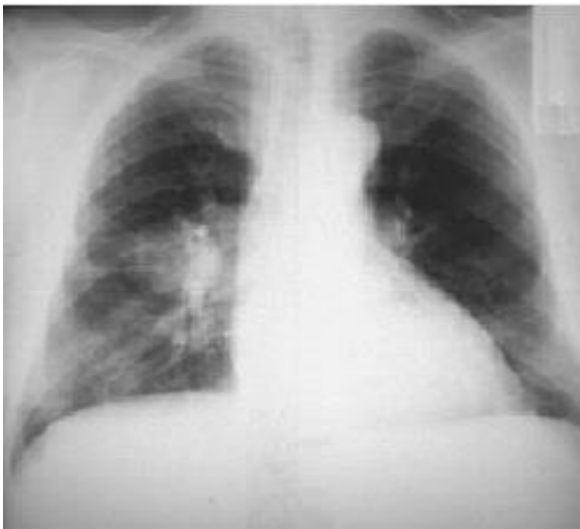1. Conditions of the study (type, concentration, quantity and method of administration of contrast agent, projection and sequence of images: position patient, breathing tests, etc. conditions).
2. Assessment of image quality (quality of patient preparation for examination, physical Specifications 6: optical density, contrast, image sharpness, absence of artifacts).
3. The condition of the visible parts of the skeleton.
4. Condition of soft tissues and neighboring organs.
5. Contours of the psoas major muscles, compared on both sides (determined or no, even - uneven, clear - not clear).
6. Position of the kidneys.
7. Kidney shape. 8. Kidney sizes.
9. Kidney contours.
10. Intensity and structure of the bud shadow.
11. The presence of additional shadows in the projection of the urinary tract and other organs of the retroperitoneal space and abdominal cavity, suspicious for stones, petrificates , tumors , etc.
12. Comparative assessment of the release of contrast agent by the kidneys (timing and severity of the nephrographic phase, timing and nature of filling the abdominal cavity with contrast systems) .
13. Position, shape and size of the cups and pelvis.
14. The position, shape, contours and width of the lumen of the various parts of the ureters.
15. The degree and nature of filling of the ureters with a contrast agent.
16. Position, shape, size of the bladder.
17. Contours and structure of the bladder shadow.
18. X-ray (clinical- radiological) conclusion. 19. Recommendations.

Descriptions of radiographs of the heart and large vessels.

1. What kind of study is this and in what projection was the radiograph taken?
2. Indicate whether a contrast agent was used for the study, and if so, what kind. How is it distributed in the anatomical structure under study (evenly, are there pathological accumulations, streaks, etc.).
3. Compare the size and shape of the left and right halves of the chest, as well as the degree of transparency of the lung fields (is there hypoventilation, hyperventilation).
4. Compare the state of the symmetrical sections of the lungs and decide whether there are darkening, clearing, or a combination of them.
5. Determine the location of the observed changes in the pulmonary fields, if any (in the medial or lateral, upper, middle or lower pulmonary field, at the apex of the lung, at the level of which ribs), as well as the magnitude. Shape, state of contours, uniformity, shadows, its intensity.
6. Determine the state of the pulmonary pattern (unchanged or changed). If there are changes, what kind (strengthening, depletion, deformation) and where - (totally, locally - clarify localization).
7. Give a description of the condition of the roots of the lungs - is the structure preserved, is there expansion or not, are there additional shadows against the background of their projection (if yes, then give a description of these shadows).
8. Give a description of the position of the mediastinal organs:
9. Its position in the chest (only for heart defects).
10. Characteristics of the cardiac waist, heart configuration in mitral and aortic defects.
11. Diameter of the heart: the ratio of the right and left diameter.
12. Condition of the heart chambers.
13. Characteristics of heart contractions during research behind the screen (depth, rhythm).
14. Is there a displacement of them, if so, in what direction (towards healthy, towards pathological changes) and to what extent.
15. Condition of the aorta.
16. Determine which group of pathology the changes belong to: diseases of the heart or aorta.
17. Give your conclusion.

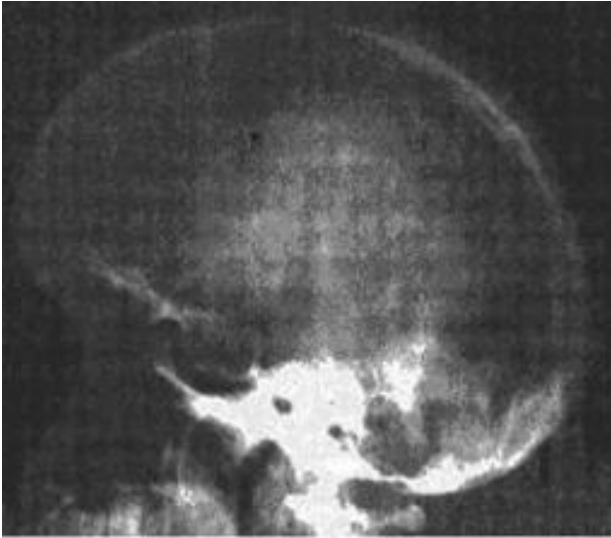
Practical task No. 1

Protocol. Describe the radiograph. (central lung cancer)



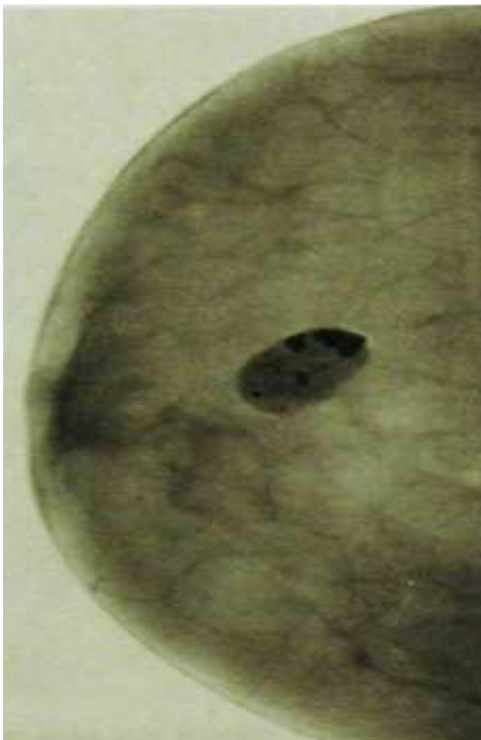Practical task No. 2

Protocol. Describe the radiograph (pituitary adenoma)



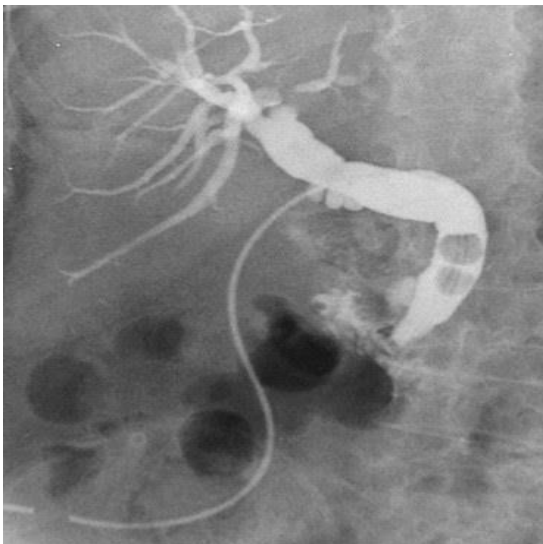
Practical task No. 3

Protocol. Describe the radiograph. (single fibroadenoma with lumps of lime)



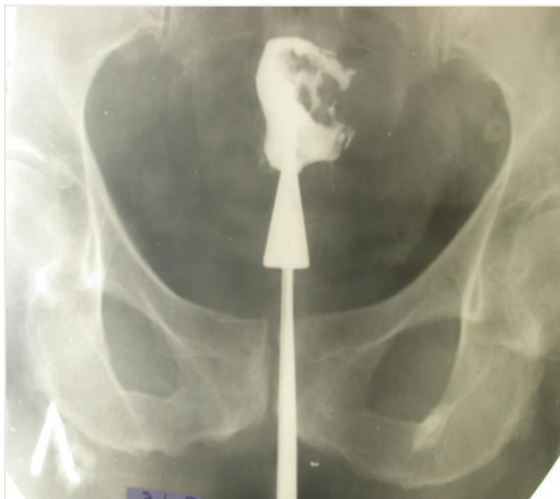Practical task No. 4

Protocol. Describe the radiograph (cholecystolithiasis)



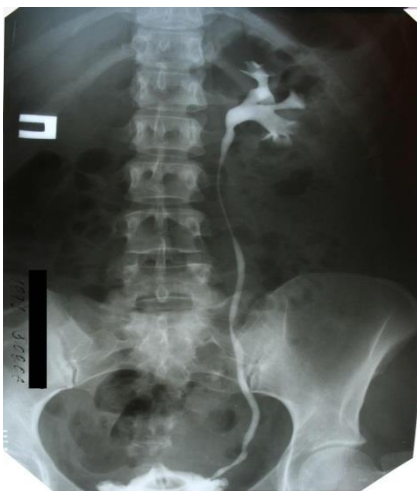Practical task No. 5

Protocol. Describe x-ray (uterine cancer)



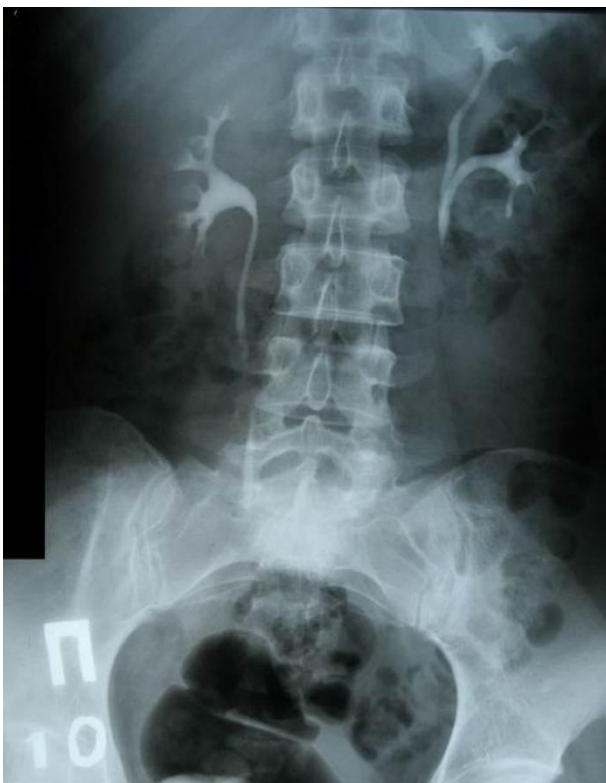Practical task No. 6

Protocol. Describe the radiograph (urolithiasis)



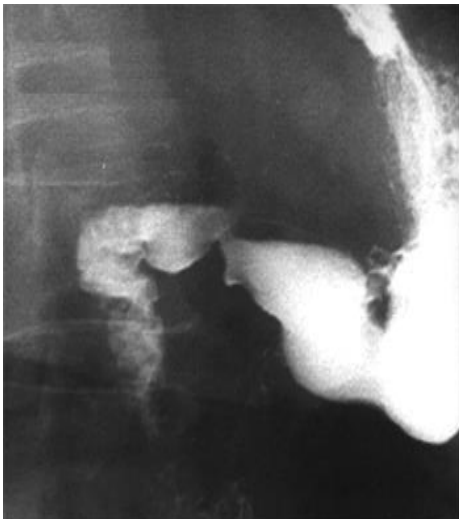Practical task No. 7

Protocol. Describe the radiograph (double left kidney)



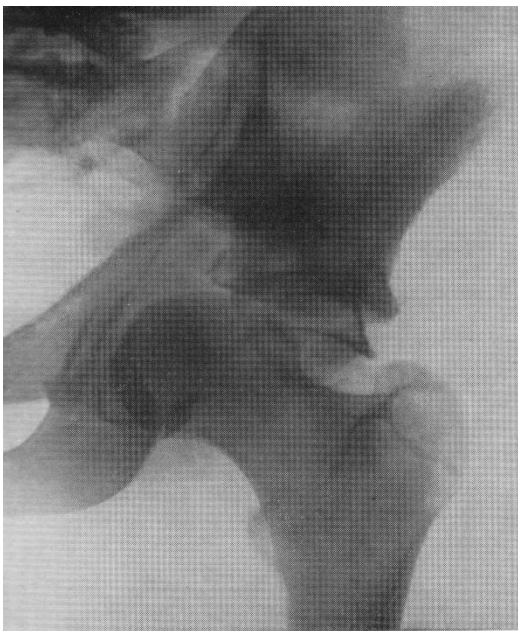
Practical task No. 8

Protocol. Describe the radiograph (antral ulcer)



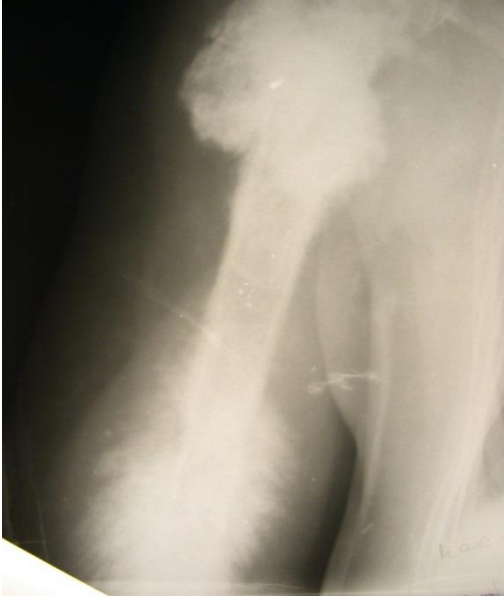Practical task No. 9

Protocol. Describe the radiograph (fracture-dislocation of the left hip)



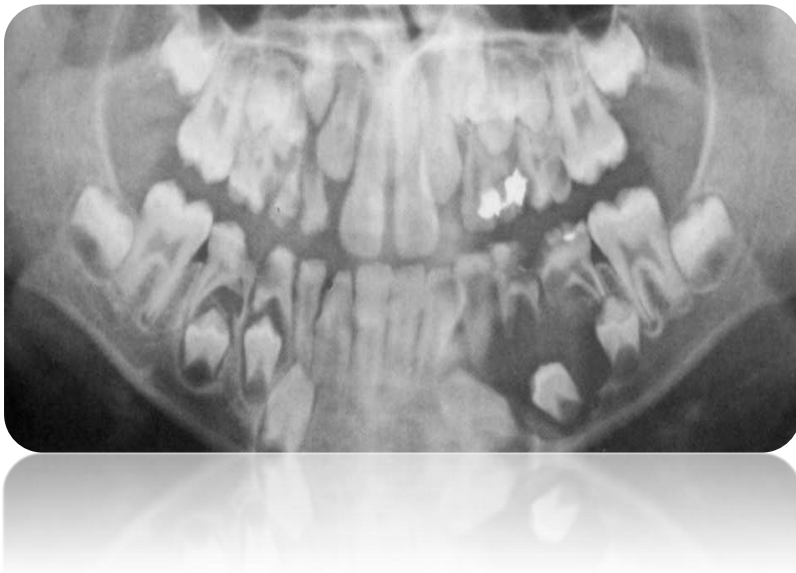
Practical task No. 10

Protocol. Describe the radiograph (osteosarcoma of the shoulder , osteoblastic variant)



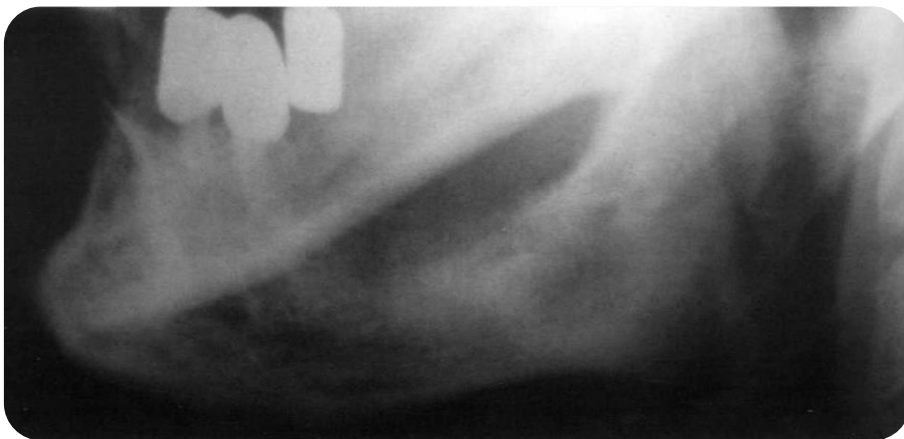Practical task No. 11

Protocol. Describe the radiograph (follicular cyst)



Practical task No. 12

Protocol. Describe the radiograph (phobrosarcoma)



Business game No. 1

In the office of a radiologist, a woman with a 7-year-old child with a referral from a phthisiatrician regarding the increase in the Mantoux test.

Instructions for simulating a doctor

Your task: explain to the woman the possible reasons for the increase in the Mantoux test and offer to conduct an X-ray examination.

Instructions for simulating a patient

Patient: Ask your doctor about the possible risks associated with radiation during an x-ray examination.

Important: insist on the need for an x-ray examination. Give arguments in favor of x-ray examination

Explanation:

Determine the need for x-ray examination

Determine the method and projection of x-ray examination

Describe the radiograph

Give a conclusion

Business game No. 2

A 45-year-old man is in the radiologist's office . I applied on my own without a doctor's referral.

Instructions for simulating a doctor:

Your task: find out additional complaints, how many days the man considers himself sick, and what is associated with the appearance of pain in the finger.

Instructions for simulating a patient:

Instructions for the patient: Complain of acute pain in the finger, insist on an x-ray examination

Important: due to the lack of a doctor's referral, a preliminary diagnosis, based on the patient's complaints and examination data, determine the need for an x-ray examination. Carry out differential . diagnosis between osteomyelitis and fracture

Explanation:

Determine the need for x-ray examination

Determine the method and projection of x-ray examination

Describe the radiograph

Give a conclusion

Business game No. 3

In the office of a radiologist (in a hospital setting) a patient with suspected intestinal obstruction.

Instructions for simulating a doctor : conduct an x-ray examination (determine the optimal projection, placement, etc.), identify x-ray signs of intestinal obstruction

Your task: describe the photo, write a conclusion

Instructions for the patient :

Describe your complaints about diffuse pain in the abdominal area, increasing over the course of three days.

Important: perform an X-ray examination and make a timely conclusion.

Explanation:

Determine the need for x-ray examination

Determine the method and projection of x-ray examination

Describe the radiograph

Give a conclusion

Federal State Budgetary Educational Institution
higher education "North Ossetian State Medical Academy" of the Ministry of Health
of the Russian Federation

Discipline Radiation diagnostics

Business game No. 4

A 40-year-old woman is in the radiologist's office with a referral from the clinic for a chest x-ray.

Instructions for simulating a doctor : determine projections, describe the image, make a conclusion

Patient simulation instructions :

Complain of malaise, pain in the right side when moving and breathing, cough without sputum discharge.

Your task: based on complaints, anamnesis, and x-ray pictures, confirm or refute the diagnosis of the referring institution.

Important: Carry out differential diagnosis (pneumonia, myositis, osteochondrosis of the thoracic spine)

Explanation:

Determine the need for x-ray examination

Determine the method and projection of x-ray examination

Describe the radiograph

Give a conclusion

**Federal State Budgetary Educational Institution
higher education "North Ossetian State Medical Academy" of the Ministry of Health
of the Russian Federation**

Department of Radiation Diagnostics with Radiation Therapy and Oncology

Faculty/ Specialty General Medicine Course

/Year of Study 3

Discipline Radiation diagnostics

Business game No. 5

In the fluoroscopy room (in a hospital setting), a 60-year-old woman was brought in by relatives after a fall at home.

Instructions for simulating a doctor : collect a brief history, complaints, determine the optimal x-ray diagnostic method.

Instructions for the patient : complain of intense pain in the lower back that appeared after a fall and lasted for 2-3 hours.

Your task: based on the history, complaints and preliminary diagnosis of the referring institution (ambulance), determine the optimal research method .

Important: Carry out a differential . diagnosis between renal colic, osteochondrosis of the lumbar spine, vertebral fracture

Explanation:

Determine the need for x-ray examination

Determine the method and projection of x-ray examination

Describe the radiograph

Give a conclusion

**Federal State Budgetary Educational Institution
higher education "North Ossetian State Medical Academy" of the Ministry of Health
of the Russian Federation**

Department of Radiation Diagnostics with Radiation Therapy and Oncology

Faculty/ Specialty General Medicine Course

/Year of Study 3

Discipline Radiation diagnostics

Business game No. 6

A 30-year-old woman is in a radiologist's office with a referral from an ENT doctor for an X-ray examination.

Instructions for simulating a doctor : determine the method and projection of an x-ray examination

Instructions for the patient : complain about headaches that appear when tilting the head forward, general malaise, purulent discharge from the nose.

Your task: determine the method and projection for x-ray examination

Explanation:

Determine the need for x-ray examination

Determine the method and projection of x-ray examination

Describe the radiograph

Give a conclusion

**Federal State Budgetary Educational Institution
higher education "North Ossetian State Medical Academy" of the Ministry of Health
of the Russian Federation**

Department of Radiation Diagnostics with Radiation Therapy and Oncology

Faculty/ Specialty General Medicine Course

/Year of Study 3

Discipline Radiation diagnostics

Business game No. 7

In the X-ray room in a dental clinic, a 55-year-old woman with a referral for OPTG.

Instructions for the doctor : collect a brief history, complaints

Your task: to produce OPTG

Instructions for the patient : complain of acute pain in the right half of the face, radiating to the right half of the head and ear; aggravated by chewing and talking, lasting for 10-15 hours.

Important: Carry out a differential . diagnosis between acute caries, retention and inflammation of the trigeminal nerve branch

Explanation:

Determine the need for x-ray examination

Determine the method and projection of x-ray examination

Describe the radiograph

Give a conclusion

**Federal State Budgetary Educational Institution
higher education "North Ossetian State Medical Academy" of the Ministry of Health
of the Russian Federation**

Department of Radiation Diagnostics with Radiation Therapy and Oncology

Faculty/ Specialty General Medicine Course

/Year of Study 3

Discipline Radiation diagnostics

Business game No. 8

8

In the X-ray room there is a woman with a 3-year-old child. The mother believes that the child swallowed an iron part from the cars.

Instructions for simulating a doctor : collect a brief history and complaints

Your task: to choose the optimal method of x-ray examination in this case

Instructions for the patient : You suspect that the child has swallowed a part from a typewriter (most likely iron).

Important: based on the mother's words and the child's complaints, try to find out whether the machine part was aspirated .

Explanation:

Determine the need for x-ray examination

Determine the method and projection of x-ray examination

Describe the radiograph

Give a conclusion

Federal State Budgetary Educational Institution
higher education "North Ossetian State Medical Academy" of the Ministry of Health of the
Russian Federation

Department of Radiation Diagnostics with Radiation Therapy and Oncology

Standards of test tasks

in the discipline _____ Radiation diagnostics _____

main professional educational program of higher education - specialty program in specialty
05/31/01 General Medicine, approved 05/24/2023.

For _____ 3rd year students _____
(students/residents/postgraduates/listeners – select the required (course/year of study)

specialty 05/31/01 General Medicine
(code/name)

Table of contents

No.	Name of the controlled section (topic) of the discipline/module	Code of competence being formed (stage)	Number of tests (total)	p. from __ to __
1	2	3	4	5
View control	Ongoing progress monitoring/interim assessment			
1.	Incoming control of the level of training of students Introduction. General issues of radiation diagnostics and radiology.	OPK-9 PC-1 PK-5 PK-6 PK-7 PK-21	35	1-3
2.	Radiation diagnostics in neurology	OPK-9 PC-1 PK-5 PK-6 PK-7 PK-21	13	3-4
3.	Lungs in X-ray image	OPK-9 PC-1 PK-5 PK-6 PK-7 PK-21	20	4-6
4.	Radiation diagnostics of the heart and large vessels.	OPK-9 PC-1 PK-5 PK-6 PK-7 PK-21	10	8-9
5.	The osteoarticular system in a radial image adults and children.	OPK-9 PC-1 PK-5 PK-6 PK-7 PK-21	10	9-10
6.	Methods for radiological diagnosis of esophageal diseases, stomach, intestines. Defects and anomalies of development in children..	OPK-9 PC-1 PK-5 PK-6 PK-7 PK-21	10	6-7
7.	Complex radiation diagnosis of diseases of the hepato- pancreato - biliary system.	OPK-9 PC-1 PK-5 PK-6 PK-7 PK-21	2	7
8.	Comprehensive radiographic examination of	OPK-9 PC-1 PK-5	eleven	10-11

	the kidneys and urinary tract	PK-6 PK-7 PK-21		
9.	Mammography. Radial diagnostics of genital organs.	OPK-9 PC-1 PK-5 PK-6 PK-7 PK-21	6	8
10.	Radiation diagnostics in otorhinolaryngology, endocrine system	OPK-9 PC-1 PK-5 PK-6 PK-7 PK-21	16	11-13

*The name of the controlled section (topic) or topics (sections) of the discipline/module and the code of the competence being formed is taken from the work program of the discipline.

Preventive fluorographic examination of mandatory contingents is carried out
+ "continuous" - once every 2 years
differentiated - once every 2 years differentiated with favorable conditions
epidemiological situation for tuberculosis - once every 3 years continuously" –
from the age of 7-12 years

Which organs and tissues of the patient need priority protection from ionizing radiation?
thyroid gland mammary gland
+bone marrow, gonads skin

Where should a personal dosimeter be located?
above the apron at chest level
under the apron at chest level
above the apron at pelvic level
+under the apron at pelvic level

The development of radiology is associated with the name of V. Roentgen , who discovered radiation,
which was later named after him
in 1890
+ in 1895
in 1900
in 1905

The attenuation of a radiation beam when passing through various objects depends
from absorption by the substance of the object
from the convergence of rays
from ray interference
from scattering
+ correct a) and d)

Conventional X-ray image
+more subject to shoot
smaller than the subject being photographed
equal to the object being photographed
all answers are correct

When examining in oblique projections it is possible to make
two pictures
four pictures
eight pictures
+unlimited number of photos

Subtraction of shadows during plain radiography
facilitates the detection of pathological changes
+ makes it difficult to detect pathological changes
does not affect the detection of pathological changes

The diagnosis of a patient according to S.P. Botkin is established on the basis
careful examination of the diseased organ
application of additional methods for using functional samples
+studying the state of the whole organism

During the functional Valsalva maneuver
the size of varicose veins of the esophagus increases
+ the size of varicose veins of the esophagus decreases
the size of varicose veins of the esophagus is preserved
pulmonary pattern intensifies

In the classical case, scattered radiation has

higher energy than the original radiation
+less energy than the original radiation
the same energy as the original radiation
there is no correct answer

The source of electrons for producing X-rays in the tube is a rotating anode
+ filament
focusing cup
tungsten target

The percentage of energy of electrons colliding with the anode of the X-ray tube and being converted into X-ray radiation is
+1%
5%
10%
50%
98%

The quality of the image is affected by the following parameters of the X-ray cassette:
+case material
lock design
elastic material for screen clamping
cassette weight

The purpose of using lead diaphragms in the X-ray emitter is to shorten the exposure time
+limitation of the X-ray beam reduction of development time filtering out soft radiation

To obtain an image in computed tomography, the following is used:
+ x-ray radiation;
ultrasonic radiation;
magnetic resonance radiation;
radiation produced by the spontaneous decay of a nucleus.

The formation of a CT image is based on:
different acoustic densities of fabrics;
selective accumulation of radiopharmaceuticals in tissues and organs;
+ multi-projection measurement of the X-ray attenuation coefficient;
different proton densities of organs and systems.

The images obtained with CT are:
+ many layer-by-layer sections of the object;
projection of an object onto a plane;
one-dimensional amplitude image in the form of bursts on the center line;
sweep of the amplitude signal over time.

Hypodense structures in a CT image look like:
white;
gray;
+ black;
Any of the above options is possible.

Hyperdense structures in a CT image look like:
+white; gray; black;
Any of the above options is possible.

Hypodense on CT are:
+gas, liquor, area of edema;
bone tissue, fresh blood;
brain, parenchymal organs;
all the listed structures.

Hyperdense on CT are:
gas, cerebrospinal fluid, area of edema;
+bone tissue, fresh blood;
brain, parenchymal organs;
all the listed structures.

MRI is based on:
on the ability of tissues to resonate with the frequency of ultrasonic waves; on the bending of X-rays in a magnetic field;
+ on the ability of the nuclei of some atoms to behave like magnetic dipoles; on the acceleration of the spontaneous decay of certain atoms in a magnetic field.

Modern MRI scanners are “tuned” to the following nuclei:
+hydrogen, i.e. protons; calcium;
gland; carbon.

MR radiation is received by:
when electrons are decelerated at the moment of collision with the anode;
+ when excitation of hydrogen nuclei of a biological object in a magnetic field; due to the piezoelectric effect ;
during spontaneous nuclear decay.

A patient placed in a “ tunnel” of a magnetic resonance imaging scanner may experience:
+claustrophobia;
pressure ulcers due to the length of the study; allergy to magnetic field;
combination of all manifestations.

When interpreting MRI results, the following terms are used:
+ hypointense , hyperintense ;
hypoechoic , hyperechoic ;
hypodense , hyperdense ; h
darkening , enlightenment.

During an MRI, the patient:
+ not exposed to ionizing radiation; exposed to ionizing radiation in all cases;
exposed to ionizing radiation only when performing contrast techniques;
exposed to ionizing radiation only when using high-field magnets.

Ultrasonic waves are received by:
when a stream of electrons collides with the anode surface;
+due to the piezoelectric effect ;
during spontaneous decay of nuclei;
by exciting protons in a magnetic field.

What is the dependence of the frequency of ultrasonic waves and their penetrating ability:
the lower the wave frequency, the lower the penetrating ability;
+ the higher the wave frequency, the lower the penetrating ability;
there is no correlation between the frequency of the ultrasonic wave and its penetrating power; it all depends on the specific settings of the ultrasound machine.

anechoic :
+ freely transmitting ultrasonic waves and appearing black on the screen; moderately absorbs ultrasonic waves and appears gray on the screen;
having high acoustic resistance and appearing light or white;
reflecting ultrasonic waves.

hyperechoic are:
freely transmitting ultrasonic waves and appearing black on the screen;
moderately absorbs ultrasonic waves and appears gray on the screen;
+having high acoustic resistance and appearing light or white;
reflecting ultrasonic waves.

An acoustic shadow is called:

a zone free from ultrasonic waves located behind the ultrasound machine;

an area of about 1 m behind the transducer (sensor);

+ the space behind the hyperechoic object, into which ultrasound rays do not penetrate, and the contents of which cannot be assessed; appears as a black bar on the screen;

method of shadowless illumination of an ultrasound diagnostic room.

Visualization of objects during ultrasound depends on:

+ the ability of an object to transmit, absorb or reflect ultrasonic waves;

physical density of the object;

proton density of the object;

elastic properties and elasticity of the object.

Among biological tissues, obstacles to ultrasound are:

gas (in the lungs, intestines);

+bone;

both of the above fabrics;

there are no obstacles.

The most informative in diagnosing a linear fracture of the bones of the calvarium is overview (direct and lateral) radiographs

+targeted tangent radiographs

targeted contact radiographs

direct tomograms

The most common skull fractures occur in the area

occipital bone

+ frontal bone temporal bone sphenoid bone

Variants of skull fractures include the "green stick" type.

transverse

+ depressed

oblique with divergence of fragments

The most commonly identified normal forms of the sella turcica include

flask-shaped

flat

+oval

rounded

Age features of the skull include

+ condition of seams

pattern of vascular grooves

severity of development of finger impressions development of graduates

The most reliable radiological sign of pituitary adenoma is

+increase in the size of the sella turcica

osteoporosis of saddle parts

increased pneumatization of the main sinus

decreased pneumatization of the main sinus

The term "relief of the bones of the cranial vault" means

drawing of venous sinuses

pattern of arterial grooves

finger indentation pattern

+drawing of all the formations listed above

The most informative research method for traumatic brain injury is

+craniography

tomography

angiography
pneumoencephalography

Common benign tumors of the calvarium include
osteoma
+ hemangioma
osteochondroma
cyst

A symptom of swelling of the bones of the calvarium is observed
for osteosarcoma
with osteomyelitis with osteoma
+ for fibrous dysplasia

Hemangioma of the calvarial bones is characterized by
limited osteosclerosis
hyperostosis
+local osteoporosis with a coarse cellular structure
widespread cellularity

The most reliable radiological sign of intracranial hypertension in a child is
thinning of the bones of the arch
+seam divergence
deepening of digital impressions, expansion of diploic vein canals

The focus of destruction in the bones of the vault may disappear spontaneously
with tumor metastasis
for myeloma
with eosinophilic granuloma
+ for osteomyelitis

The main symptom of complete craniostenosis is skull deformation
thinning of the bones of the calvarium, increased digital impressions
+ early closure of seams

The X-ray picture of metastases in the skull is characterized more often
+multiple foci of destruction,
single foci of destruction,
foci of sclerosis
foci of hyperostosis

Fluoroscopy makes it possible to study
pulmonary drawing
+ diaphragm mobility
condition of the interlobar pleura
small focal shadows

To identify bronchiectasis, the most informative diagnostic technique is radiography.
tomography
+bronchography angiopulmonography

Pulmonary pattern during Valsalva maneuver
does not change
intensifies
+ depletes thickens

With pneumothorax, the root of the lung is displaced
up
downwards
+ medially outwards

In case of total darkening, accompanied by a decrease in the lung, it is primarily determined narrowing of the intercostal spaces; high position of the dome of the diaphragm decrease in the vertical size of the lung, displacement of the mediastinal organs
+ correct a), b) and d)

Shift of the mediastinum to the healthy side is typical
for lung cancer
+for exudative pleurisy
for progressive pulmonary dystrophy
for chronic pneumonia

Pulmonary artery hypoplasia appears
+depletion of the pulmonary pattern
increased bronchopulmonary pattern
deformation of the pulmonary pattern
lack of pulmonary pattern

Differential diagnosis between focal tuberculosis and focal pneumonia is decided by size of lesions
outlines of focal shadows
no petrification
+process dynamics

The most characteristic sign of interstitial pneumonia is a massive infiltrate
miliary dissemination
+ deformation of the pulmonary pattern
pleural effusion

The most typical characteristics of a draining acute lung abscess are:
+horizontal liquid level presence of “sequester”
presence of a “path” to the root no signs

In bronchiectasis, changes are most often localized
in the upper lobe of the right lung
in the middle lobe of the right lung
in the lower lobe of the right lung
+ in the lower lobe of the left lung

Broncholithiasis is
any foreign body of the bronchus calcified root lymph node
+ calcified lymph node protruding into the bronchus, calcification of the bronchial wall

The primary tuberculosis complex is characterized by lobar darkening
bilateral lesion
+ expansion of the root shadow on one side; fluid in the pleural cavity

Tuberculous bronchadenitis is characterized by
bilateral damage to all intrathoracic lymph nodes with calcification along the contour; unilateral enlargement of one or two groups of intrathoracic lymph nodes
root expansion combined with a focus in the lung
bilateral enlargement of bronchopulmonary lymph nodes
+correct b) and c)

Tuberculosis infiltrate is characterized
heterogeneous triangular-shaped darkening of a segment or lobe of the lung
+darkening with an unclear contour and dropout areas; darkening of a segment with a decrease in its volume
round focus with decay and liquid level

Stage II sarcoidosis differs from disseminated pulmonary tuberculosis
+ the nature of changes in the roots of the lungs and mediastinum

the nature of pulmonary dissemination
bronchographic picture of pleural changes

The division of cancer into central and peripheral is carried out according to the principle
lobar localization
+level of damage to the bronchial tree form
relation to the pleura

Characteristic symptoms of central cancer detected on tomograms are
maintaining bronchial lumen
bronchus amputation
conical bronchial stump no clear symptoms
+correct b) and c)

Rare forms of lung cancer include central cancer
"small" peripheral cancer
branched peribronchial
+ apical (Pencoast tumor type)

Surrounding lung tissue in peripheral lung cancer
+ sometimes has a stringy path from the tumor to the root does not change
often has focal shadows around
the tumor is always connected by a wide path to the root

X-ray examination of the digestive tract 24 hours after taking a barium suspension is used
for the study of colon pathology for the study of the ileocecal region
+ to control the timing of passage of barium suspension through the gastrointestinal tract, study the
position of the large intestine
for studying the pathology of the small intestine

The most informative method for studying the biliary system is cholelithiasis is
ERCP
+ Ultrasound
intravenous cholecystocholangiography
infusion cholegraphy

The optimal interval between oral administration of a contrast agent and x-ray examination of the
gallbladder is
8-10 hours
+10-12 h
12-15 h
15-20 hours

Esophageal cancer is more common in the upper esophagus
+ in the middle part of the esophagus
in the lower esophagus
in the abdominal segment of the esophagus

A large extent of changes in the esophagus in the form of multiple defects with areas of wall rigidity are
most characteristic
for polyps for cancer
+for sarcoma
for varicose veins

Esophageal diverticula formed during chronic mediastinitis are called Zenker's diverticula .
epiphrenal
pulsion
+ traction

Zenker's diverticula form
on the anterior wall of the esophagus

+ on the posterior wall of the esophagus
on the lateral walls of the esophagus
on the anterior and lateral walls of the esophagus

Narrowing of the lumen of the esophagus is not typical
for endophytic cancer
for esophageal ulcers
+for varicose veins for benign tumors

A pointed niche of the lesser curvature of the body of the stomach up to 1 cm in diameter, protruding beyond the contour, with symmetrical shaft, elastic wall around can be
+ for a benign ulcer with a penetrating ulcer
with a malignant ulcer
for infiltrative ulcerative cancer, a) and d) are correct

The defining symptoms of endophytic (infiltrative) gastric cancer are a decrease in the size of the gastric bladder,
lack of peristalsis,
violation of gastric emptying
central filling defect, relief defect,
additional shadow against the background of the gas bubble of the stomach
+ shortening of the lesser curvature of the stomach, rigidity of its walls, absence of folds, microgastria
filling defect, atypical relief, impaired peristalsis

A single central filling defect of an irregularly rounded shape measuring more than 3 cm, easily moving by more than 10 cm, is characteristic of:
polyp
non-epithelial tumor polyposis carcinoma
+ bezoar

A single round filling defect in the colon with a tuberos surface measuring more than 3 cm is a radiological sign
diverticulum
+ exophytic cancer
polyp
Hirschsprung's disease

Large gall bladder, low-intensity shadow, after taking a choleretic agent of contrasted bile remains in it . Hypertonic, hyperkinetic dyskinesia occurs
+hypotonic, hypokinetic dyskinesia
spasm of the sphincter of Oddi
hydrocele of the gallbladder

The formation of gallstones is caused by the processes
mechanical
chemical
+physical and chemical
infectious

X-ray examination of the mammary glands during mass screening examinations is preferable to perform
direct or lateral projection
in frontal and lateral projection
in direct and oblique projection
+ in oblique projection

The absolute indication for ductography is nipple discharge
of any nature
serous in nature
bloody in nature
+ serous and bloody in nature

Mammography is preferred
from the 1st to the 5th day of the menstrual cycle
+from the 6th to the 12th day of the menstrual cycle
in the second half of the menstrual cycle
doesn't matter

The greatest differential diagnostic value between the nodular form of mastopathy and a malignant neoplasm is
blurred contours
hypervascular symptom
+change in education size
depending on the phase of the menstrual cycle, the presence of lumpy calcifications

Differential diagnosis between the infiltrative-edematous form of breast cancer and the inflammatory process is based
on changes in breast size
on diffuse restructuring of the mammary gland on thickening of the skin of the mammary gland
+differential diagnosis is limited

Differential diagnosis between nodular mastopathy and breast cancer allows
+change in education size
depending on the phase of the menstrual cycle, the intensity of the formation shadow
presence of calcifications
the nature of the contours of education

insufficiency in the right oblique projection is characterized by the radius of the arc of deviation of the contrasted esophagus
small
average
+big
no esophageal deviation

In the right projection, the contrasted esophagus deviates along a large radius arc posteriorly and moves posteriorly during left ventricular systole. This symptom is observed when
aortic stenosis
with mitral stenosis
+ for mitral insufficiency
with aortic valve insufficiency

Depletion of the vascular pattern of the lungs is typical
for mitral valve insufficiency
+ for notebook Fallot
for ventricular septal defect
for patent ductus arteriosus

The patterns of the ribs are characteristic
for the right aorta
for double aortic arch
+for coarctation of the aorta
for aortic stenosis

A sharply hypertrophied right ventricle in direct projection can form
second arch along the right contour of the heart
the first arch along the right contour of the heart
second arch along the left contour of the heart
+ fourth arch along the left contour of the heart

Obligatory enlargement of the left atrium is accompanied by
coarctation of the aorta
Fallot's triad

+mitral stenosis aortic aneurysm

Curley lines can be determined
with coarctation of the aorta
atrial septal defect
+ for mitral stenosis with Ebstein's anomaly

Small radius of the arc of deviation of the contrasted esophagus (right anterior oblique projection) is a characteristic symptom
for transposition of great vessels
for atherosclerotic cardiosclerosis
+for mitral stenosis for Ebstein's anomaly

Obtuse cardiophrenic angles are observed in tetralogy Fallot
with complete transverse heart block
+ for myocarditis
with coarctation of the aorta

A large radius of the arc of deviation of the contrasted esophagus (right anterior oblique projection) is characteristic
for armored heart for mitral stenosis
+for mitral insufficiency for tricuspid stenosis

In case of damage to the menisci of the knee joints, informative radiography in typical projections
radiography in oblique projections
tomography
+ contrasting of the knee joint cavity

The absence of radiological changes in the osteoarticular apparatus in the first 2-3 weeks, followed by rapid dynamics of the radiological picture, is typical
+ for acute nonspecific inflammatory processes
for tuberculous lesions
for syphilis

Hematogenous purulent osteomyelitis in long bones is characterized by lesions
diaphysis
pineal gland
+ metaphysis
diaphysis and epiphysis

Changes in the bone and periosteum in hematogenous osteomyelitis in adults appear within a period of time
7-10 days
+2-3 weeks
1-1.5 months
2 months

Early periosteal reaction in hematogenous osteomyelitis looks like
+linear shadow
strips of periosteal layers layered
spicule-like

Tuberculous osteitis most often occurs
+ in the pineal gland
in the metaphysis
in the diaphysis
in the apophysis

Tuberculous osteitis is characterized by
+destruction of bone tissue

periosteal reaction
regional osteoporosis
bone atrophy

Tuberculous osteitis in the hip joint is localized
in the head of the femur
in the neck of the femur
in the acetabulum
+correct b) and c)

Not typical for benign bone tumors
+thickening of soft tissues
normal soft tissue thickness
normal soft tissue structure

The most characteristic of malignant bone tumors is
thinning of the cortex
breakage of the cortical layer with gradual thinning towards the point of breakage
breakage of the cortical layer against the background of swelling (symptom of “spikes”)
+steep cliff of the cortical layer

cavernous tuberculosis of the kidney in the nephrographic phase
+ parenchyma defect “white” kidney
no kidney contrast
intense uneven contrasting of the parenchyma

Symptoms of a kidney tumor include
+ amputation of the calyx
weak nephrographic phase
reduction in kidney size
hypotension of the calyces and pelvis

To identify the condition of the pelvis and calyces when the kidney is “off,” you can use
infusion urography
+retrograde pyelography
plain radiography
computed tomography

Plain radiograph of the urinary tract shows a shadow of the bladder
+rarely detected
always revealed
never revealed
perfectly detected

An enlarged, heterogeneous shadow of the kidney with uneven contours on a plain radiograph, a filling defect, expansion or “amputation” of the calyx on a retrograde pyelogram, a filling defect of the pelvis with uneven, pitted contours are the most typical
for solitary cyst
for hydronephrosis
+ for kidney tumor
for kidney tuberculosis

Significant narrowing of the stem part of the renal artery and its segmental and subsegmental branches, the formation of avascular zones. The intrarenal arterial branches are shifted predominantly to the periphery, as if apart. These signs are most characteristic
for solitary cyst
for hydronephrosis
+ for kidney tumor
for pyelonephritis

Reduction in the size of the kidney, deformation of the pyelocaliceal system, uneven contours of the small

calyces, obliteration of small vessels of the renal cortex are most typical for kidney tuberculosis
+for wrinkled kidney for kidney hypoplasia
for kidney tumor

The most common kidney diseases include
glomerulonephritis
+pyelonephritis
nephroptosis
tumors

The most common initial site of kidney and urinary tract cancer is
pelvis
+renal parenchyma
calyces
ureter
bladder

The most common initial localization of the tuberculosis process in the kidney is
medulla
cortex
calyces and pelvis
papillary zone
+ medulla and papillary zone

Cancer alertness means knowledge
+early symptoms of the disease
drugs for treatment
professional difficulties
permissible doses of radiation therapy

The main clinical manifestation of cancer of the mucous membrane of the floor of the mouth is
erosion without edge infiltration
ulcer without infiltration of edges
hyperemia and swelling of the mucous membrane
+ulcerating infiltrate adherent to surrounding tissues

The most common location of cancer is in the oral cavity
floor of the mouth
buccal mucosa
alveolar process of the maxilla
+language

Early clinical symptoms of cancer of the upper jaw are
runny nose
decreased vision
nosebleeds
+ pathological growths in the socket of the extracted tooth of the upper jaw

One of the main surgical methods for treating maxillary sinus cancer is
Microwave hyperthermia
Kreill's operation
Billroth operation
+resection of the upper jaw

Sarcomas develop from
epithelium
glandular tissue
+ connective tissue

Symptoms of sarcoma of the upper jaw are

+ nasal discharge, exophthalmos
dry mouth, paroxysmal acute pain, difficulty swallowing, hypersalivation ,
chills, muff-like infiltration of the jaw
paresis of the branches of the facial nerve

Fibrous dysplasia is
bone tumor
soft tissue tumor
true odontogenic tumor
+tumor-like bone formation

The main treatment method for gingival fibromatosis
chemotherapy
radiation therapy
combination treatment
+excision of the tumor along with the periosteum

Odontoma belongs to the group
inflammatory diseases
tumor-like formations
+ malformations of dental tissues
malignant odontogenic tumors

Ameloblastoma belongs to the group
precancers
inflammatory diseases
malignant odontogenic tumors
+benign odontogenic tumors

The final diagnosis of ameloblastoma is made based on the data
survey
blood test
+histology
clinical and radiological examination

Giant cell tumor belongs to the group
tumor-like formations
malignant odontogenic tumors
+benign odontogenic tumors
true tumors

Synonym for giant cell tumor
cylindroma
osteosarcoma
+ osteoclastoma
retention cyst

The X-ray picture of a giant cell tumor is characterized by varieties of polymorphic, monomorphic
+cellular, cystic, lytic
subperiosteal , periapical
proliferative, bone-forming

The main treatment for giant cell tumor is
chemotherapy
cryodestruction
scraping
+removal of the tumor within healthy tissues

**Federal State Budgetary Educational Institution
higher education "North Ossetian State Medical Academy" of the Ministry of Health
of the Russian Federation**

Department of Radiation Diagnostics with Radiation Therapy and Oncology
Faculty/ Specialty General Medicine Course **/Year of Study** 3
Discipline Radiation diagnostics

Ticket to test No. 1

1. In what year were X-rays discovered, what they are, their properties.
2. X-ray diagnosis of pulmonary echinococcus.
3. Situational task.

**Federal State Budgetary Educational Institution
higher education "North Ossetian State Medical Academy" of the Ministry of Health
of the Russian Federation**

Department of Radiation Diagnostics with Radiation Therapy and Oncology

Faculty/ Specialty General Medicine Course

/Year of Study 3

Discipline Radiation diagnostics

Ticket to test No. 2

1. Layer-by-layer (tomographic) examination of the chest organs
2. X-ray diagnosis of tuberculoma lungs, cavernous form of pulmonary tuberculosis.
3. Situational task.

**Federal State Budgetary Educational Institution
higher education "North Ossetian State Medical Academy" of the Ministry of Health
of the Russian Federation**

Department of Radiation Diagnostics with Radiation Therapy and Oncology

Faculty/ Specialty General Medicine Course

/Year of Study 3

Discipline Radiation diagnostics

Ticket to test No. 3

- 1 X-ray image formation. Construction of an x-ray report.
2. Diseases of the trachea, research methods, placement.
3. Situational task.

**Federal State Budgetary Educational Institution
higher education "North Ossetian State Medical Academy" of the Ministry of Health
of the Russian Federation**

Department of Radiation Diagnostics with Radiation Therapy and Oncology

Faculty/ Specialty General Medicine Course

/Year of Study 3

Discipline Radiation diagnostics

Ticket to test No. 4

1. The importance of fluorography clinical examination
2. X-ray diagnosis of effusion pleurisy.
3. Situational task.

**Federal State Budgetary Educational Institution
higher education "North Ossetian State Medical Academy" of the Ministry of Health
of the Russian Federation**

Department of Radiation Diagnostics with Radiation Therapy and Oncology

Faculty/ Specialty General Medicine Course

/Year of Study 3

Discipline Radiation diagnostics

Ticket to test No. 5

1. Filling out and maintaining medical documentation in the X-ray room of the clinic
2. Bronchial obstruction syndrome.
3. Situational task.

**Federal State Budgetary Educational Institution
higher education "North Ossetian State Medical Academy" of the Ministry of Health
of the Russian Federation**

Department of Radiation Diagnostics with Radiation Therapy and Oncology

Faculty/ Specialty General Medicine Course

/Year of Study 3

Discipline Radiation diagnostics

Ticket to test No. 6

1. Basic and additional methods of radiation diagnostics.
2. Basic x-ray signs (shadow, darkening, clearing)
3. Situational task.

**Federal State Budgetary Educational Institution
higher education "North Ossetian State Medical Academy" of the Ministry of Health
of the Russian Federation**

Department of Radiation Diagnostics with Radiation Therapy and Oncology

Faculty/ Specialty General Medicine Course

/Year of Study 3

Discipline Radiation diagnostics

Ticket to test No. 7

1. Contrast research methods
2. Methodology for studying the large intestine. X-ray diagnosis of colon tumors.
3. Situational task.

**Federal State Budgetary Educational Institution
higher education "North Ossetian State Medical Academy" of the Ministry of Health
of the Russian Federation**

Department of Radiation Diagnostics with Radiation Therapy and Oncology

Faculty/ Specialty General Medicine Course

/Year of Study 3

Discipline Radiation diagnostics

Ticket to test No. 8

1. Methods of obtaining x-ray images.
2. Radiation diagnostic methods not related to X-rays. radiation (ultrasound).
3. Situational task.

**Federal State Budgetary Educational Institution
higher education "North Ossetian State Medical Academy" of the Ministry of Health
of the Russian Federation**

Department of Radiation Diagnostics with Radiation Therapy and Oncology

Faculty/ Specialty General Medicine Course

/Year of Study 3

Discipline Radiation diagnostics

Ticket to test No. 9

1. Measures to protect medical staff , patients and the population.
2. Acute and chronic inflammatory and suppurative diseases of the bronchi and lungs (research methods, symptoms).
3. Situational task.

**Federal State Budgetary Educational Institution
higher education "North Ossetian State Medical Academy" of the Ministry of Health
of the Russian Federation**

Department of Radiation Diagnostics with Radiation Therapy and Oncology

Faculty/ Specialty General Medicine Course

/Year of Study 3

Discipline Radiation diagnostics

Ticket to test No. 10

1. Filling out and maintaining medical documentation in the X-ray room of the clinic
2. X-ray diagnosis of acute intestinal obstruction.
3. Situational task.